

Oral Administration of the Aqueous Extract of *Rosmarinus Officinalis* in Rats Before Renal Reperfusion Injury

Saeed Changizi Ashtiyani,¹ Marzieh Zohrabi,¹ Akbar Hassanpoor,² Nasser Hosseini,³ Saeed Hajhashemi¹

¹Department of Physiology, Arak University of Medical Sciences, Arak, Iran

²Department of Pathology, Arak University of Medical Sciences, Arak, Iran

³Department of Medicinal Plants, Arak University, Arak, Iran

Keywords. acute kidney failure, reperfusion injury, kidney, *Rosmarinus*, rats

Introduction. Reperfusion injury leads to damage to the hemodynamic and functional parameters of the kidney. This study investigated the effects of oral administration of the aqueous extract of rosemary on improvement of changes induced by ischemia-reperfusion in rats. **Materials and Methods.** Forty male Sprague-Dawley rats were divided into 4 groups. One group was the control, rats in another group underwent sham operation, and 2 groups were exposed to reperfusion injury. Rats in one of the reperfusion groups was treated with 8% oral aqueous extract of rosemary (10 mL/kg/d) for 1 week (rosemary group), and the other received normal saline for the same period of time (reperfusion group). Reperfusion injury was induced by bilateral occlusion of the renal artery and vein for 30 minutes and reperfusion for 24 hours. Examination of oxidative stress was done, including measurement of malondialdehyde and ferric reducing antioxidant power in urine and blood samples. Histological studies were performed on excised kidneys.

Results. The comparison between the rosemary and reperfusion groups indicated significant reductions in the levels of plasma creatinine, blood urea nitrogen, and absolute urinary excretion of sodium in the rosemary group. Similarly, the rosemary group presented a significant decrease in malondialdehyde and a significant increase in ferric-reducing antioxidant power. Histopathological examinations showed significant reductions in vascular congestion and cells exfoliation in the rosemary group, in comparison with the reperfusion group.

Conclusions. Oral administration of the aqueous extract of rosemary prior to ischemia-reperfusion is effective in reducing functional and histopathological complications associated with acute kidney failure.

IJKD 2013;7:367-75
www.ijkd.org

INTRODUCTION

Acute kidney failure (AKF) is a medical emergency characterized by a rapid decline in kidney function, which results in the accumulation of nitrogenous wastes and increased blood urea and creatinine.¹ The most common cause of AKF is known to be renal ischemia during which renal

damage is induced by a combination of factors including vasoconstrictor factors, renal tubule obstruction, tubule backleak, and increased glomerular permeability.² Reperfusion injury as the most common method of inducing AKF leads to damage to hemodynamic and functional parameters.³ During ischemia, adenosine triphosphatase depletion

results in disruption of ion transfer, which in turn leads to the accumulation of ions and water, and eventually damage to endothelial and epithelial cells. This damage is accompanied by the migration of leukocytes and inflammatory mediators such as interleukins, tumor necrosis factor (TNF)- α , and platelet-activating factors, which is accompanied by oxidant factors and cytokines release by energy depletion on the one hand and reperfusion on the other. This can cause further damage to endothelial cells and also result in alteration of gene expression and proteins synthesis, which plays a key role in ions transfer.⁴

Since common medical treatments have side effects, especially in association with their long-term use, and have high costs imposed on these patients, tendency towards alternative and traditional treatments is increasing. A great amount of research has been done on herbs to investigate their effects on AKF.⁵ Rosemary plant (*Rosmarinus officinalis*), which belongs to the *Lamiaceae* family is an aromatic plant that is used as a food additive.⁶ Although this plant is mostly known for its antioxidant properties in medicine, it possesses anti-inflammatory, antiproliferative, antitumorigenic, and neuroprotective effects, as well.⁷ Several studies have shown that rosemary is a moderator of apoptosis and inflammatory activities.⁷ It has a variety of properties, including antispasmodic, diuretic, and expectorant.⁸ Due to its antioxidant property, rosemary inhibits lipid peroxidation and the production of free oxygen radicals and suppresses inflammation.⁹

Noticing the presence of compounds with these properties in the aqueous extract of rosemary plant and the mechanisms related to disturbances in the excretory function of nephrons following AKF, we decided to study the effect of the aqueous extract of this plant on the improvement of histopathology and functional complications associated with AKF from different perspectives for the first time.

MATERIALS AND METHODS

Study Design

This experimental study was done on 40 male Sprague-Dawley rats weighing 300 g to 250 g, which were supplied from the Experimental Animals Breeding Center of Arak University of Medical Sciences. These animals were placed in controlled conditions of temperature ($23 \pm 2^\circ\text{C}$) and light

(light, 12 hours; dark, 12 hours) and they were provided with food and water ad libitum. Animal care and handling were performed according to the guidelines set by Iranian Ministry of Health and Medical Education.

First the rats were weighed and then anesthetized by an intraperitoneal injection of sodium pentobarbital (60 mg/kg; Sigma, UK). Renal ischemia was induced by bilateral occlusion of the renal artery and vein for 30 minutes, using a special clamp, which was removed after 30 minutes of obstruction. The rats were divided into 4 groups, each including 10: (1) control group, in which the rats did not receive any vehicle or drugs and had access to standard feed; (2) sham group, in which the rats were anesthetized and the renal arteries and veins were exposed without clamping. They received the vehicle of rosemary extract through gavage for 1 week; (3) reperfusion group, in which the rates received the vehicle of rosemary extract (normal saline) administered through gavage for 1 week before induction of AKF by ischemia-reperfusion; and (4) rosemary group, in which the rats received rosemary extract was administered through gavage for 1 week before induction of AKF by ischemia-reperfusion.

In all groups, the rats were kept in metabolic cages and urine samples were collected after induction of AKF and measured using the gravimetric method. The rats were anesthetized and blood pressure was measured by a Power Lab System (AD Instruments, Bella Vista, Australia). The left kidney artery was separated from the vein and renal blood flow was measured as mL/min using flow meter with a special probe. Blood sampling from the aorta was done by heparin cold syringe. Plasma separation was done by centrifugation. After separating and weighing both kidneys, one of them was kept in 10% formalin for histological studies and the other one was frozen in liquid nitrogen and kept in -20°C for measuring biochemical parameters. Antioxidant properties were determined by ferric-reducing antioxidant power (FRAP) and malondialdehyde. Serum and urine levels of sodium, potassium, and creatinine, and blood urea nitrogen (BUN) concentrations were measured. In order to determine kidney function, absolute urinary excretion of sodium and potassium, and also fractional excretion of sodium and potassium were calculated. Creatinine clearance

was calculated for determination of glomerular filtration rate.

Rosemary Extraction

Rosemary plant was provided from Arak University Herb Farm. The air-dried leaves were coarsely powdered and 8 g of the powder dissolved in 100 mL of distilled water was boiled for 5 minutes and infused for 10 minutes. After cooling and passing through a filter paper, a clear solution was achieved. During 1 week, 10 mL/kg/d of the extract was given to the rats by gavage.¹⁰

Biochemical Parameters

Malondialdehyde. Injury due to oxidative stress which results from lipid peroxidation was assessed by measuring malondialdehyde level. The Ohkawa method was used for determination of malondialdehyde level in kidney tissues. In short, after separation of the kidney and weighing, phosphate buffer was added at 1:10 ratio (W/V), and then homogenized by homogenizer to form a homogenate. Acetic acid (20%), thiobarbituric acid (0.8%), and sodium dodecyl sulphate (8.1%) were added to all tubes. Test tubes containing the suspension were heated inside a water bath at 95°C for 60 minutes. After malondialdehyde reaction, a pink complex was formed that was extracted with n-butanol. Absorption was measured at 532 nm by spectrophotometry. The results obtained from these samples were compared by tetraethoxy-propane and the numeric amounts were reported as micromole per gram kidney weight ($\mu\text{mol/g KW}$).¹¹

Ferric Reducing Antioxidant Power. Measurement of FRAP has been considered as one of the most common methods for evaluation of total antioxidant activity since 1996. This method is based on the ability of tissue fluid to reduce ferric to ferrous in the presence of tripyridyl-S-triazine. The ability of tissue fluid reduction was assessed by concentration of blue tripyridyl-S-triazine-ferrous complex measured by spectrophotometry. The FRAP indicator was prepared as a mixture of acetate buffer, ferric chloride, tripyridyl-S-triazine, and distilled water. Tissue extract (50 μL) and FRAP indicator (1.5 mL) were mixed in cuvettes, and after 4 minutes, absorption was measured at 593 nm and read against blank. The results were compared to the standard curve, and plasma concentrations of the samples were measured. After constructing the

standard curve, the FRAP levels of tissue samples were expressed as mmol/g KW .^{12,13}

Histopathological Studies

The kidneys were processed for light microscopy examination. The kidneys were fixed in the buffered 10% formaldehyde and embedded in paraffin, and 5- μm sections were stained with hematoxylin and eosin. Histopathological analysis was done on cortex sections and the inner and outer sections of the medulla separately. The cortex was analyzed for the number of erythrocytes inside the glomeruli, tubular epithelial cells necrosis, and tubular injury, and the inner and outer of medulla for epithelial cell necrosis, proteinaceous casts, and medullary vessels congestion. The degree of impairments was graded as follows: no impairment, grade zero; 1% to 20%, grade 1; 21% to 40%, grade 2; 41% to 60%, grade 3; 61% to 80%, grade 4; and 81% to 100%, grade 5.¹⁴

Statistical Analysis

The results were expressed as mean \pm standard error of mean. The analyses were done using the SPSS software (Statistical Package for the Social Sciences, version 11.5, SPSS Inc, Chicago, Ill, USA). Statistical comparisons between the groups were performed by the 1-way analysis of variance and the Duncan test. The Kruskal-Wallis multiple comparison test was used for analysis of categorical variables. The differences were considered to be significant at a *P* value less than .05.

RESULTS

The Table presents significant changes in different hemodynamic parameters in the reperfusion and rosemary groups during the 24 hours of reperfusion following 30 minutes of ischemia as compared to the sham and control groups. Significant decreases were seen in creatinine clearance (86%), urine osmolarity (34%), number of erythrocytes inside the glomeruli (39%), and absolute urinary excretion of potassium (53%) in the reperfusion group in comparison with the sham group. In addition, significant increases were observed in the levels of plasma creatinine, BUN, absolute urinary excretion of sodium, fractional excretion of sodium, and fractional excretion of potassium in the reperfusion group in comparison with the sham group (Figure 1 and Table).

In the rosemary group, significant decreases were seen in the levels of plasma creatinine (71%), BUN (48%), absolute urinary excretion of sodium (74%), fractional excretion of sodium (94%), and fractional excretion of potassium (56%) in comparison with the reperfusion group. Moreover, there were significant increases in the number of erythrocytes in

glomeruli, absolute urinary excretion of potassium, and creatinine clearance in the rosemary group in comparison with the reperfusion group (Figure 1 and Table). Similarly, the rosemary group presented a significant decrease in malondialdehyde and a significant increase in ferric-reducing antioxidant power (Figure 2). However, no significant changes

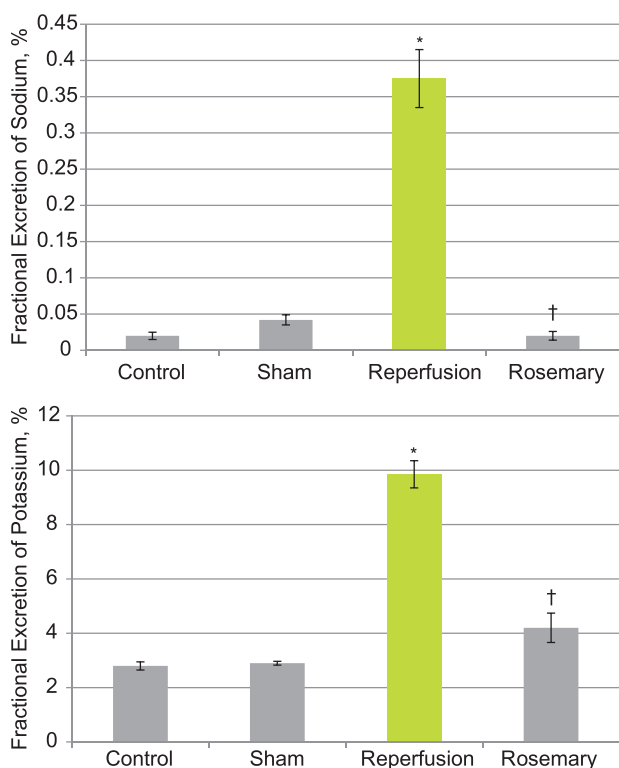


Figure 1. The mean levels of fractional excretions of sodium and potassium after reperfusion injury in rats receiving oral rosemary (rosmary group) and normal saline (reperfusion group) as compared to the sham operation and control groups.
**P* < .001, compared with sham group
†*P* < .001, compared with reperfusion group

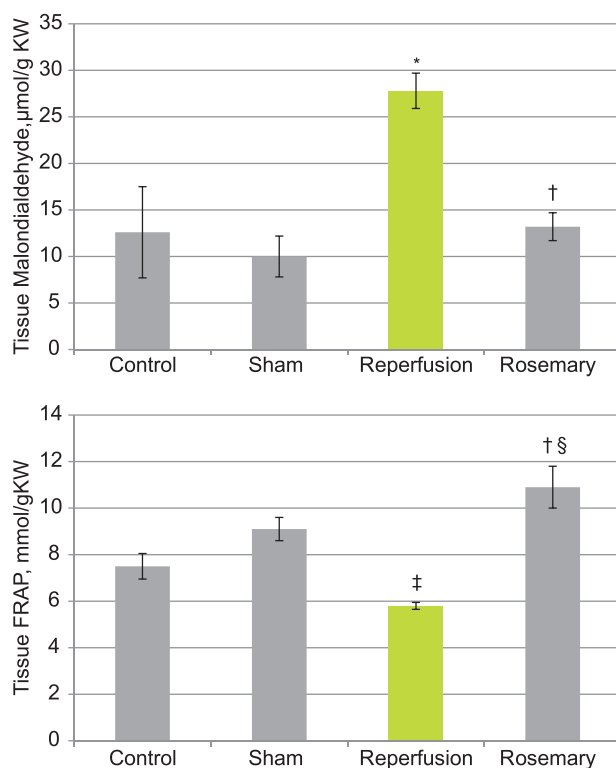


Figure 2. The mean levels of malondialdehyde and ferric reducing antioxidant power (FRAP) after reperfusion injury in rats receiving oral rosemary (rosmary group) and normal saline (reperfusion group) as compared to the sham operation and control groups.
**P* < .001, compared with sham group
†*P* < .001, compared with reperfusion group
‡*P* < .01, compared with sham group
§*P* < .05, compared with sham group

Hemodynamic Changes in Kidney Function Parameters Due to Renal Ischemia-Reperfusion in Rats

Parameter	Control	Sham	Reperfusion	Rosemary
Plasma Creatinine, mg/dL	0.65 ± 0.04	0.80 ± 0.05	2.69 ± 0.10*	0.78 ± 0.10†
Blood Urea Nitrogen, mg/dL	17.6 ± 0.6	24.2 ± 1.5	84.9 ± 4.8*	44.0 ± 10.4††
Absolute urinary sodium excretion, mmol/min/kg	0.50 ± 0.04	0.95 ± 0.10	1.28 ± 0.10	0.33 ± 0.04†
Absolute urinary potassium excretion, mmol/min/kg	1.4 ± 0.1	1.7 ± 0.2	0.8 ± 0.1*	1.6 ± 0.2§
Urine osmolarity, mOsm/kg H ₂ O	1458.0 ± 46.8	1486.0 ± 47.2	970.0 ± 96.5*	1538.0 ± 13.2†
Creatinine clearance, mL/min/kg	13.3 ± 1.8	16.6 ± 2.7	2.3 ± 0.2*	11.7 ± 2.2§
Mean renal blood flow, mL/min	8.0 ± 0.3	8.4 ± 0.4	5.1 ± 0.6*	6.8 ± 0.3‡
Systolic blood pressure, mm Hg	94.39 ± 5.20	81.96 ± 5.60	85.39 ± 4.40	71.84 ± 5.03

**P* < .001, compared with sham group
†*P* < .001, compared with reperfusion group
‡*P* < .05, compared with sham group
§*P* < .01, compared with reperfusion group

were observed in systolic blood pressure of these groups.

The histopathological findings of this study showed no kidney tissue changes (grade zero) in the sham group (Figure 3), whereas in the reperfusion group, a significant amount of cells exfoliation (grade 4) in the proximal tubule was seen as compared with the sham group. Furthermore, a significant increase in Bowman space (grade 3) was seen in this region (Figure 4). In the reperfusion group, significant vascular congestion (grade 4) and proteinaceous casts (grade 4) were observed in the proximal region and medulla of the kidney; however, significant changes in the collecting tubules and the thin ascending tubules of Henle were not observed. In the group receiving rosemary, vascular congestion (grade 2) was less significant in the cortex area and cells exfoliation (grade 2) and Bowman space (grade 1) showed significant

improvements. The amount of proteinaceous casts (grade 1) and vascular congestion (grade 2) in the outer medulla significantly decreased (Figures 5).

DISCUSSION

In this study, the effect of the pretreatment administration of the aqueous extract of rosemary on the improvement of renal damages induced by 30 minutes of bilateral ischemia of the renal arteries and veins and 24 hours of reperfusion was investigated. The findings of this study showed that the number of erythrocytes in the glomeruli of the reperfusion group experienced a significant decrease (39%) in comparison with the sham group. Furthermore, a similar pattern was observed for creatinine clearance with an 86% reduction. These findings are indicative of tubular cell damage, particularly the proximal tubule, increased pressure in the Bowman capsule, and glomerular arteries

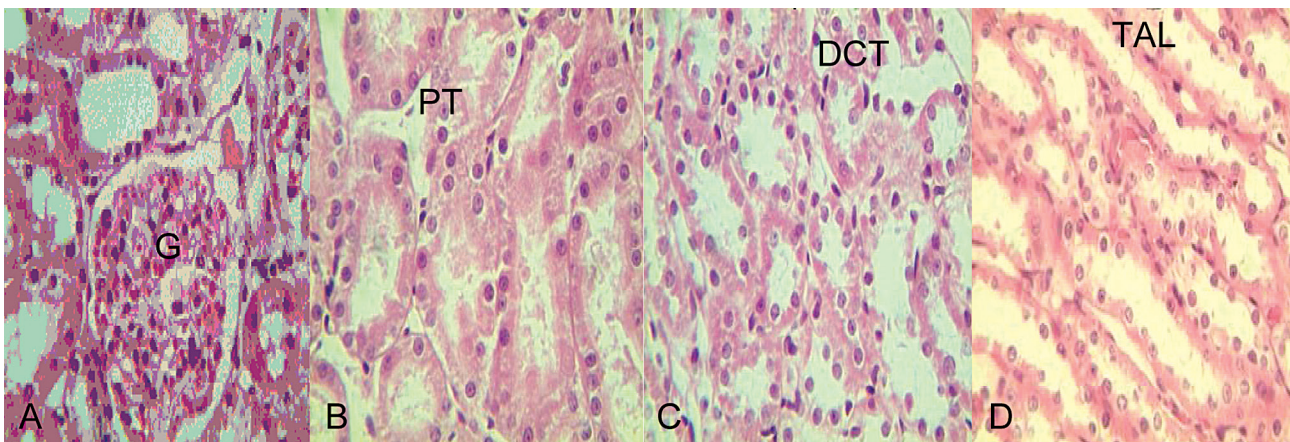


Figure 3. Microphotographic representation of the left kidney from cortex (A and B) and outer medulla (C and D) in the sham group (hematoxylin-eosin, $\times 400$). G indicates glomerulus; PT, proximal tubule; DCT, distal convoluted tubule; and TAL, thick ascending limb of Henle loop.

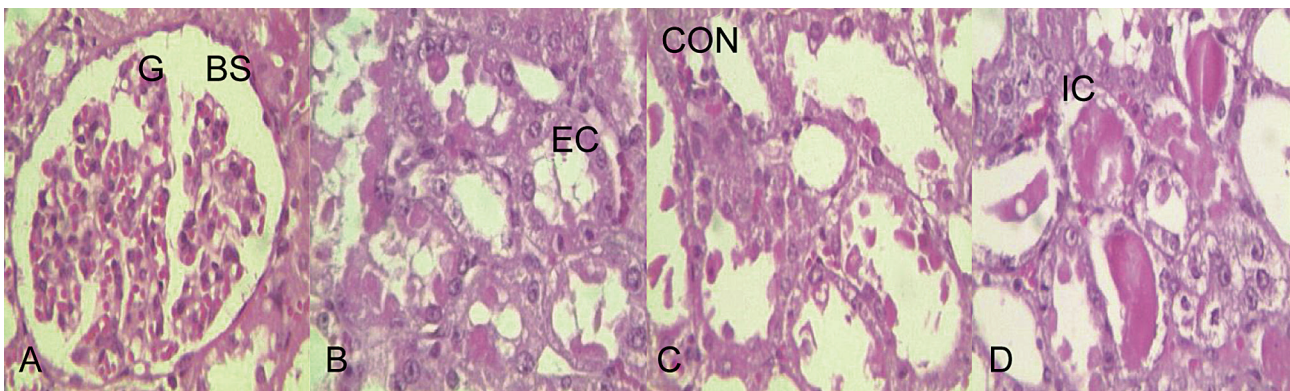


Figure 4. Microphotographic representation of the left kidney from cortex (A and B) and outer medulla (C and D) in the reperfusion group (hematoxylin-eosin, $\times 400$). G indicates glomerulus; BS, Bowman space; EC, exfoliated cells; CON, congestion; and IC, intratubular cast.

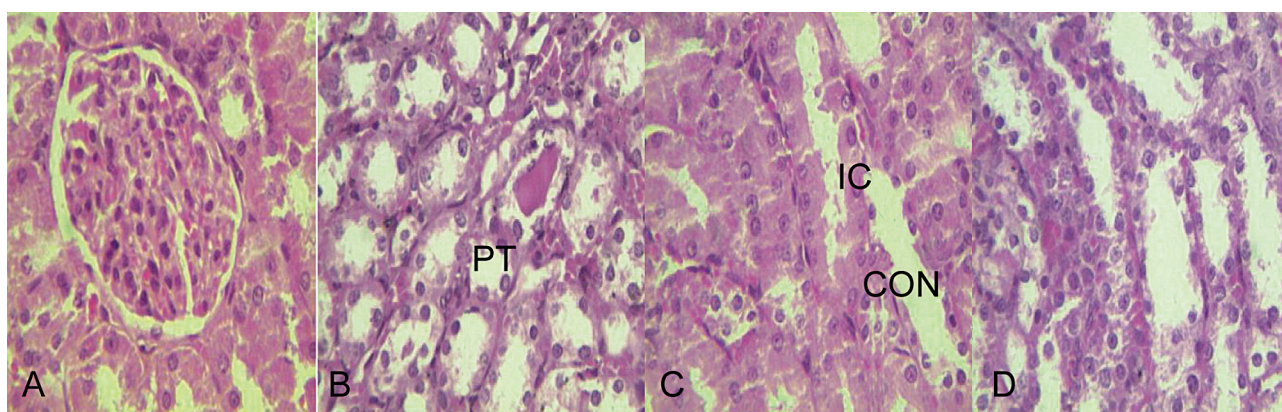


Figure 5. Microphotographic representation of the left kidney from cortex (a1, a2) and outer medulla (a3, a4) in the rosemary group (hematoxylin-eosin, $\times 400$). PT indicates proximal tubule; IC, intratubular cast; and CON, congestion.

congestion and constriction.¹⁵

Several studies have seen reperfusion injury as the loss of balance in the vasoactive factors and the dominance of vasoconstrictive factors, such as angiotensin II and endothelin, on vasodilatory factors.¹⁶ A number of studies have associated this imbalance with the overproduction of free oxygen radicals, especially in the proximal tubule.^{17,18} The significant decrease in renal blood flow due to vascular congestion and increase of resistance due to the accumulation of erythrocytes and leukocytes in glomerular arteries result in decrease of urine clearance, especially creatinine clearance.¹⁹ The findings of histopathological analysis also showed a significant increase in Bowman space, which was indicative of glomerular constriction. In addition, the presence of a significant congestion in proximal tubules showed a significant decrease in the renal blood flow in the reperfusion group.

The decreases in vascular congestion and Bowman space were indicative of improvements in renal blood flow in the group of rats pretreated with rosemary. In this group, the mean renal blood flow increased up to 25% in comparison with the reperfusion group, which demonstrated the positive effect of rosemary on elimination of reactive oxygen species that can be attributed to its anti-inflammatory and antispasmodic properties. In the study done by Lian and colleagues, it was shown that the carnosol present in rosemary inhibits the TNF- α bond to endothelial cells which induce monocytes.²⁰ Furthermore, Sagorchev and colleagues showed that 25 $\mu\text{L/L}$ of rosemary had agonistic effects on $\alpha 1$ and $\alpha 2$ adrenergic receptors, whereas its higher than 100 $\mu\text{L/L}$ doses completely

suppressed the α effects and it had an anti-spasmodic effect.²¹ Yao and colleagues' study on the pretreatment effect of carnosol on acute liver damage due to intestinal reperfusion injury in rats showed that pretreatment administration of carnosol can be effective in reducing damages to the liver through decreasing oxidative stress and liver function markers, activity of blood leucocytes, downregulation of interleukin-6 inflammatory factor, and inhibition of nuclear factor kappa-light-chain-enhancer of activated B cells.²²

Evaluation of systolic blood pressure values during the 24-hour period of reperfusion did not reveal any significant differences in different groups. This indicated that the observed differences in kidney function parameters in the tested groups were not due to changes in systolic blood pressure.

In this study, 86% and 70% increases were observed in creatinine clearance and plasma creatinine level in the reperfusion group, respectively, as compared with the sham group. In Chatterjee and coworkers' study, after 45 minutes of bilateral obstruction of the renal arteries, a significant increase was observed in plasma urea and creatinine concentrations, which indicated damage to the glomerular function. In addition, a significant increase was seen in fractional excretion of sodium, which demonstrated tubular damage, and the presence of tubular function damage markers suggested that in the early phases after ischemia, renal tubules damages are more than glomerular function damages.²³

The findings of the present study showed significant 89% and 70% increases in fractional excretions of sodium and potassium, respectively,

in the reperfusion group as compared with the sham group. This increase was, in fact, indicative of tubular cells damage, especially proximal tubule cells, during ischemia-reperfusion. Kang and colleagues showed that after 45 minutes of the bilateral obstruction of renal arteries, proximal tubule, which is the site of absorption of two-thirds of the sodium entering the tubule, resulted in an increase in fractional excretion of sodium, following glomerular filtration rate decrease during ischemia-reperfusion. This was attributed to the decrease of expression of $\alpha 1$ and $\beta 2$ subunits of the sodium-potassium-adenosine triphosphatase pump during ischemia-reperfusion.²⁴ However, in the rosemary group, fractional excretion of sodium decreased up to 94% in comparison with the reperfusion group, which shows the positive effect of rosemary on the improvement of tubules damage during ischemia-reperfusion. Histopathological findings in the pretreatment with rosemary group also showed significant decrease in proteinaceous casts and cellular apoptosis, which were indicative of the improvement of renal tubules, especially the proximal tubule.

The findings of the present study indicated that urine osmolarity in the reperfusion group significantly decreased in comparison with the sham group. This shows the destruction of osmotic gradient in kidney medulla which led to deficiency in the urine concentration. In the study by Mozzafari and coworkers, it was shown that the expression of aquaporin 2 as the main regulator of urine osmolarity, aquaporin 3 in the collecting ducts, and aquaporin 1 in proximal tubules significantly decreased during AKF.²⁵ In addition, Kwon and associates showed that following 30 minutes of bilateral renal obstruction and 24 hours of reperfusion, aquaporin 2 and aquaporin 3 levels in the main cells of the collecting tubule of the inner medulla significantly decreased and the expression of aquaporin 1 in the proximal tubule and thick ascending limb, which are the main targets for damage during ischemia-reperfusion significantly decreased as well.²⁶ Following pretreatment with rosemary a significant increase was observed in urine osmolarity. The histopathological findings of the present study also showed decrease of proteinaceous casts, apoptosis in thick ascending limb tubules, and proximal tubules necrosis which verify the effectivity of this plant in maintain

osmotic gradient and urine concentration.

In the present study, following the 30-minute obstruction of bilathral renal artery and vein and 24 hours of reperfusion, oxidative stress states were established. This was verified by the 62.5% increase in the amount of malondialdehyde in reperfusion group in comparison with the sham group, which shows the presence of reactive oxygen species following the 30-minute renal obstruction. However, in the rosemary group, the 68% increase in FRAP and the 52% decrease in the amount of malondialdehyde in comparison with the reperfusion group were indicative of the strong anti-oxidant property of rosemary in eliminating reactive oxygen species.

Rosemary can also decrease the amount of reactive oxygen species through increasing the reducibility power in kidney tissues. Ahmad and colleagues' study, which investigated the effect of the aqueous extract of rosemary on the immune response due to the oxidative stress induced by aflatoxins, demonstrated that pretreatment with rosemary significantly decreased the lipid peroxidation. This effect was attributed to the presence of carnosic acid and carnosol, which are the main phenolic compounds of this plant.²⁷ Moreover, Sancheti and Goyal's study on the effect of rosemary on 7,12-dimethyl-benz(a) anthracene of tumor inductor in mice showed that the oral administration of the aqueous extract of rosemary through moderating the level of blood antioxidants and increasing the level of blood and liver glutathione results in inducing the antitumor effects. It was also stated that rosemary plant due to the presence of four terpenoids, carnosic acid, carnosol, rosmanol, and epirosmanol in it, leads to the inhibition of lipid peroxidation and superoxide.²⁸ In addition, Botsoglou and colleagues' study demonstrated that carbon tetrachloride, through increasing the level of malondialdehyde, results in acute damage to liver cells and disturbance in the integrity of liver structure that following pretreatment with Rosemary plant, it improves the liver structure in rats through eliminating the free radicals and decreasing the malondialdehyde level.²⁹

CONCLUSIONS

This study shows that oral administration of the aqueous extract of rosemary prior to ischemia-reperfusion is effective in reducing functional and

histopathological complications associated with acute kidney failure. Further investigation of the protective effect of rosemary against kidney injury in human kidneys is warranted.

ACKNOWLEDGMENTS

This manuscript was part of the research project No 531 of the Research Committee of Arak University of Medical Sciences, Arak, Iran (Ethics Committee No 89-97-3). The authors would like to thank the moral and financial support provided by the Vice presidency of Research of Arak University of Medical Sciences, the laboratory staff at Amir-al-momenin Hospital, Arak, and histopathology experts of the Faculty of Medicine, Arak University of Medical Sciences.

CONFLICT OF INTEREST

None declared.

REFERENCES

1. Andreoli SP. Acute kidney injury in children. *Pediatr Nephrol.* 2009;24:253-63.
2. Abuelo JG. Normotensive ischemic acute renal failure. *N Engl J Med.* 2007;357:797-805.
3. Sauvant C, Schneider R, Holzinger H, Renker S, Wanner C, Gekle M. Implementation of an in vitro model system for investigation of reperfusion damage after renal ischemia. *Cell Physiol Biochem.* 2009;24:567-76.
4. Gimelreich D, Popovtzer MM, Wald H, Pizov G, Berlatzky Y, Rubinger D. Regulation of ROMK and channel-inducing factor (CHIF) in acute renal failure due to ischemic reperfusion injury. *Kidney Int.* 2001;59:1812-20.
5. Changizi Ashtiyani S, Najafi H, Jalalvandi S, Hosseini F. Protective effects of rosa canina L fruit extracts on renal disturbances induced by reperfusion injury in rats. *Iran J Kidney Dis.* 2013;7:290-8.
6. El-Din HMF, Ghita EI, Badran SMA, Gad AS, El-Said MM. Manufacture of low Fat UF-soft cheese supplemented with rosemary extract (as natural antioxidant). *J Am Sci.* 2010;6:570-9.
7. Cheng AC, Lee MF, Tsai ML, et al. Rosmanol potently induces apoptosis through both the mitochondrial apoptotic pathway and death receptor pathway in human colon adenocarcinoma COLO 205 cells. *Food Chem Toxicol.* 2011;49:485-93.
8. Ventura-Martinez R, Rivero-Osorno O, Gomez C, Gonzalez-Trujano ME. Spasmolytic activity of Rosmarinus officinalis L. involves calcium channels in the guinea pig ileum. *J Ethnopharmacol.* 2011;137:1528-32.
9. Rasha AR, Abdella EM. Modulatory effects of rosemary leaves aqueous extract on doxorubicin-induced histological lesions, apoptosis and oxidative stress in mice. *Iran J Cancer Prevent.* 2010;1:1-22.
10. Haloui M, Louedec L, Michel JB, Lyoussi B. Experimental diuretic effects of Rosmarinus officinalis and Centaureum erythraea. *J Ethnopharmacol.* 2000;71:465-72.
11. Ashtiyani SC, Najafi H, Firouzifar MR, Shafaat O. Grape seed extract for reduction of renal disturbances following reperfusion in rats. *Iran J Kidney Dis.* 2013;7:28-35.
12. Zohrabi M, Ashtiyani SC, Hajhashemi S, Hassanpoor A, Hosseini N. The study of 24 h post treatment effects of the aqueous extract of Rosmarinus officinalis after renal ischemia/reperfusion in rat. *J Physiol Pathophysiol.* 2012;3:12-19.
13. Ashtiyani SC, Najafi H, Kabirinia K, Vahedi E, Jamebozorky L. Oral omega-3 fatty acid for reduction of kidney dysfunction induced by reperfusion injury in rats. *Iran J Kidney Dis.* 2012;6:275-83.
14. Moosavi SM, Bayat G, Owji SM, Panjehshahin MR. Early renal post-ischaemic tissue damage and dysfunction with contribution of A1-adenosine receptor activation in rat. *Nephrology (Carlton).* 2009;14:179-88.
15. [No author listed]. Biology of acute renal failure: therapeutic implications. *Kidney Int.* 1997;52:1102-15.
16. Conger J. Hemodynamic factors in acute renal failure. *Adv Ren Replace Ther.* 1997;4:25-37.
17. Chatterjee PK, Cuzzocrea S, Brown PA, et al. Tempol, a membrane-permeable radical scavenger, reduces oxidant stress-mediated renal dysfunction and injury in the rat. *Kidney Int.* 2000;58:658-73.
18. Bayrak O, Bavbek N, Karatas OF, et al. Nigella sativa protects against ischaemia/reperfusion injury in rat kidneys. *Nephrol Dial Transplant.* 2008;23:2206-12.
19. Thadhani R, Pascual M, Bonventre JV. Acute renal failure. *N Engl J Med.* 1996;334:1448-60.
20. Lian KC, Chuang JJ, Hsieh CW, et al. Dual mechanisms of NF-kappaB inhibition in carnosol-treated endothelial cells. *Toxicol Appl Pharmacol.* 2010;245:21-35.
21. Sagorchev P, Lukanov J, Beer AM. Investigations into the specific effects of rosemary oil at the receptor level. *Phytomedicine.* 2010;17:693-7.
22. Yao JH, Zhang XS, Zheng SS, et al. Prophylaxis with carnosol attenuates liver injury induced by intestinal ischemia/reperfusion. *World J Gastroenterol.* 2009;15:3240-5.
23. Chatterjee PK, Zacharowski K, Cuzzocrea S, Otto M, Thiemeermann C. Inhibitors of poly (ADP-ribose) synthetase reduce renal ischemia-reperfusion injury in the anesthetized rat in vivo. *FASEB J.* 2000;14:641-51.
24. Kang DG, Sohn EJ, Moon MK, Lee YM, Lee HS. Rehmannia glutinosa ameliorates renal function in the ischemia/reperfusion-induced acute renal failure rats. *Biol Pharm Bull.* 2005;28:1662-7.
25. Mozaffari MS, Abdelsayed R, Liu JY, Zakhary I, Baban B. Renal distal tubule proliferation and increased aquaporin 2 level but decreased urine osmolality in db/db mouse: treatment with chromium picolinate. *Exp Mol Pathol.* 2012;92:54-8.
26. Kwon TH, Frokiaer J, Fernandez-Llama P, Knepper MA, Nielsen S. Reduced abundance of aquaporins in rats with bilateral ischemia-induced acute renal failure: prevention by alpha-MSH. *Am J Physiol.* 1999;277:F413-27.
27. Ahmad ST, Hafez AS, Hassan MA, Mansour MK.

- Influence of rosemary extract on immune responses and oxidative stress in mice intoxicated by aflatoxins. *Nat Sci*. 2011;9:54-63.
28. Sancheti G, Goyal PK. Effect of *Rosmarinus officinalis* in modulating 7,12-dimethylbenz(a)anthracene induced skin tumorigenesis in mice. *Phytother Res*. 2006;20:981-6.
29. Botsoglou N, Taitzoglou I, Zervos I, Botsoglou E, Tsantariotou M, Chatzopoulou PS. Potential of long-term dietary administration of rosemary in improving the antioxidant status of rat tissues following carbon tetrachloride intoxication. *Food Chem Toxicol*. 2010;48:944-50.

Correspondence to:
Saeed Changizi Ashtiyani, PhD
Department of Physiology, Arak University of Medical Sciences,
Arak, Iran
E-mail: dr.ashtiyani@arakmu.ac.ir

Received August 2012
Revised February 2013
Accepted February 2013