

Diagnostic Accuracy of Renal Pelvic Dilatation in Determining Outcome of Congenital Hydronephrosis

Mostafa Sharifian,¹ Nasrin Esfandiar,² Masoumeh Mohkam,¹ Reza Dalirani,¹ Elaheh Baban Taher,¹ Arezu Akhlaghi¹

¹Department of Pediatric Nephrology, Pediatric Infectious Research Center, Shahid Beheshti University of Medical Sciences, Tehran, Iran

²Department of Pediatric nephrology, Pediatric Respiratory Diseases Research Center, National Research Institute of Tuberculosis and Lung Diseases, Masih Daneshvari Hospital, Shahid Beheshti University of Medical Sciences, Tehran, Iran

Keywords. congenital hydronephrosis, neonates, ultrasonography

Introductions. The widespread use of prenatal ultrasonography results in increased recognition of congenital hydronephrosis, a therapeutic and diagnostic challenge. This study was conducted to investigate the natural course of prenatal hydronephrosis and the accuracy of postnatal APD in determining the outcome.

Materials and Methods. All newborns with prenatal hydronephrosis were followed up by ultrasonography after birth. Voiding cystoureterography, diethylene triamine pentaacetic acid renal scintigraphy, and dimercaptosuccinic acid renal scintigraphy were done if indicated. The receiver operating characteristic curve was plotted to determine the best cutoff for the anterior-posterior pelvic diameter (APD) to distinguish surgical from spontaneously resolving group.

Results. Of 178 neonates, 42 (23%) required surgery. The area under the curve for APD to predict the need for surgery was 0.925 with an APD cutoff of 15 mm. The diagnostic value of APD for determining the need for surgery was determined by sensitivity and specificity of 95.2% and 73.5%, respectively.

Conclusions. Postnatal APD on ultrasonography has a valuable diagnostic accuracy for requiring surgery and provides a useful guide for parental counseling.

IJKD 2014;8:26-30
www.ijkd.org

INTRODUCTION

Hydronephrosis is the most common congenital defect detectable by prenatal ultrasonography.¹ Widespread use of prenatal ultrasonography, however, results in developing a new challenge for the clinicians. Prenatal hydronephrosis contains very wide differential diagnosis from transient to important cases such as obstructive uropathy or vesicoureteral reflux. The clinician's art is to differentiate significant cases from clinically insignificant ones preventing renal damage.

There are various viewpoints concerning the patient's follow-up. Some recommend performing

all available diagnostic methods including voiding cystoureterography (VCUG) and diethylene triamine pentaacetic acid (DTPA) renal scintigraphy, but some prefer selective methods relying on degree of hydronephrosis and unilateral or bilateral nature.¹⁻¹²

Hydronephrosis severity is categorized to grade 1 to 4 based on grading system of the Society for Fetal Urology or to mild, moderate and severe based on anterior-posterior pelvic diameter (APD) dilatation.¹³ This study was conducted to investigate correlation between prenatal ultrasonography and postnatal evaluation. We aimed to compare the results with similar studies determining whether

postnatal ultrasonographic measurement of APD can differentiate the surgical and nonsurgical groups upon specifying the best cutoff for APD or upon dividing patients into two groups of surgical and nonsurgical based on patient's follow-up.

MATERIALS AND METHODS

All newborns referred to our pediatric nephrology clinic with a main complaint of prenatal hydronephrosis were included in this study. Newborns with hydronephrosis that were not diagnosed prenatally were excluded. Prenatal hydronephrosis was defined based on the grading system of the Society for Fetal Urology (an APD greater than 4 mm in newborns with a gestational age shorter than 33 weeks or greater than 7 mm in those with a gestational age of 33 weeks and longer).¹⁴

Postnatal ultrasonography was performed by the same radiologist using the Medison Accavix V10 linear array 7 MHz probe (Samsung, South Korea) after the 1st week and on the 30th day of age, aiming at preventing pseudonegative effect of physiological oliguria on early days of life. According to the measured APD on ultrasonography, hydronephrosis was divided into 3 groups: mild hydronephrosis with an APD less than 9 mm, moderate hydronephrosis with an APD of 9 mm to 15 mm, and severe hydronephrosis with an APD greater than 15 mm.¹⁴ Newborns with moderate to severe hydronephrosis received prophylactic antibiotic therapy. The diagnosis, management, and follow-up of the patients are summarized in Figure 1.

RESULTS

A total of 178 newborns were included in the 4-year study. The median infant's age when entered the study was 7 days (range, 4 to 14 days). Clinical and radiologic characteristics are summarized in the Table.

The mean follow-up duration was 8.9 month (varied from 1 month to 4 years). All of the patients underwent postnatal ultrasonography, which showed hydronephrosis in 70% again. Voiding cystourethrography was performed in 152 (85.4%) of the patients, 35 of which (19.5%) indicated various grades of vesicoureteral reflux. According to diethylene triamine pentaacetic acid renal scintigraphy scans performed for 98

Clinical and Radiologic Characteristics of Newborns*

Parameter	Number (%)
All	178
Male	151 (85.0)
Female	27 (15.0)
Side of hydronephrosis	
Left	89 (50.0)
Right	56 (30.5)
Bilateral	33 (18.5)
VCUG (n = 152)	
Vesicoureteral reflux	35 (19.5)
DTPA (n = 98)	
Partial obstruction	64 (35.9)
Complete obstruction	30 (9.5)
Bilateral obstruction	4 (2.3)
Surgery	42 (23.5)
% of patients who underwent surgery	
< 15 mm	(3.0)
15 mm to 20 mm	(23.0)
20 mm to 30 mm	(66.7)
> 31 mm	(100)

*VCUG indicates voiding cystourethrography and DTPA, diethylene triamine pentaacetic acid renal scintigraphy.

(54.8%) patients, there were partial, complete, and bilateral obstruction in 51 (29.0%), 30 (17.0%), and 4 (2.4%) patients, respectively. Also, according to dimercaptosuccinic acid scans performed in 70 (39%) patients, cortical function reduction was indicated in the ipsilateral, contralateral, and bilateral sides in 30, 6, and 24 patients, respectively. Multicystic dysplastic kidney patients showed a single kidney on dimercaptosuccinic acid scans.

The final diagnosis included transient hydronephrosis, ureteropelvic junction obstruction, vesicoureteral reflux, ureterovesical junction obstruction, and multicystic dysplastic kidney in 30 (17%), 41 (23%), 35 (19.5%), 9 (4.9%), and 4 (2.4%) of patients, respectively. Forty-two patients (23.5%) underwent surgery and 136 (76.5%) were followed up without requiring surgery. The median APD was 14 mm, ranging from 4 mm to 60 mm. A positive correlation was found between APD and surgery rate ($P < .001$, $r = 0.60$).

The receiver operating characteristic curve was plotted to determine diagnostic accuracy of various APDs resulted in an area under the curve (AUC) of 0.925 (96% confidence interval, 0.88 to 0.97; Figure 2) and the best cutoff point for APD to differentiate the surgical cases was 15 mm with sensitivity and specificity of 95.2% and 73.5%, respectively.

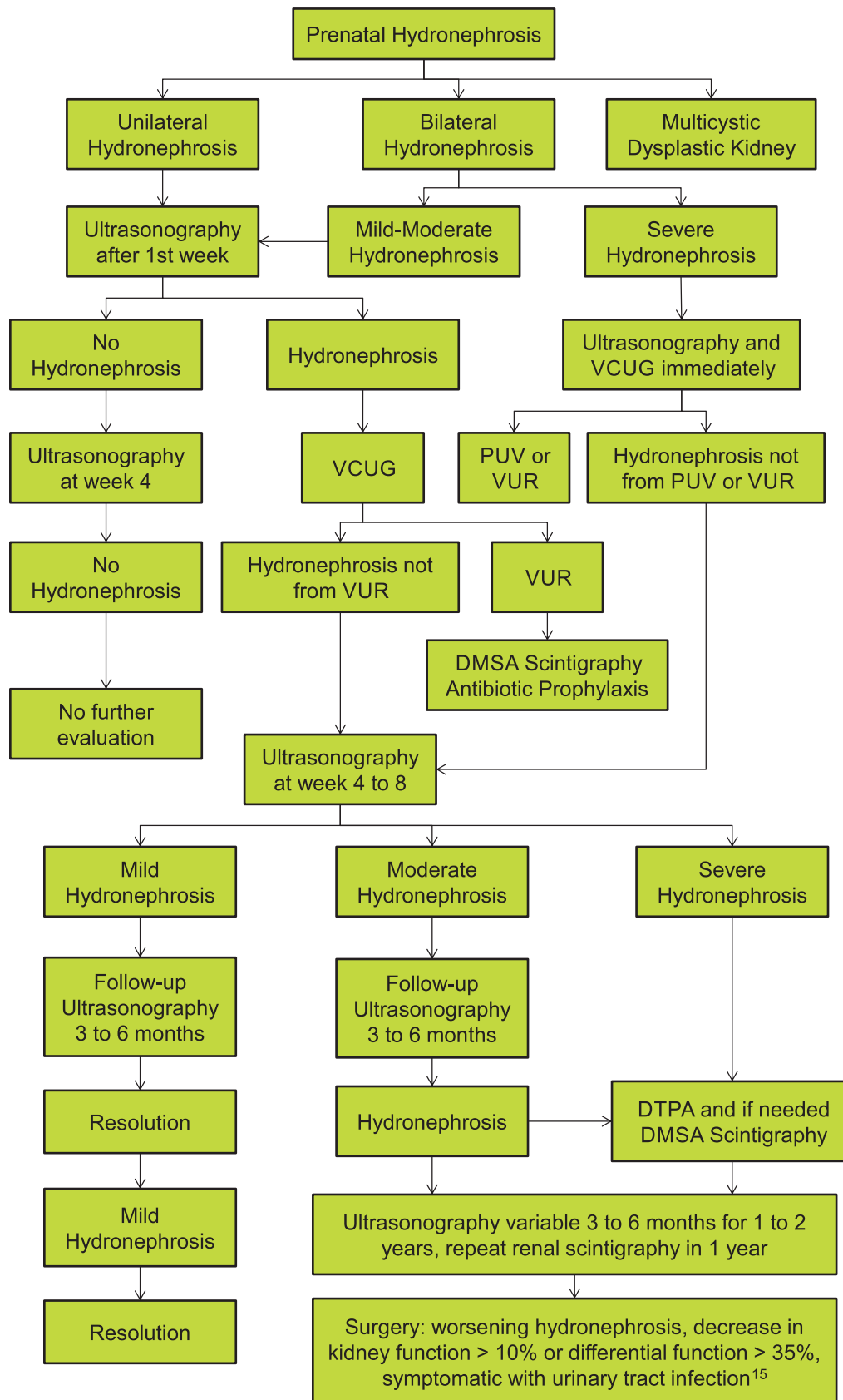


Figure 1. Algorithm of the diagnosis and management of newborns with hydronephrosis. VCUG indicates voiding cystourethrography; VUR, vesicoureteral reflux; PUV, posturethral valve; DTPA, diethylene triamine pentaacetic acid; and DMSA, dimercaptosuccinic acid.

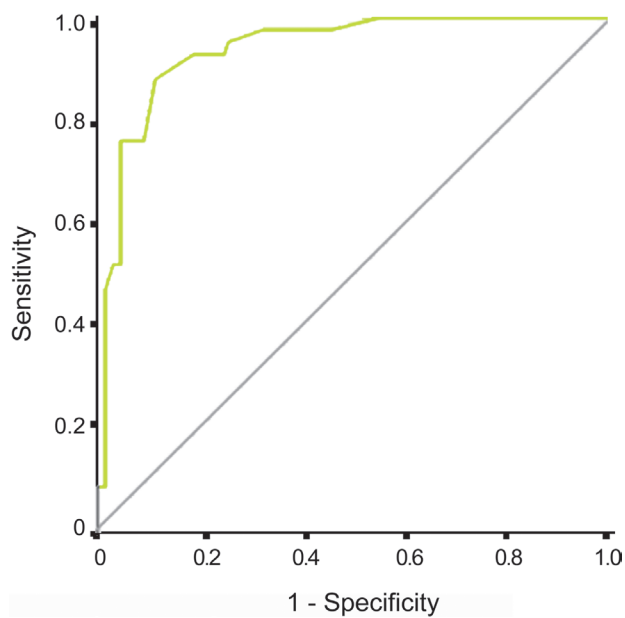


Figure 2. The receiver operating characteristic curve for predicting the need for surgery by the anterior-posterior pelvic diameter measured via renal ultrasonography. The area under the curve was 0.93 (96% confidence interval, 0.88 to 0.97).

DISCUSSION

This study was conducted to explore the diagnostic accuracy of APD in postnatal ultrasonographic evaluation to differential infants requiring surgery from those recover with conservative management and to determine the best cutoff point for APD. It could be assumed that measurements higher than this cutoff point require to be examined thoroughly by renal scintigraphy in order to find patients requiring VCUG, since patients with lower cutoff had vesicoureteral reflux and neglecting VCUG could miss some of them as studied by Ismaili and colleagues and Estrada and coworkers.^{10,15}

Some studies similar to our study show spontaneous resolution of the mild form of congenital hydronephrosis.^{11,17-19} In 4 other studies, renal pelvic diameter was considered as a predictor for uropathy. In Bouzada and colleagues' study,²⁰ the AUC estimated by the receiver operating characteristic curve was 0.921 and a cutoff of 15 mm was proposed for determining the renal units requiring surgery, which was similar to the result of our study. The AUC was reported by Halek and colleagues²¹ to be 0.847 for postnatal ultrasonography and a 7-mm APD cutoff point was considered ideal for detection of significant uropathy, which is lower than previous studies and our study's finding due to employing postnatal

ultrasonography for screening purpose. In Coplen and coworkers' study,²² a fetal renal pelvic dilatation more than 15 mm was considered a significant threshold with a sensitivity of 73% and a specificity of 82%, similar to our results except for performing analysis for prenatal APD.

According to a recent novel study,²³ using a combination of prenatal and postnatal APD with cutoff points of 18 mm and 16 mm, respectively, showed 100% sensitivity and 86% specificity. The authors suggested a combination of using prenatal and postnatal APD to increase diagnostic accuracy.

CONCLUSIONS

Measurement of APD in postnatal ultrasonography has a good prognostic accuracy for identifying neonatal cases requiring surgery and further investigations are recommended in cases with values above the cutoff point.

CONFLICT OF INTEREST

None declared.

REFERENCES

1. Assadi F, Schloemer N. Simplified diagnostic algorithm for evaluation of neonates with prenatally detected hydronephrosis. *Iran J Kidney Dis.* 2012;6:284-90.
2. Yamacake KG, Nguyen HT. Current management of antenatal hydronephrosis. *Pediatr Nephrol.* 2013;28:237-43.
3. Sinha A, Bagga A, Krishna A, et al. Revised guidelines on management of antenatal hydronephrosis. *Indian J Nephrol.* 2013;23:83-97.
4. Valent-Moric B, Zigman T, Cuk M, Zaja-Franulovic O, Malenica M. Postnatal evaluation and outcome of infants with antenatal hydronephrosis. *Acta Clin Croat.* 2011;50:451-5.
5. Rao PK, Palmer JS. Prenatal and postnatal management of hydronephrosis. *ScientificWorldJournal.* 2009;9:606-14.
6. Kitchens DM, Herndon CD. Antenatal hydronephrosis. *Curr Urol Rep.* 2009;10:126-33.
7. Estrada CR, Peters CA, Retik AB, Nguyen HT. Vesicoureteral reflux and urinary tract infection in children with a history of prenatal hydronephrosis—should voiding cystourethrography be performed in cases of postnatally persistent grade II hydronephrosis? *J Urol.* 2009;181:801-6.
8. Cordero L, Nankervis CA, Oshaughnessy RW, Koff SA, Giannone PJ. Postnatal follow-up of antenatal hydronephrosis: a health-care challenge. *J Perinatol.* 2009;29:382-7.
9. Ansari MS, Ayyildiz HS, Jayanthi VR. Is voiding cystourethrogram necessary in all cases of antenatal hydronephrosis? *Indian J Urol.* 2009;25:545-6.

10. Estrada CR, Jr. Prenatal hydronephrosis: early evaluation. *Curr Opin Urol*. 2008;18:401-3.
11. Sidhu G, Beyene J, Rosenblum ND. Outcome of isolated antenatal hydronephrosis: a systematic review and meta-analysis. *Pediatr Nephrol*. 2006;21:218-24.
12. Herndon CD. Antenatal hydronephrosis: differential diagnosis, evaluation, and treatment options. *Sci World J*. 2006;6:2345-65.
13. Fernbach SK, Maizels M, Conway JJ. Ultrasound grading of hydronephrosis: Introduction to the system used by the Society for Fetal Urology. *Pediatr Radiol*. 1993;23:478-80.
14. Lee RS, Cendron M, Kinnamon DD, Nguyen HT. Antenatal hydronephrosis as a predictor of postnatal outcome: a meta-analysis. *Pediatrics*. 2006;118:586-93.
15. Coran AG, Adzick NS, Krummel TM, Laberge JM, Shamberger R, Caldamone A. *Pediatric surgery*. 7th ed. Philadelphia: Elsevier, Mosby, Saunders; 2012. p. 1411-25.
16. Ismaili K, Auni F, Hall M. Results of systematic voiding cystourethrography in infants with antenatally diagnosed renal pelvis dilation. *J Pediatr* 2002;141:21-4.
17. Asl AS, Maleknejad S. Clinical outcome and follow-up of prenatal hydronephrosis. *Saudi J Kidney Dis Transpl*. 2012;23:526-31.
18. de Kort EH, Bambang Oetomo S, Zegers SH. The long-term outcome of antenatal hydronephrosis up to 15 millimetres justifies a noninvasive postnatal follow-up. *Acta Paediatr*. 2008;97:708-13.
19. Coelho GM, Bouzada MC, Pereira AK, et al. Outcome of isolated antenatal hydronephrosis: a prospective cohort study. *Pediatr Nephrol*. 2007;22:1727-34.
20. Bouzada MC, Oliveira EA, Pereira AK, et al. Diagnostic accuracy of fetal renal pelvis anteroposterior diameter as a predictor of uropathy: a prospective study. *Ultrasound Obstet Gynecol*. 2004;24:745-9.
21. Halek J, Flogelova H, Michalkova K, et al. Diagnostic accuracy of postnatal ultrasound screening for urinary tract abnormalities. *Pediatr Nephrol*. 2010;25:281-7.
22. Coplen DE, Austin PF, Yan Y, Blanco VM, Dicke JM. The magnitude of fetal renal pelvic dilatation can identify obstructive postnatal hydronephrosis, and direct postnatal evaluation and management. *J Urol*. 2006;176:724-7.
23. Dias CS, Silva JM, Pereira AK, et al. Diagnostic Accuracy of Renal Pelvic Dilatation for Detecting Surgically Managed Ureteropelvic Junction Obstruction. *J Urol*. 2013.

Correspondence to:
Nasrin Esfandiari, MD
Department of Pediatric Nephrology, Pediatric Respiratory
Diseases Research Center, National Research Institute of
Tuberculosis and Lung Diseases, Masih Daneshvari Hospital,
Darabad, Tehran, Iran
E-mail: nasrinesfandiari@yahoo.com

Received June 2012
Revised September 2013
Accepted September 2013