

# A Rare Incidence of Angiomyolipoma After Kidney Transplantation

Jamshid Roozbeh,<sup>1,2</sup> Ahad Eshraghian,<sup>1,2</sup> Bita Geramizadeh,<sup>1</sup> Saman Nikeghbalian,<sup>1</sup> Mehdi Salehipour,<sup>1</sup> Seyed Ali Malek-Hosseini<sup>1</sup>

<sup>1</sup>Department of Internal Medicine, Namazi Hospital, Shiraz University of Medical Sciences, Shiraz, Iran

<sup>2</sup>Organ Transplant Research Center, Namazi Hospital, Shiraz University of Medical Sciences, Shiraz, Iran

**Keywords.** kidney transplantation, angiomyolipoma, partial nephrectomy

Kidney transplantation has been established as the treatment of end-stage renal disease. Despite great improvement in transplant science, complications are still frequently seen after kidney transplantation. We describe the first case of isolated angiomyolipoma in the kidney allograft developed 3 years after transplantation and treated with partial nephrectomy of the allograft.

IJKD 2012;6:311-3  
www.ijkd.org

## INTRODUCTION

Angiomyolipoma is a benign renal tumor that originates from the mesenchymal tissue and consists of fat, smooth muscles, and thick-walled blood vessels.<sup>1</sup> It has an incidence of 0.3% to 3% and is more prevalent in women than in men, suggesting the role of female hormone in the growth of the tumor.<sup>2</sup> Isolated angiomyolipoma accounts for 80% of cases that occurs sporadically in the 4th to 5th decade of life; however, angiomyolipoma associated with tuberous sclerosis can be multiple and bilateral and mostly occurs in younger patients.<sup>3</sup>

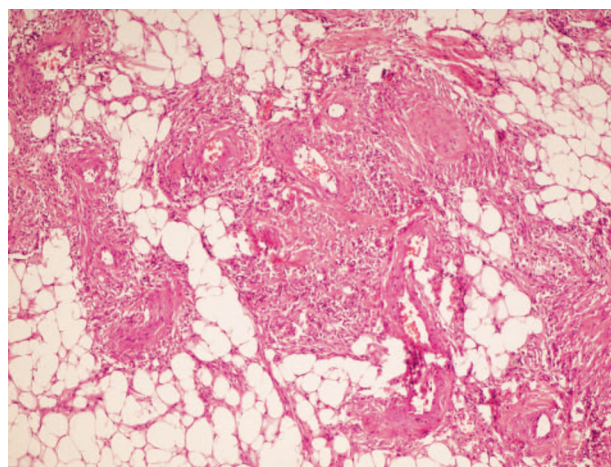
Kidney transplantation has been well established as the treatment of end-stage renal disease. Development of tumors after transplantation has been frequently reported and is a well-known complication mostly related to immunosuppressive medications. Herein, we report a very rare case of isolated angiomyolipoma in a transplanted kidney that developed 3 years after uneventful kidney transplantation.

## CASE REPORT

A 20-year-old woman with end-stage renal disease due to hypertension underwent kidney transplantation at our center. The patient received a kidney from a deceased donor and spent her postoperative period without any complication

and was discharged from hospital in good health. The patient received prednisolone, cyclosporine, and azathioprine as immunosuppressive agents. She passed an uneventful posttransplant period and was well in her routine follow-up visits in our nephrology clinic. Blood urea nitrogen and serum creatinine were 14 mg/dL and 0.75 mg/dL, respectively.

Three years after transplantation, an abdominal pelvic ultrasonography was performed for her as part of the routine checkup, which showed a large



Section from tumor in transplanted kidney show thick walled blood vessels, adipose tissue and smooth muscle which together are diagnostic for angiomyolipoma.

hyperechoic mass measuring 7.7 cm in its largest diameter with uniform echogenicity, arising from the upper pole of the transplanted kidney. She underwent abdominal computed tomography that confirmed findings of the ultrasonography. The patient underwent partial nephrectomy and the mass was removed. Gross view of the resected specimen showed a well-defined nodule measuring 7 cm in diameter. Histological findings were typical of renal angiomyolipoma (Figure). Postoperative surgery was uneventful and the patient was discharged in good health. Four years after resection of angiomyolipoma, she had a normal function of the transplanted kidney (blood urea nitrogen, 17 mg/dL and serum creatinine, 0.8 mg/dL).

## DISCUSSION

Although kidney transplantation has minimized mortalities due to end-stage renal disease, its complications are still frequent and impose considerable morbidities to the patients. In addition to surgical complications, patients receive a collection of immunosuppressive medications after transplantation that predisposes them to several medical challenges after transplantation. One of these complications is development of tumors in the kidney allograft. Posttransplant tumors can originate from 3 sources: the kidney transplant donor, recurrence of previous tumor, and de novo development.<sup>4</sup> Our patient probably developed de novo angiomyolipoma since there was no evidence of tumor in the received allograft.

The risk factors for development of tumors after kidney transplantation are not clear. However, sun exposure, long-term immunosuppressive therapy, concomitant viral infection, advanced age, and longer pretransplant dialysis periods have been described as risk factors of malignancies after kidney transplantation.<sup>5</sup> Renal cell carcinoma has been reported to occur in kidney allograft after transplantation.<sup>6</sup> Posttransplant lymphoproliferative disorders are associated with Epstein-Barr virus and immunosuppressive agents and have been reported to involve kidney allografts.<sup>7</sup> Plasmacytoma in the kidney allograft was also reported in a series of malignancies after kidney transplantation by Tremblay and colleagues.<sup>8</sup> Angiomyolipoma is a benign tumor that may occur in the kidney sporadically or as a part of genetic disorders such as tuberous sclerosis

or lymphangioliomyomatosis.<sup>1</sup> However, the incidence of angiomyolipoma in the kidney allograft is very rare. Simultaneous development of renal cell carcinoma and angiomyolipoma has been also reported by Rotman and coworkers.<sup>9</sup> To the best of our knowledge, the only case of development of solitary angiomyolipoma in the kidney allograft after transplantation was reported in a series of 445 kidney allografts,<sup>10</sup> and our patient is the second case in literature. It should be noted that other reports of angiomyolipoma in kidney allografts were of donor origin. Lappin and colleagues reported a kidney transplant patient who received kidney allograft containing angiomyolipoma and had no tumor-related complication in 7 years' follow-up.<sup>11</sup> Another case of angiomyolipoma in transplant kidney was diagnosed after postmortem examination.<sup>12</sup>

Although tumors are treated with total allograft removal,<sup>13</sup> partial nephrectomy has been applied based on the tumor size and location.<sup>14</sup> Angiomyolipoma imposes a risk of spontaneous hemorrhage, and surgical removal or radiographic embolization is usually applied for the treatment. Nephron-sparing surgery for a giant angiomyolipoma in a patient with lymphangioliomyomatosis has been reported, as well.<sup>15</sup>

In conclusion, clinicians should be aware that angiomyolipoma can occur in the renal allograft after kidney transplantation. These tumors can be managed conservatively without any complications to the kidney allograft and can be removed only if become symptomatic.

## CONFLICT OF INTEREST

None declared.

## REFERENCES

1. Nonomura A, Minato H, Kurumaya H. Angiomyolipoma predominantly composed of smooth muscle cells: Problems in histological diagnosis. *Histopathology*. 1998;33:20-7.
2. Steiner MS, Goldman SM, Fishman EK, Marshall FF. The natural history of renal angiomyolipoma. *J Urol*. 1993; 150:1782-6.
3. Blute ML, Malek RS, Segura JW. Angiomyolipoma: Clinical metamorphosis and concerns. *J Urol*. 1988;139:20-4.
4. Kauffman HM. Malignancies in organ transplant recipients. *J Surg Oncol*. 2006;94:431-3.

5. Kauffman HM, Cherikh WS, McBride MA, Cheng Y, Hanto DW. Post-transplant de novo malignancies in renal transplant recipients: the past and present. *Transpl Int*. 2006;19:607-20.
6. Feldman JD, Jacobs SC. Late development of renal carcinoma in allograft kidney. *J Urol*. 1992;148: 395-7.
7. Cobo F, Garcia C, Talavera P, Ruiz-Cabello F, Bravo J, Concha A. Diffuse large B-cell lymphoma in a renal allograft associated with Epstein-Barr virus in the recipient: a case report and a review of lymphomas presenting in a transplanted kidney. *Clin Transplant*. 2008;22:512-9.
8. Tremblay F, Fernandes M, Habbab F, deB Edwardes MD, Loertscher R, Meterissian S. Malignancy after renal transplantation: incidence and role of type of immunosuppression. *Ann Surg Oncol*. 2002;9:785-8.
9. Rotman S, Deruaz C, Venetz JP, et al. De novo concurrent papillary renal cell carcinoma and angiomyolipoma in a kidney allograft: evidence of donor origin. *Hum Pathol*. 2006;37:481-7.
10. Ditunno P, Lucarelli G, Bettocchi C, et al. Incidentally discovered yellowish lesions in a renal graft from a deceased donor. *Transplant Proc*. 2008;40:2062-4.
11. Lappin DWP, Hutchison AJ, Pearson RP, O'Donoghue DJ, Roberts ISD. Angiomyolipoma in a transplanted kidney. *Nephrol Dial Transplant*. 1999;14:1574-5.
12. Mosunjac M, Scukanec-Spoljar M, Popovic-Uroic T, Manojlovic M. Angiomyolipoma in the transplanted kidney: a case report. *Tumori*. 1992;78:52-4.
13. Roupret M, Peraldi MN, Thaunat O, et al. Renal cell carcinoma of the grafted kidney: how to improve screening and graft tracking. *Transplantation*. 2004;77:146-8.
14. De Simone P, Antonacci V, Rosa F, Verzaro R. Nephron-sparing surgery for de novo renal cell carcinoma in a 19-year-old transplanted kidney. *Transplantation*. 2004;77:478.
15. Hsu TH, O'Hara J, Mehta A, Levitin A, Klein EA. Nephron-sparing nephrectomy for giant renal angiomyolipoma associated with lymphangioliomyomatosis. *Urology*. 2002;59:138.

Correspondence to:  
 Ahad Eshraghian, MD  
 Department of Internal Medicine, Namazi Hospital, Shiraz, Iran  
 Tel: +98 711 612 5600  
 Fax: +98 711 627 6212  
 E-mail: eshraghiana@yahoo.com

Received October 2011  
 Revised February 2012  
 Accepted February 2012