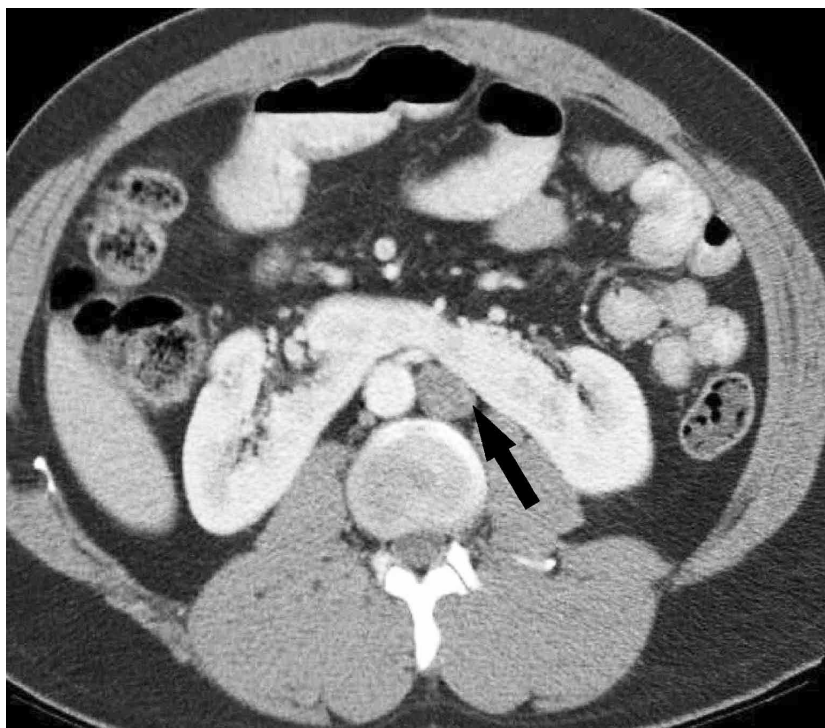


## Left-sided Inferior Vena Cava in Horseshoe Kidney An Unusual Anomaly

IJKD 2012;6:17  
www.ijkd.org



We herein report a case of 20-year-old man who underwent a contrast-enhanced computerized tomography of the pelvis for a workup of complicated urinary tract infection, which showed presence of classical horseshoe kidney and incidental left-sided infrarenal inferior vena cava (IVC). The left IVC joined the left renal vein and crossed anterior to the aorta, uniting with the right renal vein to form a normal right-sided prerenal IVC. Horseshoe kidney is a renal fusion anomaly found in about 0.2% of the general population and is more common in men.<sup>1</sup> A left IVC results from regression of the right supracardinal vein with persistence of the left supracardinal vein. Its prevalence is 0.2% to 0.5%.<sup>2</sup> Our case was highlighted by an unusual association of the horseshoe kidney and reversal in the position of the aorta and inferior vena cava. To the best of our literature search, there is no report of reversal of these major vessels in horseshoe kidney. The clinical importance lies in the fact that in the event of a need of a surgery, the position of these vessels, if ignored, could have catastrophic consequences. Radiologists commenting on imaging of these kidneys should be cautious enough not to miss such subtle anomalies and misdiagnose this for para-aortic lymphadenopathy.

Ashish Khandelwal,<sup>1</sup> Preeti Gupta,<sup>2</sup> Ankur Gupta<sup>3</sup>

<sup>1</sup>Department of Radiology, University of Ottawa, Ottawa, Canada

<sup>2</sup>Central Government Health Scheme, New Delhi, India

<sup>3</sup>Department of Nephrology, University of Ottawa, Ottawa, Canada

E-mail: parthankur@yahoo.com

### REFERENCES

1. Gupta M, Pandey AK, Goyal N. Horseshoe kidney--a case report. *Nepal Med Coll J.* 2007;9:63-6.
2. Phillips E. Embryology, normal anatomy, and anomalies. In: Ferris EJ, Hipona FA, Kahn PC, Phillips E, Shapiro JH, editors. *Venography of the inferior vena cava and its branches.* Baltimore, Md: Williams & Wilkins; 1969. p. 1-32.