

Early Recurrence of Diabetic Nodular Sclerosis in a Kidney Transplant Recipient

Malleshappa Pavan,¹ Ravi Ranganath,² Anup P Chaudhari²

¹Department of Nephrology, Vaatsalya Hospital, Bharathi Healthcare Complex, Hassan, Karnataka, India

²Department of Nephrology, Lilavati Hospital and Research Centre, Bandra West, Mumbai, India

Keywords. diabetic nephropathies, kidney transplantation, recurrence

Almost all kidney transplant recipients with diabetes mellitus will eventually develop recurrence of diabetic nephropathy in their allograft. Despite this high incidence, there are very few reported cases of diabetic nephropathy of diffuse type, and the nodular sclerosis form is uncommon. Recurrence of diabetic nephropathy of nodular glomerulosclerosis type usually occurs during the second decade of transplantation. We report a rare case of diabetic nodular glomerulosclerosis developing 5 years after transplantation, leading to progressive kidney dysfunction and graft loss.

IJKD 2012;6:219-21
www.ijkd.org

INTRODUCTION

Almost all kidney transplant patients with diabetes mellitus will eventually develop alterations attributable to glucose intolerance in their allograft.¹ Despite advances in prevention of acute rejection and improved short- and long-term kidney allograft survival, recurrent glomerulonephritis remains problematic and poorly characterized. There have been improvements in short- and long-term graft survival after kidney transplantation in the past 2 decades. Development of new immunosuppressive medications has been targeted toward controlling acute and chronic rejections but has not influenced the occurrence and outcome of recurrent glomerulonephritis after kidney transplantation. Recurrence of diabetic nephropathy with rapid deterioration of kidney function, leading to graft loss within the 1st decade of transplantation, is uncommon. We highlight a rare combination of nodular glomerulosclerosis leading to rapid worsening of kidney allograft function and graft loss.

CASE REPORT

A 52-year-old man with kidney allograft presented with generalized weakness, vomiting, and worsening edema. He had end-stage renal disease due to diabetic nephropathy for 7 years

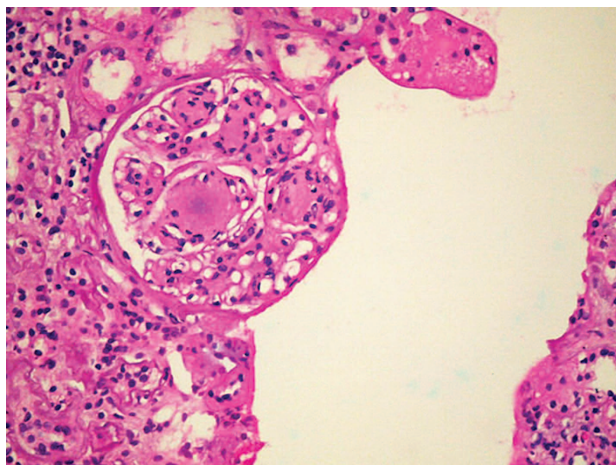
and suffered from type 2 diabetes mellitus and hypertension for 20 years, complicated with diabetic retinopathy, autonomic and sensory neuropathy, and neuropathic joints. He underwent living donor kidney transplantation 5 years earlier. The donor was his wife, nondiabetic and nonhypertensive with normal kidney function (creatinine 0.7 mg/dL). He had a stable graft function for almost 3 years. His immunosuppressive medication included prednisolone, cyclosporine, and azathioprine. Throughout the course, his blood glucose level was kept under control with the help of regular insulin and his haemoglobin A1c levels were maintained at 6.8%. However, his blood pressure used to be highly variable and he used to experience frequent episodes of hypotension. His average supine blood pressure was around 160/100 mm Hg and standing blood pressure was 100/60 mm Hg.

Two years earlier he was detected to have proteinuria (1.2 g/d) on routine follow-up, with normal kidney function. Five months earlier, he developed pedal edema and was found to have a serum creatinine of 2 mg/dL. He was not on any antihypertensive medications till that time. He was advised to undergo transplant kidney biopsy at that time, but the patient refused.

On admission he was edematous, afebrile, conscious, alert, and well oriented. His pulse

was 78/min, blood pressure was 150/90 mm Hg (supine) and 110/70 mm Hg (standing). He had bilateral symmetrical sensory neuropathy with absent dorsalis pedis and posterior tibial artery pulsations on both legs. Other systemic examinations were unremarkable. His laboratory investigation results on admission were as follows: blood urea nitrogen, 44.4 mg/dL; serum creatinine, 3.8 mg/dL; haemoglobin, 8.8g/dL; total leukocyte count, $6.3 \times 10^9/L$; platelet count, $248 \times 10^9/L$; serum albumin, 2.68 g/dL; serum calcium, 7 mg/dL; and serum phosphorus, 5.4 mg/dL. Urinalysis revealed albumin excretion, 3+; leukocyte count, 5 to 6 per high-power field; and erythrocyte count, 1 to 2 per high-power field. The spot urine showed a protein-creatinine ratio of 11.79. Ultrasonography of the transplant kidney was normal and Doppler ultrasonography of the transplant kidney revealed increased resistive indexes in the main renal artery and the interlobar artery and its branches.

Allograft biopsy was performed in view of nephrotic-range proteinuria and worsening of kidney function. On light microscopy, there were 22 glomeruli, most of which (> 50%) were sclerosed or obsolescent. The residual glomeruli showed increase in mesangial matrix, some of which were nodular in configuration (Figure). The afferent arteriole showed hyalinized walls. Patchy interstitial fibrosis and tubular atrophy were present. These findings were suggestive of recurrence of diabetic nephropathy class IV, interstitial fibrosis and tubular atrophy score 3, interstitial inflammation score 2, and arteriosclerosis score 2 in the transplant



The glomerulus shows a well-developed Kimmelsteil-Wilson lesion, with nodular sclerosis of glomerular tuft (hematoxylin-eosin).

kidney. Immunofluorescence staining was negative for immunoglobulin and complement components. Immunohistochemistry was negative for light and heavy chains. Electron microscopy showed no evidence of electron dense deposits in the glomeruli or tubules.

In spite of strict blood glucose control throughout the course, our patient had a rapid deterioration in his kidney function and he became dialysis dependent within 6 months of diagnosis of nodular glomerulosclerosis.

DISCUSSION

It is estimated that approximately 10% to 20% of patients with glomerulonephritis develop recurrence in the allograft and 50% of them lose their graft on long-term follow-up, thus having a negative impact on long-term graft survival.² Diagnosis and management of recurrence of native glomerulonephritis is critical to optimize and improve long-term kidney transplant graft survival and also provides a unique opportunity to explore the pathogenesis of native kidney disease.³ The goal should be to understand the pathogenesis of recurrent glomerulonephritis and to implement protocols for the prevention and treatment of recurrent glomerulonephritis, thus optimizing kidney transplant outcome.

Diabetes mellitus is the most common systemic disorder that leads to end-stage renal disease. In almost all of the allografts, there will be recurrence of glomerular basement membrane thickening and mesangial expansion 2 years after transplantation and hyalinization of afferent and efferent arterioles by 4 years. Prior to this linear staining for immunoglobulin G along glomerular and tubular basement membranes may be detectable. However, the typical nodular glomerulosclerosis is uncommon in these patients.⁴ Nodular glomerulosclerosis was documented on histology in our patient.

Studies have shown development of nodular glomerulosclerosis in patients with hypertension, smoking, obesity, and intermittent hyperglycemia predated the diagnosis of diabetes mellitus.⁵ Our patient was nonsmoker, not obese and had a stable and good glycemic control. Therefore, the most probable cause of nodular glomerulosclerosis in our patient would be recurrence of diabetic nephropathy in the transplanted kidney. In the report of Mauer and coworkers, diabetic glomerular

changes were demonstrated within 2 years of transplanting normal kidneys into diabetics, but graft failure was thought to be rare at least before the 10th year after transplant.⁶ On the other hand, Hariharan and associates studied 14 patients with recurrent diabetic nephropathy and found severe advanced morphological changes after a mean of 8 years.⁷ Tinel and coworkers reported a rapid recurrence of diabetic nephropathy 2 years after kidney transplantation in a 56-year-old Caucasian man.⁸ Bhalla and colleagues reported that the mean duration of diabetes mellitus at the time of a histologic diagnosis of recurrence of diabetic nephropathy was 6.68 ± 3.86 years.⁹

The mechanism for recurrence of diabetic nephropathy has not been fully elucidated. In studies examining the development of diabetic nephropathy in native kidneys, 3 pathogenic theories have been proposed: genetic, metabolic, and hemodynamic factors.¹⁰ The genetic theory proposes that the development of microvascular complications is related to a genetic predisposition of the individual. Certain human leukocyte antigen phenotypes, notably DR4, B8, and B15, have been associated with nephropathy. With the metabolic theory, glycemic control, either with exogenous insulin replacement or islet cell transplantation, is felt to play a major role in the genesis of the disease. Proponents of the hemodynamic theory state that changes in renal hemodynamics, including the increase in renal plasma flow and transcapillary hydraulic pressure in the glomerulus that leads to diabetic kidney disease.

Clinically, most patients present with proteinuria and a slow decline in allograft function over a period of many years, with graft loss seen in the 2nd decade posttransplantation in less than 5% of patients.¹ Our patient, despite having tight blood glucose control, went on to develop graft loss within 5 years of transplantation. Significant hemodynamic alteration following diabetic autonomic neuropathy leading to increase in transcapillary hydraulic pressure which in turn leads to proteinuria and nephropathy might be the most probable cause of rapid deterioration in kidney function in our patient.

CONFLICT OF INTEREST

None declared.

REFERENCES

1. Owda AK, Abdallah AH, Haleem A, et al. De novo diabetes mellitus in kidney allografts : nodular sclerosis and diffuse glomerulosclerosis leading to graft failure. *Nephrol Dial Transplant.* 1999;14:2004-7.
2. Briganti E, Russ G, McNeil J, Atkins R, Chadban S. Risk of renal allograft loss from recurrent glomerulonephritis. *N Engl J Med.* 2002;347:103-9.
3. Cameron JS. Glomerulonephritis in renal transplants. *Transplantation.* 1982;34:237-45.
4. Maryniak RK, Mendoza N, Clyne D, Balakrishnan K, Weiss MA. Recurrence of diabetic nodular glomerulosclerosis in a renal transplant. *Transplantation.* 1985;39:35-8.
5. Navaneethan SD, Singh S, Choudhry W. Nodular glomerulosclerosis in a non-diabetic patient: case report and review of literature. *J Nephrol.* 205:18;613-5.
6. Mauer SM, Steffes MW, Najarian JS, Sutherland DER, Barbosa J. The development of lesions in the glomerular basement membrane and the mesangium after transplantation of normal kidneys to diabetic patients. *Diabetes.* 1983;32:948-52.
7. Hariharan S, Smith RD, Viero R, First MR. Diabetic nephropathy after renal transplantation: clinical and pathologic features. *Transplantation.* 1996;62:632-5.
8. Tinel C, Martin L, Cabanne JF, Tanter Y, Riffe G, Mousson C. Early recurrence of type 2 diabetic nephropathy after kidney transplantation. *Clin Nephrol.* 2011;75:179-80.
9. Bhalla V, Nast CC, Stollenwerk N, et al. Recurrent and de novo diabetic nephropathy in renal allografts. *Transplantation.* 2003;75:66-7.
10. Reddi AS, Camerini-Davalos RA. Diabetic nephropathy: an update. *Arch Intern Med.* 1990;150:31-43.

Correspondence to:

Mallesappa Pavan, MD

Department of Nephrology, Vaatsalya Hospital, Bharathi Healthcare Complex, R C Rd, Hassan- 573201, Karnataka State, India

Tel: +91 8172 251707

E-mail: dr_pavanm@yahoo.co.in

Received July 2011

Revised August 2011

Accepted September 2011