

Interpretation of Renal Volume in Autosomal Dominant Polycystic Kidney Disease and Relevant Clinical Implications

Amirali Masoumi, Elwaleed Elhassan, Robert W Schrier

Department of Medicine,
University of Colorado Denver,
Aurora, Colorado, USA

Keywords. autosomal dominant polycystic kidney disease, kidney failure, hypertension, renin-angiotensin system

Autosomal dominant polycystic kidney disease (ADPKD) is the most common life-threatening hereditary disease of the kidney. It presents with progressive enlargement of the kidneys with numerous cysts that distort the parenchyma and result in progressive decline in kidney function. Autosomal dominant polycystic kidney disease is genetically modified with the responsible genes localized to separate loci on chromosome 16 (*PKD1* gene), accounting for the majority of ADPKD cases, and chromosome 4 (*PKD2* gene), accounting for the remainder. This review discusses the current understanding of the pathogenesis of ADPKD, focusing on renal volume and its pivotal role on the manifestations of the disease. Specifically, activation of the renin-angiotensin-aldosterone system, hypertension, left ventricular hypertrophy, kidney function deterioration, pain, and hematuria are examined as consequences of renal volume increase. Recent developments on diagnostic modalities and criteria of the ADPKD are also discussed.

IJKD 2011;5:1-8
www.ijkd.org

INTRODUCTION

Autosomal dominant polycystic kidney disease (ADPKD) is the most common genetic disease of the kidney. It affects all races, with an estimated frequency of 1 in 400 to 1 in 1000 live births.¹ It is a systemic disease characterized by multiple bilateral renal cysts, resulting in massive kidney enlargement and progressive functional impairment. Usually, only a few renal cysts are detected in most affected individuals before 30 years of age. However, by the 5th decade of life, numerous renal cysts will be found in the majority of patients. The degree of kidney enlargement correlates with complications such as pain, hematuria, hypertension, and renal insufficiency.

PATHOGENESIS

Autosomal dominant polycystic kidney disease is a heterogeneous disease with 2 gene loci, *PKD1* on chromosome 16 and *PKD2* on chromosome 4. Approximately, 85% of cases are *PKD1*, while

PKD2 accounts for 15% of ADPKDs. *PKD1* genotype is associated with the more severe form of the disease. Cyst number, cyst growth, and eventually, renal expansion are more pronounced in this subgroup. Incidence of hypertension and proteinuria are significantly higher among patients with the *PKD1* genotype.² These patients reach end-stage renal disease (ESRD) 20 years earlier on average than the *PKD2* cases do (age at ESRD, 54.3 years versus 74.0 years for *PKD1* and *PKD2*, respectively).³ It has been shown that the more severe course of the disease in *PKD1* patients is associated with more cyst formation at early ages rather than cyst enlargement.⁴ Both polycystin-1 and polycystin-2, encoded by *PKD1* and *PKD2* genes, are essential for proper differentiation and low-rate proliferation of the tubular epithelial cells.⁵⁻⁷ Impaired function of any of these protein complexes leads to disrupted intracellular signaling, ciliary dysfunction, apoptosis, and excessive fluid secretion into tubuloepithelium-originated cysts.⁸

It has been demonstrated that only 1% of nephrons will develop cysts. Potentially, cysts can arise from all segments of the nephron; however, collecting duct cysts are more predominant.⁹ These cysts tend to expand continuously, and ultimately, detach from the parent tubules, yet continue to grow.^{7,10,11} A large body of evidence indicates that a considerable proportion of cysts form in utero and progressively enlarge from birth to the 6th decade of life.¹²⁻¹⁸ In a longitudinal ultrasonographic study on 182 children between birth and 20 years of age, Fick-Brosnahan and colleagues reported that age-matched children with ADPKD had larger renal volumes compared to healthy controls.¹⁹ In 2002, the same group at the University of Colorado conducted the first sequential quantitative study of total renal volumes in adults with ADPKD. They followed 229 patients aged between 19 to 81 years, over a mean interval of 7.8 years. The mean rate of renal growth documented by ultrasonography was 8.2% per year.¹⁴ Increased renal volume at baseline was significant in this study, as well (mean baseline total renal volume of 1122 mL). In recent years, the Consortium of Radiologic Imaging Studies of Polycystic Kidney Disease (CRISP) published the early analysis of their invaluable study. They showed that the total kidney and cyst volumes increased exponentially.¹² Over a span of 3 years, 241 nonazotemic (glomerular filtration rate [GFR], > 60 mL/min/1.73 m²) adult ADPKD patients aged 15 to 49 years old at baseline were followed up prospectively with yearly magnetic resonance imaging (MRI) examinations. At baseline, the mean combined volume of both kidneys was 1060 ± 642 mL with a mean increase of 204 mL per year (5.3% per year). Total cyst volumes were reported to be 540 mL at baseline and increased by a mean of 12.0% per year over a 3-year period. These findings strongly indicate that total renal volume is a harbinger of subsequential renal growth, and ultimately, kidney function impairment. Although *PKD1* kidneys had more cysts and were larger than *PKD2* kidneys at baseline, the rates of growth were not significantly different (5.68% per year versus 4.82% per year). Thus genotype likely determines the cyst initiation not cyst expansion. In 2009, Kistler and coworkers from Switzerland provided more support for CRISP findings. The results of total kidney and cyst volumes as well as the growth rates in their 6-month MRI study of

100 adult *PKD1* patients were remarkably similar to the CRISP study.²⁰

CONSEQUENCES OF RENAL ENLARGEMENT Renin-Angiotensin-Aldosterone System

Activation of renin-angiotensin-aldosterone system (RAAS) in ADPKD has been demonstrated in several studies. On the other hand, angiographic studies have shown that cyst expansion is associated with the compression of the adjacent parenchyma and vasculature. This results in local glomerular ischemia/hypoxia.^{21,22} Graham and associates reported hyperplasia of renin-containing cells along the arterioles and within cyst walls.²³ Moreover, elevated levels of renin have been detected in both renal tissue and cyst fluid of ADPKD kidneys.²⁴ In 2004, Loghman-Adham and colleagues described an intrarenal role of RAAS in ADPKD by detecting the angiotensinogen, angiotensin-converting enzyme (ACE), angiotensin II type I (AT1) receptor, and angiotensin II within cysts and tubules.²⁵ The first clinical study that indicated the activation of RAAS in ADPKD resulted from comparing the effect of ACE inhibitor on plasma renin activity (PRA) in hypertensive versus normotensive patients.²⁶ Plasma renin activity was significantly higher in the hypertensive group despite treating with ACE inhibitors. This finding has been confirmed by measuring PRA and aldosterone levels in hypertensive ADPKD patients versus patients with essential hypertension who were matched for blood pressure (BP), renal function, age, and sodium intake.²⁷ The results demonstrated a prominent increase of PRA and aldosterone in the supine and upright positions, as well as after ACE inhibitor administration, in ADPKD patients. Moreover, with ACE inhibitor, hypertensive ADPKD participants exhibited a significant decrease in renal vascular resistance and consequently an increase in renal blood flow compared to essential hypertension patients.^{28,29}

It has been demonstrated that intrarenal as well as circulatory RAAS is highly activated in ADPKD, whereas there is controversy about the importance of the circulating RAAS.³⁰ Doulton and colleagues showed equivalent activation of RAAS in hypertensive ADPKD and essential hypertension patients with low or high sodium intake and also after administration of ACE inhibitors.³¹ Increased PRA and serum aldosterone have been

documented not only in hypertensive ADPKD, but also in normotensive patients with preserved kidney function.³²

It has been well understood that early activation of RAAS occurs while ADPKD patients are completely asymptomatic, and this will proceed with hypertension. Although hypertension in ADPKD is multifactorial,³³ activation of RAAS plays a major role in its pathogenesis. Hypertension is highly frequent in the ADPKD with substantial contribution to the disease progression and related morbidity and mortality. Approximately, 60% of the patients develop hypertension without any decline in their GFR ($> 75 \text{ mL/min/1.73 m}^2$).^{34,35}

Hypertension

The incidence of hypertension is at a much younger age in ADPKD (32 and 34 years of age for men and women, respectively). Hypertension occurs even earlier in ADPKD patients with affected hypertensive parents.³⁶ As mentioned earlier, activation of RAAS is associated with cyst expansion and renal growth, and therefore, hypertension. This correlation has been strongly confirmed by several studies.^{14,37-41} Recently, Cadnapaphonchai and coworkers, in a 5-year randomized study among 85 ADPKD children, reported a strong relationship between renal volume expansion and BP. The results were significant for more aggressive increase in kidney size in hypertensive children (BP > 95 th percentile) than children with borderline hypertension (BP < 95 th percentile).¹⁸ This clinical trial validates previous reports, describing renal volume as the most relevant characteristic of disease progression in children.^{19,42} Similarly, in adults with ADPKD, renal volume, measured either by ultrasonography or MRI, was significantly larger in hypertensive patients.^{38,43}

Left Ventricular Mass Index

One of the most important and life-threatening consequences of prolonged hypertension in ADPKD is left ventricular hypertrophy. Cardiovascular diseases are the leading cause of death among ADPKD patients in the era of renal replacement therapy.⁴⁴ Left ventricular hypertrophy, of note, is a major independent risk factor, which exacerbates cardiac morbidity.⁴⁵ There is a firm and direct correlation between mean arterial pressure and left ventricular mass index.^{44,46-48} In Cadnapaphonchai

and colleagues' study, this correlation among ADPKD children was well demonstrated not only in hypertensive participants, but also in patients with borderline hypertension.⁴⁹ In 116 ADPKD patients in their early 40s, left ventricular hypertrophy was reported in 46% of male and 37% of female patients.^{50,51} Of interest, 23% of these patients were normotensive. Nondipper ADPKD patients, those with a BP that does not decrease at night, exhibited higher left ventricular mass index compared to dippers.⁵²

In summary, renal enlargement is associated with RAAS activation, hypertension, and eventually, left ventricular mass index increase.

RENAL VOLUME: A HARBINGER

The development of kidney failure in ADPKD is multifactorial and highly variable. As mentioned previously, genotype (*PKD1* versus *PKD2*), site of mutation in *PKD1* gene and modifier genes have significant impact on the clinical course of the disease.⁵³ According to several cross-sectional and longitudinal human studies, an inverse correlation between GFR and total renal volume has been well described.^{14-16,39,40} Participants in the CRISP study who were older than 30 years with a total renal volume above 1500 mL at baseline had a greater GFR decline ($4.33 \pm 8.07 \text{ mL/min per year}$).¹² These findings demonstrate that not only total renal volume, but also the rate of cyst, and eventually, renal growth, are strongly associated with the decline in GFR.

As a consequence of hyperfiltration and compensation of unaffected nephrons, in the vast majority of patients, and despite an insidious and constant increase in renal volume, kidney function remains preserved until the 4th to 6th decade of life. By the time the GFR starts to decline, the average rate of loss is about 4.4 mL/min/y to 5.9 mL/min/y .⁵⁴ Therefore, GFR, or its surrogate serum creatinine, seems to be a poor indicator to estimate how advanced the disease is.

Recently, it has been proposed that renal volume can be used as a predictor of ADPKD progression. For clinicians, incorporating only one measurement of total renal volume by ultrasonography, computed tomography, or MRI will allow them to estimate the patient's kidney expansion rate and expected volume in the years ahead (Figure 1).^{13,55} In most of the patients, the kidneys grow symmetrically;

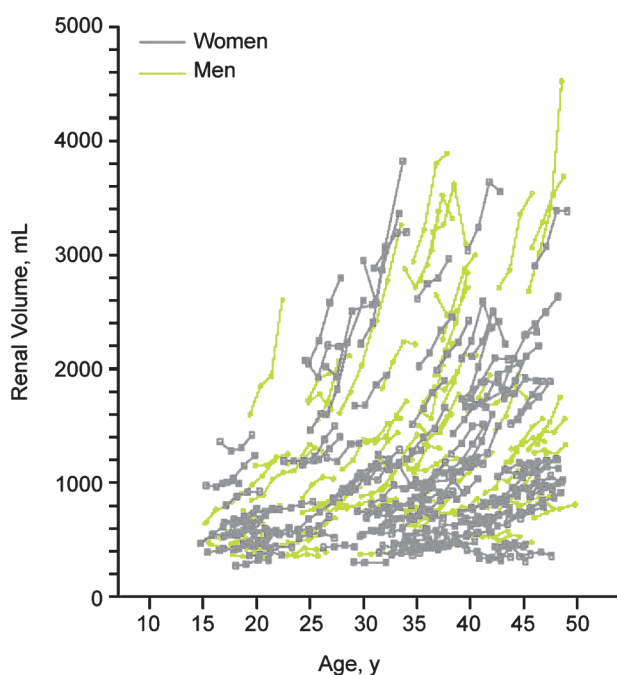


Figure 1. Prognostic value of volume measurements from the Consortium of Radiologic Imaging Studies of Polycystic Kidney Disease study. Reprinted with permission obtained from Massachusetts Medical Society.¹³

however, in some rare cases, asymmetric cyst distribution has been described either within or between the kidneys.⁵⁵ In these cases, although the total renal volume could be the same as those of the kidneys with symmetric cystic pattern, the amount of preserved parenchyma might be different. Thus, the association between GFR and

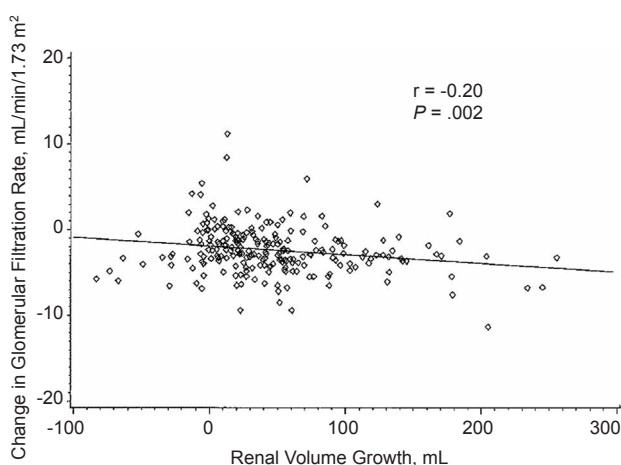


Figure 2. Relationship between change in glomerular filtration rate and rate of kidney growth in adults with autosomal dominant polycystic kidney disease ($R = 0.20$; $P = .002$), adapted from a study of Fick-Brosnahan and colleagues.¹⁴ Reprinted with permission from Elsevier.

total renal volume might be different from the majority of patients.

Understanding the clinical implication of patients' renal volume and estimated growth rate is very important to stratify at-risk patients (Figure 2).^{14,55} The patients with larger kidneys and rapid progression should be monitored more frequently in terms of disease-related complications, especially blood pressure control. On the other hand, measuring total renal volume will provide us with a reliable indicator to evaluate if the renal growth rate is in the expected range or has been accelerated.

PAIN AND HEMATURIA

The most common symptom in ADPKD patients is pain, which can occur acutely or chronically. Approximately, 60% of patients experience pain during the course of the disease.³³ Patients may present mainly with lower back pain (71.3%), radiculopathies (29.6%), and abdominal pain (61.4%). Abdominal pain can be described as dull pain, uncomfortable fullness, stabbing pain, and cramping.⁵⁶ Cyst rupture or hemorrhage, infected cysts, and nephrolithiasis are the most frequent etiologies of acute pain. It has been shown that stone formation is related to higher cyst numbers and also larger cysts. Cyst enlargement with secondary renal collecting duct distortion and consequent urine stasis might be the relevant pathophysiology of this finding.⁵⁷ Cyst rupture and kidney stones are commonly associated with gross hematuria. Gross hematuria is also highly related to the kidney size and hypertension.^{58,59} Progressive cyst growth contributes to chronic pain. This is due to the renal capsule stretch, renal pedicle traction, and also partial occlusion of collecting ducts.^{60,61} Moreover, cyst decompression and volumetric reduction procedures and their resultant pain relief, provide sufficient evidence to establish the relationship between the cysts and pain. However, in about 24 months after these interventions, pain symptoms will reappear in more than 40% of the patients.

DIAGNOSIS

The diagnosis of ADPKD is usually made by the aid of imaging modalities. However, the importance of the patient's education and awareness of the hereditary basis of the disease is indisputable.

This has led to the formation of better family histories and earlier diagnosis of ADPKD.⁶² Considering the availability, cost, and safety, the ultrasonography modality has become the main diagnostic tool in the diagnosis of ADPKD.⁶³ Cysts larger than 10 mm can reliably be detected by ultrasonography.⁶⁴ According to the recently revised Ravine's criteria for diagnosis of ADPKD by ultrasonography, presence of at least 3 renal cysts (unilateral or bilateral) is sufficient for diagnosis of at-risk individuals aged 15 to 39 years old (Table).⁶⁵ For at-risk individuals aged 40 to 59 years old and 60 years and older, respectively, 2 and 4 cysts in each kidney are diagnostic. Although the positive predictive value of these criteria is 100%, their sensitivity and negative predictive value for *PKD2* is low, especially in at-risk individuals younger than 15 years old (about 67%). However, in at-risk individuals with unknown family genotype, the absence of any renal cyst via ultrasonography associates with a negative predictive value of 100%. Normal kidneys or one renal cyst in individuals older than 40 years old is definitive for disease exclusion.⁶⁵ While the Ravine's criteria focus on at-risk individuals older than 15 years, recently, Reed and colleagues at the University of Colorado evaluated 420 children aged 15 years or younger with a positive family history. They reported bilateral renal cysts found on ultrasonography in 71.5% (181 of 253) of children who had repeated evaluation before 15 years. Of interest, 65% (17 of 26) of children who originally had unilateral cysts developed bilateral cysts on follow-up at the age of 15 or younger. Acknowledging that unilateral cysts might be the only early manifestation of ADPKD in children younger than 15 years, this study supports precise family history taking and further MRI studies to differentiate ADPKD from the entity termed *unilateral renal cystic disease*.⁶⁶ In cases of uncertainty, especially in organ donor individuals with a positive family history of

ADPKD, more expensive modalities such as MRI or computed tomography would be the preferred techniques. These highly sensitive methods will enable the detection of even very small cysts (2 mm).⁵⁵ Although it has been suggested that ultrasonography provides merely the same sensitivity as MRI in children, incapability to detect short-term prognosis of the disease is of another limitation of ultrasonography.⁶⁶ In contrast, MRI has been shown to be more precise and reliable to evaluate total renal and cyst volumes as well as cystic changes over a short-term period.^{20,67} Kistler and coworkers showed that the MRI without gadolinium to evaluate total kidney and cyst volumes has the same accuracy as the contrast-enhanced method used in the CRISP study.²⁰ This is a promising finding in reducing the cost of imaging and prevents the potential risk of developing contrast-induced nephropathy, especially in patients with advanced disease.

With all the advances in imaging techniques, the current available methods to measure kidney and cyst volumes are manual, reader dependent, and time consuming. Developing precise, reproducible, practical, semi or full automatic modalities is highly essential. In addition to imaging studies, genetic testing can always be used in equivocal or indefinite cases. Prenatal and preimplantation genetic testing are rarely considered for ADPKD.^{43,68} Genetic testing can be done either by linkage or sequence analysis. There are limitations to both techniques. Linkage analysis requires the cooperation of affected family members.⁶⁹ *PKD1* is a large and complex gene, which makes molecular testing by direct DNA analysis difficult (mutation identification, about 90%). Within families with *PKD1* gene, a mutation at the 5' end correlates with a more severe phenotype, earlier onset of ESRD, and higher risk of cerebral aneurysms.⁷⁰ No such genotype-phenotype association has been established for *PKD2* mutations. However, since

Ultrasonographic Criteria for Diagnosis of Autosomal Dominant Polycystic Kidney Disease*

Age, y	Criteria		
	Original Ravine's PKD1 Diagnostic Criteria	Revised Unified Diagnostic Criteria	Revised Criteria for Exclusion of Diagnosis
15 to 29	≥ 2 cysts, unilateral or bilateral	≥ 3 cysts, unilateral or bilateral	≥ 1 cyst
30 to 39	≥ 2 cysts in each kidney	≥ 3 cysts, unilateral or bilateral	≥ 1 cyst
40 to 59	≥ 2 cysts in each kidney	≥ 2 cysts in each kidney	≥ 2 cysts
≥ 60	≥ 4 cysts in each kidney	≥ 4 cysts in each kidney	≥ 4 cysts in each kidney

*Adapted from a study of Pei and colleagues.⁶⁵ *PKD1* indicates polycystic kidney disease 1.

most of the *PKD1* mutations are unique and up to one-third are missense, the pathogenicity of some changes is difficult to describe.^{71,72}

CONCLUSIONS

In summary, renal enlargement is associated with RAAS activation and hypertension with consequent left ventricular hypertrophy, as well as pain and hematuria. Understanding the clinical implication of patients' renal volume and estimated growth rate is important for risk stratification. Ultrasonography remains a low-cost and reliable means to diagnose APDKD in the proper context. Newly proposed ultrasonographic criteria have been discussed. The more precise imaging modalities such as MRI or computed tomography should supplement ultrasonography in cases of uncertainty.

CONFLICT OF INTEREST

None declared.

REFERENCES

- Eccer T, Fick-Brosnahan G, Schrier RW. Polycystic kidney disease. In: Schrier RW, editor. *Diseases of the kidney and urinary tract*. 8th ed. Philadelphia, PA: Lippincott Williams & Wilkins; 2006. p. 502-24.
- Masoumi A, Reed-Gitomer B, Kelleher C, Bekheirnia MR, Schrier RW. Developments in the management of autosomal dominant polycystic kidney disease. *Ther Clin Risk Manag*. 2008;4:393-407.
- Hateboer N, v Dijk MA, Bogdanova N, et al. Comparison of phenotypes of polycystic kidney disease types 1 and 2. European PKD1-PKD2 Study Group. *Lancet*. 1999;353:103-7.
- Harris PC, Bae KT, Rossetti S, et al. Cyst number but not the rate of cystic growth is associated with the mutated gene in autosomal dominant polycystic kidney disease. *J Am Soc Nephrol*. 2006;17:3013-9.
- Nauli SM, Alenghat FJ, Luo Y, et al. Polycystins 1 and 2 mediate mechanosensation in the primary cilium of kidney cells. *Nat Genet*. 2003;33:129-37.
- Patel V, Chowdhury R, Igarashi P. Advances in the pathogenesis and treatment of polycystic kidney disease. *Curr Opin Nephrol Hypertens*. 2009;18:99-106.
- Torres VE, Harris PC, Pirson Y. Autosomal dominant polycystic kidney disease. *Lancet*. 2007;369:1287-301.
- Masoumi A, Reed-Gitomer B, Kelleher C, Schrier RW. Potential pharmacological interventions in polycystic kidney disease. *Drugs*. 2007;67:2495-510.
- Grantham JJ, Geiser JL, Evan AP. Cyst formation and growth in autosomal dominant polycystic kidney disease. *Kidney Int*. 1987;31:1145-52.
- Belibi FA, Reif G, Wallace DP, et al. Cyclic AMP promotes growth and secretion in human polycystic kidney epithelial cells. *Kidney Int*. 2004;66:964-73.
- Nadasdy T, Laszik Z, Lajoie G, Blick KE, Wheeler DE, Silva FG. Proliferative activity of cyst epithelium in human renal cystic diseases. *J Am Soc Nephrol*. 1995;5:1462-8.
- Grantham JJ, Chapman AB, Torres VE. Volume progression in autosomal dominant polycystic kidney disease: the major factor determining clinical outcomes. *Clin J Am Soc Nephrol*. 2006;1:148-57.
- Grantham JJ, Torres VE, Chapman AB, et al. Volume progression in polycystic kidney disease. *N Engl J Med*. 2006;354:2122-30.
- Fick-Brosnahan GM, Belz MM, McFann KK, Johnson AM, Schrier RW. Relationship between renal volume growth and renal function in autosomal dominant polycystic kidney disease: a longitudinal study. *Am J Kidney Dis*. 2002;39:1127-34.
- King BF, Reed JE, Bergstralh EJ, Sheedy PF, 2nd, Torres VE. Quantification and longitudinal trends of kidney, renal cyst, and renal parenchyma volumes in autosomal dominant polycystic kidney disease. *J Am Soc Nephrol*. 2000;11:1505-11.
- Sise C, Kusaka M, Wetzel LH, et al. Volumetric determination of progression in autosomal dominant polycystic kidney disease by computed tomography. *Kidney Int*. 2000;58:2492-501.
- Fick-Brosnahan G, Johnson AM, Strain JD, Gabow PA. Renal asymmetry in children with autosomal dominant polycystic kidney disease. *Am J Kidney Dis*. 1999;34:639-45.
- Cadnapaphornchai MA, McFann K, Strain JD, Masoumi A, Schrier RW. Prospective change in renal volume and function in children with ADPKD. *Clin J Am Soc Nephrol*. 2009;4:820-9.
- Fick-Brosnahan GM, Tran ZV, Johnson AM, Strain JD, Gabow PA. Progression of autosomal-dominant polycystic kidney disease in children. *Kidney Int*. 2001;59:1654-62.
- Kistler AD, Poster D, Krauer F, et al. Increases in kidney volume in autosomal dominant polycystic kidney disease can be detected within 6 months. *Kidney Int*. 2009;75:235-41.
- Ettinger A, Kahn PC, Wise HM, Jr. The importance of selective renal angiography in the diagnosis of polycystic disease. *J Urol*. 1969;102:156-61.
- Jones DB. Arterial and glomerular lesions associated with severe hypertension. Light and electron microscopic studies. *Lab Invest*. 1974;31:303-13.
- Graham PC, Lindop GB. The anatomy of the renin-secreting cell in adult polycystic kidney disease. *Kidney Int*. 1988;33:1084-90.
- Torres VE, Donovan KA, Scicli G, et al. Synthesis of renin by tubulocystic epithelium in autosomal-dominant polycystic kidney disease. *Kidney Int*. 1992;42:364-73.
- Loghman-Adham M, Soto CE, Inagami T, Cassis L. The intrarenal renin-angiotensin system in autosomal dominant polycystic kidney disease. *Am J Physiol Renal Physiol*. 2004;287:F775-88.
- Bell PE, Hossack KF, Gabow PA, Durr JA, Johnson AM, Schrier RW. Hypertension in autosomal dominant polycystic kidney disease. *Kidney Int*. 1988;34:683-90.
- Chapman AB, Johnson A, Gabow PA, Schrier RW. The

- renin-angiotensin-aldosterone system and autosomal dominant polycystic kidney disease. *N Engl J Med.* 1990;323:1091-6.
28. Torres VE, Wilson DM, Burnett JC, Jr., Johnson CM, Offord KP. Effect of inhibition of converting enzyme on renal hemodynamics and sodium management in polycystic kidney disease. *Mayo Clin Proc.* 1991;66:1010-7.
 29. Watson ML, Macnicol AM, Allan PL, Wright AF. Effects of angiotensin converting enzyme inhibition in adult polycystic kidney disease. *Kidney Int.* 1992;41:206-10.
 30. Ecker T, Schrier RW. Cardiovascular abnormalities in autosomal-dominant polycystic kidney disease. *Nat Rev Nephrol.* 2009;5:221-8.
 31. Doulton TW, Saggari-Malik AK, He FJ, et al. The effect of sodium and angiotensin-converting enzyme inhibition on the classic circulating renin-angiotensin system in autosomal-dominant polycystic kidney disease patients. *J Hypertens.* 2006;24:939-45.
 32. Harrap SB, Davies DL, Macnicol AM, et al. Renal, cardiovascular and hormonal characteristics of young adults with autosomal dominant polycystic kidney disease. *Kidney Int.* 1991;40:501-8.
 33. Schrier RW. Renal volume, renin-angiotensin-aldosterone system, hypertension, and left ventricular hypertrophy in patients with autosomal dominant polycystic kidney disease. *J Am Soc Nephrol.* 2009;20:1888-93.
 34. Gabow PA. Autosomal dominant polycystic kidney disease—more than a renal disease. *Am J Kidney Dis.* 1990;16:403-13.
 35. Chapman AB, Schrier RW. Pathogenesis of hypertension in autosomal dominant polycystic kidney disease. *Semin Nephrol.* 1991;11:653-60.
 36. Schrier RW, McFann KK, Johnson AM. Epidemiological study of kidney survival in autosomal dominant polycystic kidney disease. *Kidney Int.* 2003;63:678-85.
 37. Ong AC, Harris PC. Molecular pathogenesis of ADPKD: the polycystin complex gets complex. *Kidney Int.* 2005;67:1234-47.
 38. Gabow PA, Johnson AM, Kaehny WD, et al. Factors affecting the progression of renal disease in autosomal-dominant polycystic kidney disease. *Kidney Int.* 1992;41:1311-9.
 39. Gabow PA, Chapman AB, Johnson AM, et al. Renal structure and hypertension in autosomal dominant polycystic kidney disease. *Kidney Int.* 1990;38:1177-80.
 40. Chapman AB. Cystic disease in women: clinical characteristics and medical management. *Adv Ren Replace Ther.* 2003;10:24-30.
 41. Seeman T, Sikut M, Konrad M, Vondrichova H, Janda J, Scharer K. Blood pressure and renal function in autosomal dominant polycystic kidney disease. *Pediatr Nephrol.* 1997;11:592-6.
 42. Fick GM, Johnson AM, Strain JD, et al. Characteristics of very early onset autosomal dominant polycystic kidney disease. *J Am Soc Nephrol.* 1993;3:1863-70.
 43. Chapman AB, Guay-Woodford LM, Grantham JJ, et al. Renal structure in early autosomal-dominant polycystic kidney disease (ADPKD): The Consortium for Radiologic Imaging Studies of Polycystic Kidney Disease (CRISP) cohort. *Kidney Int.* 2003;64:1035-45.
 44. Fick GM, Johnson AM, Hammond WS, Gabow PA. Causes of death in autosomal dominant polycystic kidney disease. *J Am Soc Nephrol.* 1995;5:2048-56.
 45. Koren MJ, Devereux RB, Casale PN, Savage DD, Laragh JH. Relation of left ventricular mass and geometry to morbidity and mortality in uncomplicated essential hypertension. *Ann Intern Med.* 1991;114:345-52.
 46. Ivy DD, Shaffer EM, Johnson AM, Kimberling WJ, Dobin A, Gabow PA. Cardiovascular abnormalities in children with autosomal dominant polycystic kidney disease. *J Am Soc Nephrol.* 1995;5:2032-6.
 47. Zeier M, Geberth S, Schmidt KG, Mandelbaum A, Ritz E. Elevated blood pressure profile and left ventricular mass in children and young adults with autosomal dominant polycystic kidney disease. *J Am Soc Nephrol.* 1993;3:1451-7.
 48. Bardaji A, Martinez-Vea A, Valero A, et al. Cardiac involvement in autosomal-dominant polycystic kidney disease: a hypertensive heart disease. *Clin Nephrol.* 2001;56:211-20.
 49. Cadnapaphornchai MA, McFann K, Strain JD, Masoumi A, Schrier RW. Increased left ventricular mass in children with autosomal dominant polycystic kidney disease and borderline hypertension. *Kidney Int.* 2008;74:1192-6.
 50. Chapman AB, Johnson AM, Rainguet S, Hossack K, Gabow P, Schrier RW. Left ventricular hypertrophy in autosomal dominant polycystic kidney disease. *J Am Soc Nephrol.* 1997;8:1292-7.
 51. Ecker T, Schrier RW. Hypertension in autosomal-dominant polycystic kidney disease: early occurrence and unique aspects. *J Am Soc Nephrol.* 2001;12:194-200.
 52. Verdecchia P, Schillaci G, Guerrieri M, et al. Circadian blood pressure changes and left ventricular hypertrophy in essential hypertension. *Circulation.* 1990;81:528-36.
 53. Fain PR, McFann KK, Taylor MR, et al. Modifier genes play a significant role in the phenotypic expression of PKD1. *Kidney Int.* 2005;67:1256-67.
 54. Klahr S, Breyer JA, Beck GJ, et al. Dietary protein restriction, blood pressure control, and the progression of polycystic kidney disease. Modification of Diet in Renal Disease Study Group. *J Am Soc Nephrol.* 1995;5:2037-47.
 55. Bae KT, Grantham JJ. Imaging for the prognosis of autosomal dominant polycystic kidney disease. *Nat Rev Nephrol.* 2010;6:96-106.
 56. Bajwa ZH, Sial KA, Malik AB, Steinman TI. Pain patterns in patients with polycystic kidney disease. *Kidney Int.* 2004;66:1561-9.
 57. Grampsas SA, Chandhoke PS, Fan J, et al. Anatomic and metabolic risk factors for nephrolithiasis in patients with autosomal dominant polycystic kidney disease. *Am J Kidney Dis.* 2000;36:53-7.
 58. Gabow PA, Duley I, Johnson AM. Clinical profiles of gross hematuria in autosomal dominant polycystic kidney disease. *Am J Kidney Dis.* 1992;20:140-3.
 59. Gabow PA. Autosomal dominant polycystic kidney disease. *N Engl J Med.* 1993;329:332-42.
 60. Milutinovic J, Fialkow PJ, Agodoa LY, Phillips LA, Rudd

- TG, Sutherland S. Clinical manifestations of autosomal dominant polycystic kidney disease in patients older than 50 years. *Am J Kidney Dis.* 1990;15:237-43.
61. Bajwa ZH, Gupta S, Warfield CA, Steinman TI. Pain management in polycystic kidney disease. *Kidney Int.* 2001;60:1631-44.
62. Taylor M, Johnson AM, Tison M, Fain P, Schrier RW. Earlier diagnosis of autosomal dominant polycystic kidney disease: importance of family history and implications for cardiovascular and renal complications. *Am J Kidney Dis.* 2005;46:415-23.
63. Elles RG, Hodgkinson KA, Mallick NP, et al. Diagnosis of adult polycystic kidney disease by genetic markers and ultrasonographic imaging in a voluntary family register. *J Med Genet.* 1994;31:115-20.
64. Grantham JJ. Clinical practice. Autosomal dominant polycystic kidney disease. *N Engl J Med.* 2008;359:1477-85.
65. Pei Y, Obaji J, Dupuis A, et al. Unified criteria for ultrasonographic diagnosis of ADPKD. *J Am Soc Nephrol.* 2009;20:205-12.
66. Reed B, Nobakht E, Dadgar S, et al. Renal ultrasonographic evaluation in children at risk of autosomal dominant polycystic kidney disease. *Am J Kidney Dis.* 2010;56:50-6.
67. O'Neill WC, Robbin ML, Bae KT, et al. Sonographic assessment of the severity and progression of autosomal dominant polycystic kidney disease: the Consortium of Renal Imaging Studies in Polycystic Kidney Disease (CRISP). *Am J Kidney Dis.* 2005;46:1058-64.
68. Sujansky E, Kreutzer SB, Johnson AM, Lezotte DC, Schrier RW, Gabow PA. Attitudes of at-risk and affected individuals regarding presymptomatic testing for autosomal dominant polycystic kidney disease. *Am J Med Genet.* 1990;35:510-5.
69. De Rycke M, Georgiou I, Sermon K, et al. PGD for autosomal dominant polycystic kidney disease type 1. *Mol Hum Reprod.* 2005;11:65-71.
70. Zhao X, Paterson AD, Zahirieh A, He N, Wang K, Pei Y. Molecular diagnostics in autosomal dominant polycystic kidney disease: utility and limitations. *Clin J Am Soc Nephrol.* 2008;3:146-52.
71. Rossetti S, Consugar MB, Chapman AB, et al. Comprehensive molecular diagnostics in autosomal dominant polycystic kidney disease. *J Am Soc Nephrol.* 2007;18:2143-60.
72. Garcia-Gonzalez MA, Jones JG, Allen SK, et al. Evaluating the clinical utility of a molecular genetic test for polycystic kidney disease. *Mol Genet Metab.* 2007;92:160-7.

Correspondence to:
Robert W Schrier, MD
Department of Medicine, University of Colorado Denver, Division of Renal Diseases and Hypertension
12700 East 19th Ave, Box C281, Research 2, Room 7001,
Aurora, CO 80045
USA
Tel: +1 303 724 4837
Fax: +1 303 724 4831
E-mail: robert.schrier@ucdenver.edu

Received July 2010