

# Unusual Presentation of Renal Tuberculosis

Aunp P Chaudhari, Ravi Ranganath, Malleshappa Pavan

Lilavati Hospital and Research Centre, Bandra West, Mumbai, India

**Keywords.** urogenital tuberculosis, kidney disease, latent tuberculosis

Urogenital tuberculosis (TB) is a common late manifestation of an earlier symptomatic or asymptomatic pulmonary TB infection. A latency period ranging from 5 to 40 years between the time of the initial infection and the expression of urogenital TB frequently occurs. As one of the most common sites of involvement of extrapulmonary TB, urogenital TB accounts for 15% to 20% of the infections. We present a patient who had culture-negative active tubercular kidney disease due to silent tuberculous infection. Our case demonstrates the limitations of noninvasive testing in establishing the diagnosis of renal tuberculosis.

IJKD 2011;5:207-9  
www.ijkd.org

## INTRODUCTION

Tuberculosis of the kidney and urinary tract is caused by members of the *Mycobacterium tuberculosis* complex. Tuberculosis is a common disease, with 8 to 10 million new cases annually and a rising incidence, particularly in regions with a high incidence of human immunodeficiency virus infection. Most often, the lung is affected, but the most common form of nonpulmonary tuberculosis is urogenital disease. The signs and symptoms of renal tuberculosis mimic those of other infections of the kidney, and diagnosing it is not very easy. Thus, diagnostic awareness may prevent unnecessary morbidity. Here, we report a case of progressive kidney disease due to silent tuberculous infection.

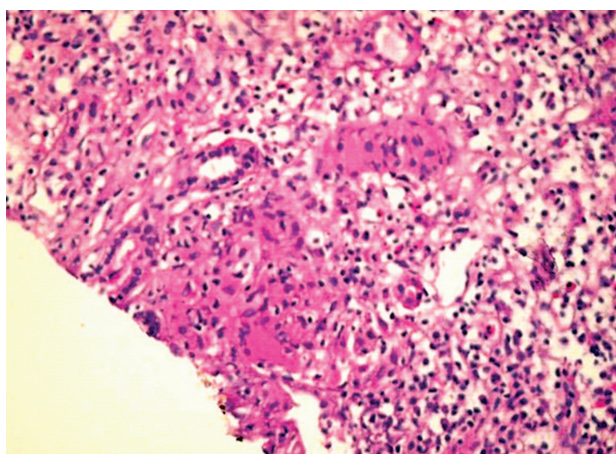
## CASE REPORT

A 28-year-old man was found to have a creatinine of 4.7 mg/dL on routine pre-employment health check. He had no facial puffiness, swelling of legs, hematuria, or dysuria. He denied any history of fever, joint pains, weight loss, or consumption of indigenous medicines. His past history was unremarkable. Physical examination was normal except for mild pallor. Laboratory data are depicted in The Table. Kidney biopsy was performed in view of unexplained azotemia. Kidney biopsy on light microscopy (Figure) revealed severe chronic

### Laboratory Studies\*

Laboratory Study	Result
CBC	
Hemoglobin, g/dL	9.4
Total leukocyte count, $\times 10^3/L$	7.2
Platelet count, $\times 10^3/L$	300
ESR, mm/h	8
Blood urea nitrogen, mg/dL	45
Serum creatinine, mg/dL	4.7
Urinalysis	
Reaction pH	Acidic
Proteins	Trace
Pus cells	Absent
Erythrocyte	Absent
Protein-creatinine ratio	0.3
Urine culture	Negative
Urine for AFB staining	Negative
Urine for AFB culture	Negative
Renal ultrasonography	Unremarkable
Plain radiography	Unremarkable
Chest radiography	Unremarkable
Anti-HIV antibody	Negative
HBs antigen	Negative
Anti-HCV antibody	Negative
ANA	Negative
Duble-stranded DNA	Negative
pANCA	Negative
cANCA	Negative
Complement 3	Normal
Complement 4	Normal

\*AFB indicates acid-fast bacilli; HIV, human immunodeficiency virus; HBs, hepatitis B surface; HCV, hepatitis C virus; ANA, antinuclear antibody; pANCA, perinuclear antineutrophil cytoplasmic antibody; and cANCA, cytoplasmic antineutrophil cytoplasmic antibody.



Kidney biopsy (light microscopy).

tubulointerstitial inflammation with tubular atrophy, thyroidisation, marked infiltration by lymphoplasmacytes, scattered medium sized noncaseating epithelioid cells with granulomas, and Langhans giant cells, with one of the granulomas showing caseous necrosis. The glomeruli were unremarkable.

Workup for caseating granulomatous interstitial nephritis revealed normal serum angiotensin-converting enzyme levels with normal serum calcium and Mantoux test and serum for polymerase chain reaction TB was negative. After ruling out all other causes of caseating granulomatous nephritis, and given that tuberculosis is prevalent in this part of the world, a provisional diagnosis of renal tuberculosis was made. The patient was started on antitubercular therapy with an initial 2-month intensive phase of treatment with rifampicin, isoniazid, pyrazinamide, and ethambutol followed by a 4-month continuation phase with rifampicin and isoniazid with dosages adjusted to creatinine clearance. Following the start of treatment, his serum creatinine started improving and settled at 2.0 mg/dL.

## DISCUSSION

Tuberculosis may involve the kidney as part of generalized disseminated infection or as a localized urogenital disease. Patients usually present with lower urinary symptoms typical of “conventional” bacterial cystitis, and suspicions of TB is aroused only when there is no response to the usual antibacterial agents or when urine examination reveals pyuria in the absence of a positive culture on routine media.<sup>1</sup> Other symptoms include back,

flank, and suprapubic pain; hematuria; frequency; and nocturia.

In the urogenital system, tubercle bacillus lodges in the glomerular and peritubular capillary bed by hematogenous seeding from the lungs or secondary spread may occur from TB of the urogenital tract or bone. Studies have shown that the natural history of renal tuberculosis starts with granulomatous lesions in the glomeruli during the primary infection, which often heal or rupture, into the interstitium or the tubules.<sup>2</sup> This rupture is a random event independent of any active tuberculosis elsewhere; it is rarely associated with systemic symptoms or pulmonary disease. The periodic rupture into the tubulo-interstitium can be associated with disease primarily in the interstitium without persistent pyuria, hematuria, or identifiable acid-fast bacilli in urine culture.<sup>3</sup> Consistent with this, our patient did not show any urinary findings or systemic signs of tuberculosis.

As in the primary site, granuloma formation, caseous necrosis, and cavitation within the renal parenchyma are the hallmark stages of progressive infection. The end-stage result is destruction, loss of function, fibrosis, and calcification in a lobular distribution of the entire kidney producing autonephrectomy.<sup>4</sup> Laboratory abnormalities commonly found on routine urinalysis are pyuria, proteinuria, and hematuria.<sup>5</sup> Simon and colleagues isolated *Mycobacterium tuberculosis* from the urine culture in 80% to 90% of clients with urogenital TB.<sup>6</sup> At least 3 serial urine cultures are considered the standard for evidence of active disease.<sup>7</sup> However, this approach failed to grow any acid-fast bacilli in our patient. Kidney biopsy clinched the diagnosis of caseating tubercular granuloma in our patient. There was a prompt response to anti-tubercular therapy, but our patient could not regain his complete kidney function, as there were changes of chronicity in the form of tubular atrophy in the kidney biopsy. Thus, we conclude that kidney biopsy should be used as a valuable tool in diagnosing culture-negative tubulo-interstitial nephropathy due to tuberculosis.

## CONFLICT OF INTEREST

None declared.

## REFERENCES

1. Eastwood JB, Corbishley CM, Grange JM. Tuberculosis

- and the kidney. *J Am Soc Nephrol.* 2001;12:1307-14.
2. Christensen WI. Genitourinary tuberculosis: review of 102 cases. *Medicine (Baltimore).* 1974;53:377-90.
  3. Lattimer JK, Reilly RJ, Segawa A. The significance of the isolated positive urine culture in genitourinary tuberculosis. *J Urol* 1969;102:610-3.
  4. Engin G, Acunas B, Acunas G, Tunaci M. Imaging of extrapulmonary tuberculosis. *Radiographics.* 2000;20:471-88.
  5. Gibson MS, Puckett ML, Shelly ME. Renal tuberculosis. *Radiographics.* 2004;24:251-6.
  6. Simon HB, Weinstein AJ, Pastermak MS, et al. Genitourinary tuberculosis. Clinical features in a general hospital population. *Am J Med.* 1977;63:410-20.
  7. [No author listed]. Diagnostic standards and classification of tuberculosis in adults and children. *Am J Respir Crit Care Med.* 2000;161:1376-95.

Correspondence to:  
Malleshappa Pavan, MD  
Department of Nephrology, A-791, Lilavati Hospital and  
Research Centre, Bandra Reclamation, Bandra West, Mumbai-  
400050, India  
Tel: +91 22 2655 2222, ext 8650  
Fax: +91 22 2640 7655  
E-mail: dr\_pavanm@yahoo.co.in

Received July 2010  
Revised December 2010  
Accepted January 2011