

Immunoglobulin G4-related Kidney Disease Associated With Autoimmune Hemolytic Anemia

Shen-Ju Gou, Shao-Bin Yu, Hong-Yu Qiu, Zhang-Xue Hu

Renal Division, Department of Medicine, West China Hospital of Sichuan University, Chengdu, China

Keywords. kidney dysfunction, IgG4-related disease, autoimmune hemolysis, anemia, storiform fibrosis

Awareness of the uncommon associated clinical manifestations of immunoglobulin G4 (IgG4)-related kidney disease is essential for the early diagnosis and effective treatment of patients. To the best of our knowledge, there have been few reports of patients with IgG4-related kidney disease associated with autoimmune hemolytic anemia. We here report a rare case of IgG4-related kidney disease associated with autoimmune hemolytic anemia. A 70-year-old man with kidney dysfunction and severe anemia had been diagnosed with chronic kidney disease and treated without any improvement. On admission, he had a high serum creatinine level, low hemoglobin level, positive direct Coombs test, and mild proteinuria. Serum IgG and IgG4 were elevated. Kidney biopsy showed marked infiltration of IgG4-positive plasma cells and storiform fibrosis in the interstitial compartment, which confirmed the diagnosis of IgG4-related kidney disease. Corticosteroid therapy was initiated, and subsequently, the kidney dysfunction and anemia dramatically improved.

IJKD 2018;12:243-6
www.ijkd.org

INTRODUCTION

Immunoglobulin G4-related kidney disease (IgG4-RKD) is a systemic disorder characterized by tumefactive lesions and histologic manifestations, such as tissue lymphoplasmacytic infiltration enriched with IgG4-positive plasma cells and storiform fibrosis.¹ The disease is often, but not always, associated with an elevated serum level of IgG4.^{2,3} Immunoglobulin G4-RKD is known to involve potentially every organ or system and affects approximately 15% of patients with IgG4-RKD.^{4,5} The number of reported cases of IgG4-RKD is increasing, but autoimmune hemolytic anemia (AIHA) is not commonly associated with IgG4-RKD. To the best of our knowledge, IgG4-RKD associated with AIHA has only been reported in 6 previous cases,⁶ and there are no reports of IgG4-RKD associated with AIHA. We report a case of IgG4-RKD associated with AIHA.

CASE REPORT

The patient was a 70-year-old man who first presented with fatigue and dizziness in 2015. He was admitted to a local hospital for kidney dysfunction and anemia. His serum creatinine level was 400 $\mu\text{mol/L}$. He was diagnosed with chronic kidney disease. The symptoms persisted, and the patient's serum creatinine level fluctuated between 200 $\mu\text{mol/L}$ and 400 $\mu\text{mol/L}$ during the follow-up period.

In August 2016, the patient suffered an exacerbation of his fatigue and dizziness and was admitted to our hospital. His physical examination was notable for facial pallor. His blood pressure was 106/62 mm Hg. No enlarged lymph nodes were palpable. The chest and abdominal examinations were within normal limits. No edema was observed. Routine hematology labs were as follows: hemoglobin, 7.6 g/dL; erythrocyte

count, $2.17 \times 10^{12}/L$; reticulocyte count, $0.1285 \times 10^{12}/L$; leukocyte count, $12.26 \times 10^9/L$; and platelet count, $144 \times 10^9/L$. Urinalysis was positive for 1+ proteinuria, and urinary protein level was 1.93 g/24 h. Fecal occult blood testing was negative. Blood biochemistry analysis revealed the following: albumin, 28.3 g/L; globulin, 45.1 g/L; alanine aminotransferase, 19 U/L; total bilirubin, 9.5 $\mu\text{mol}/L$; blood urea nitrogen, 21.96 mmol/L; serum creatinine, 625 $\mu\text{mol}/L$; uric acid, 623 $\mu\text{mol}/L$; and ferritin, > 2000 ng/mL. Clinical immunology tests revealed the following: anti-nuclear antibody, +1:100; anti-neutrophil cytoplasmic antibodies, negative; rheumatoid factor, 408 IU/mL; IgG, 32.2 g/L; IgG4, 4.47g/L (reference range, 0.04 g/L to 1.5 g/L), C3 complement, 0.4790 g/L; C4 complement, 0.0814 g/L; and C-reactive protein, 26.9 mg/L. The direct Coombs test was positive. The tests of viral and bacterial markers revealed negative for hepatitis B, hepatitis C, human immunodeficiency virus, and syphilis. A serum immunofixation electrophoresis did not reveal abnormal pattern in M protein. Renal ultrasonography showed that the size of the right kidney was $93 \times 54 \times 59$ mm, whereas the left one measured $98 \times 50 \times 57$ mm.

A kidney biopsy was performed in this patient. Light microscopy demonstrated global sclerosis in all 17 glomeruli, severe interstitial fibrosis, and tubular atrophy. In the fibrotic interstitial compartment, collagen fibers exhibited a storiform pattern, and inflammatory cells infiltrated the collagen fibers. The infiltrating inflammatory cells predominantly consisted of plasma cells, lymphocytes, and monocytes. Immunofluorescence testing was negative for IgG, IgA, IgM, C3, C4, and C1q in glomeruli. Immunohistochemistry revealed more than 10 IgG4-positive plasma cells per high-power field (Figure 1). On this basis, the

patient was diagnosed with IgG4-RKD.

The patient was treated with prednisone, 1 mg/kg daily. One and a half month later, the serum creatinine level dropped from 625 $\mu\text{mol}/L$ to 205 $\mu\text{mol}/L$, and the serum IgG4 level dropped from 4.47 g/L to 1.20 g/L. The hemoglobin increased from 7.6 g/dL to 91 g/L. The symptoms of fatigue and dizziness resolved. Prednisone was tapered to 20 mg/d after 3 months, at which time the serum IgG4 was 0.465 g/L, creatinine was 176 $\mu\text{mol}/L$, and hemoglobin was 11.1 g/dL (Figure 2).

DISCUSSION

Immunoglobulin gG4-RKD is a newly recognized fibroinflammatory condition that can potentially involve any organ in the body, either synchronously or metachronously. Histologically, IgG4-RKD is characterized by IgG4-positive plasma cell infiltration and storiform fibrosis, and serum IgG4 concentrations are often elevated. Because clinical symptoms and pathological features depend on the location of lesions, detailed diagnostic criteria vary by affected organ. The diagnostic criteria for IgG4-RKD introduced by Takao Saito indicate that IgG4-RKD can be diagnosed when at least 3 of the following 5 criteria are satisfied: kidney disease, abnormal radiologic findings, elevated serum IgG4 level (> 135 mg/dL), histologic findings in the kidney and histologic findings of extra-renal organs.⁷ Our patient presented with elevated serum creatinine and IgG4, dense lymphoplasmacytic infiltration with infiltrating IgG4-positive plasma cells, and characteristic fibrosis surrounding nests of lymphocytes and plasma cells. Therefore, the patient met diagnostic criteria for IgG4-RKD.

In this case, it is interesting that the patient suffered from severe anemia in addition to the kidney disease. He was diagnosed with AIHA based

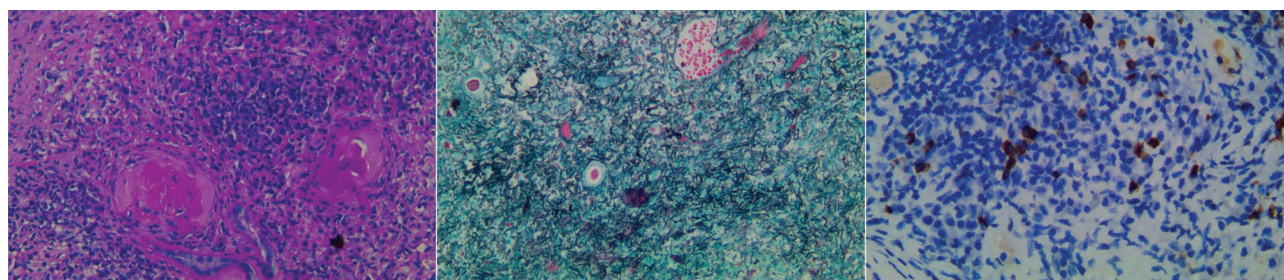


Figure 1. The histopathological and immunohistochemical findings of the renal specimen. Left, Fibrotic lesions and inflammatory cells infiltration in the interstitial compartment (hematoxylin-eosin, $\times 200$). Middle, Storiform fibrosis in the interstitial compartment (periodic acid-silver methenamine, $\times 200$). Right, Immunoglobulin G4-positive plasma cells infiltration in the interstitial compartment (immunohistochemistry, $\times 400$).

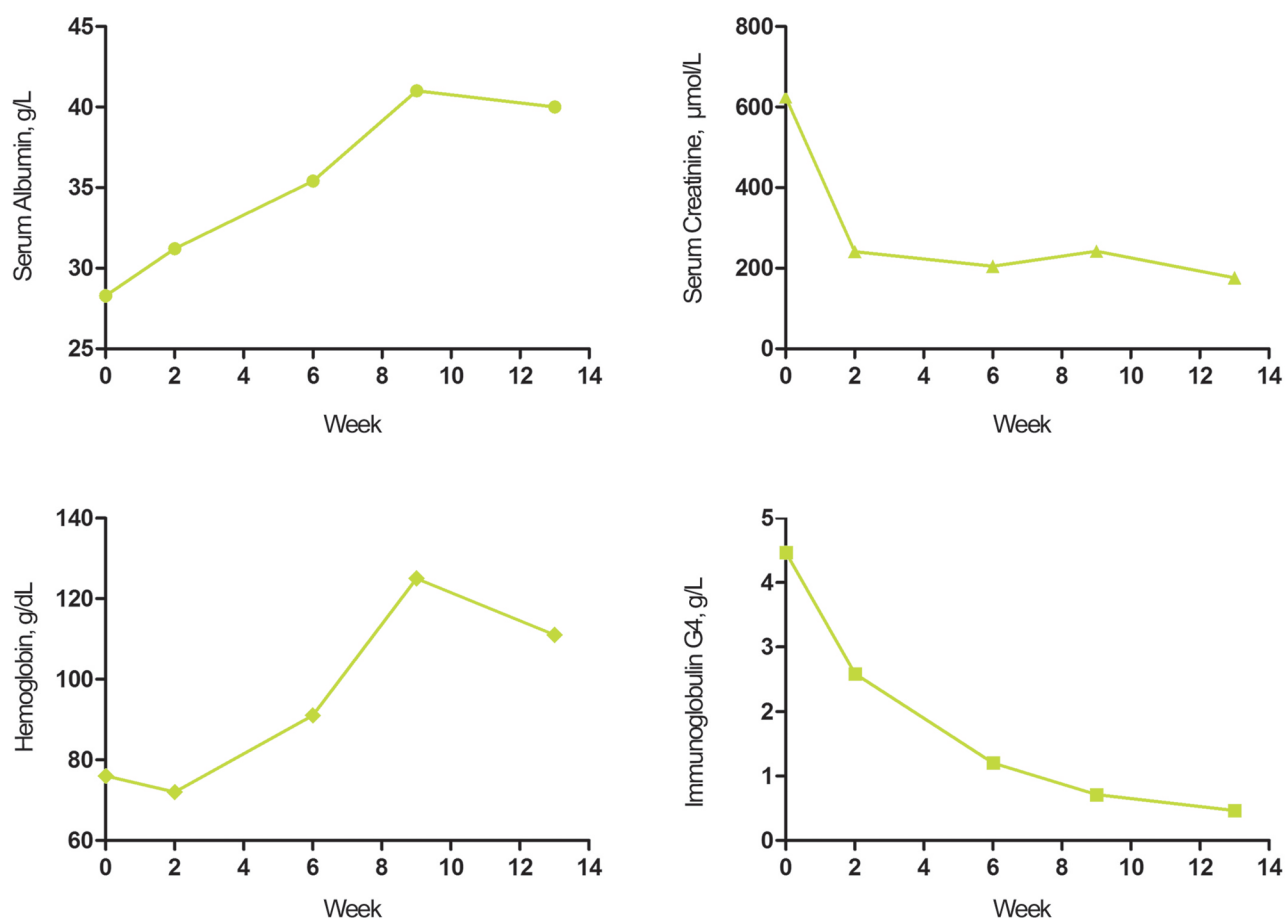


Figure 2. The clinical course of the patient after corticosteroid treatment was initiated.

on a positive direct Coombs test, reticulocytosis, and severe anemia, which was significantly improved when the corticosteroids were administered. To the best of our knowledge, there have only been 6 reported cases of IgG4-RKD associated with AIHA.⁶ Of those 6 cases, the IgG4-RKD manifested as autoimmune pancreatitis (2 cases), sclerosing cholangitis, retroperitoneal fibrosis, lung disease, and IgG4-RKD with liver, lymph node, and salivary glands involvement. Only 1 patient experienced acute kidney injury caused by hypercalcemia and recovered quickly. No cases of AIHA have been reported in associated with IgG4-RKD to date. This case is the first report of IgG4-RKD associated with AIHA.

Autoimmune hemolytic anemia is an autoimmune disease that causes hemolysis due to anti-erythrocyte autoantibodies with or without complement activation.⁸ Immunoglobulin G is the most common type of autoantibody against erythrocytes in AIHA. The IgG subclasses involved in the pathogenesis of

AIHA are predominantly IgG1 with contribution from IgG3, whereas IgG2 and IgG4 are generally not involved. On the other hand, IgG1 and IgG3 can shorten the half-life of erythrocytes more drastically than IgG2 and IgG4, and IgG1 and IgG3 are able to activate the complement cascade, whereas IgG4 reportedly lacks this ability.⁹⁻¹² The binding ability of IgG4 to Fc γ receptor expressed by tissue macrophages is also weak, which reduces the clearance of IgG-coated erythrocytes in the spleen mediated by phagocytosis. Another unique feature of IgG4 is "Fab-arm exchange," a process in which a pair of heavy and light chains of an IgG4 antibody are exchanged with those derived from another IgG4 antibody. Due to this structural change, IgG4 molecules become asymmetric and eventually lose their antigen cross-linking ability, behave as monovalent antibodies, and become incapable of forming large immune complexes.¹³ These results suggest that IgG4 might not contribute to the development of AIHA. However, more than

half of the cases of IgG4-RKD were associated with hypocomplementemia.⁷ Membranous nephropathy can overlap with IgG4-RKD. It is well known that primary membranous nephropathy is manifested by IgG4 and C3 granular deposits along glomerular capillaries. This suggests that there is a relationship between IgG4 and complement in IgG4-RKD. The Fab-arm exchange may reduce the ability to form large immune complexes, which accounts for approximately 50% of IgG4 molecules.¹⁴ However, the extent of Fab-arm exchange in patients with elevated serum IgG4 is unclear. It is possible that a high percentage of IgG4 antibodies retain monospecificity and potential to bind antigens and contribute to destructive inflammation.¹ The patient in our case as well as the six other reported cases of patients with IgG4-RKD and AIHA,⁶ showed good responses to corticosteroid therapy. Five of the seven patients showed isochronous onset and improvement of AIHA and IgG4-RKD, which supports the idea that AIHA is a hematologic manifestation of IgG4-RKD. However, further studies are needed to elucidate the relationship between IgG4-RKD and AIHA.

In conclusion, the present case is the first case report of IgG4-RKD associated with AIHA. This case suggests that patients with IgG4-RKD may present with severe AIHA. The significance of the relationship between IgG4-RKD and AIHA needs further study.

CONFLICT OF INTEREST

None declared.

REFERENCES

1. Stone JH, Zen Y, Deshpande V. IgG4-related disease. *N Engl J Med*. 2012;366:539-51.
2. Hamano H, Kawa S, Horiuchi A, et al. High serum IgG4 concentrations in patients with sclerosing pancreatitis. *N Engl J Med*. 2001;344:732-8.
3. Wallace ZS, Deshpande V, Mattoo H, et al. IgG4-Related Disease: Clinical and Laboratory Features in One Hundred Twenty-Five Patients. *Arthritis Rheumatol*. 2015;67:2466-75.

4. Cortazar FB, Stone JH. IgG4-related disease and the kidney. *Nat Rev Nephrol*. 2015;11:599-609.
5. Saeki T, Nishi S, Imai N, et al. Clinicopathological characteristics of patients with IgG4-related tubulointerstitial nephritis. *Kidney Int*. 2010;78:1016-23.
6. Noguchi S, Yatera K, Jinbo M, et al. IgG4-related Lung Disease Associated with Autoimmune Hemolytic Anemia: A Case Report and a Literature Review. *Intern Med*. 2016;55:2469-74.
7. Kawano M, Saeki T, Nakashima H, et al. Proposal for diagnostic criteria for IgG4-related kidney disease. *Clin Exp Nephrol*. 2011;15:615-26.
8. Barcellini W. New Insights in the Pathogenesis of Autoimmune Hemolytic Anemia. *Transfus Med Hemother*. 2015;42:287-93.
9. Masutani H, Okuwaki K, Kida M, et al. First case of IgG4-related sclerosing cholangitis associated with autoimmune hemolytic anemia. *World J Gastroenterol*. 2014;20:8740-4.
10. von dBAE, Beckers D, van der Meulen FW, Engelfriet CP. IgG4 autoantibodies against erythrocytes, without increased haemolysis: a case report. *Br J Haematol*. 1977;37:137-44.
11. Engelfriet CP, Borne AE, Beckers D, Van Loghem JJ. Autoimmune haemolytic anaemia: serological and immunochemical characteristics of the autoantibodies; mechanisms of cell destruction. *Ser Haematol*. 1974;7:328-47.
12. Komine M. [Autoimmune hemolytic anemia]. *Rinsho Ketsueki*. 1992;33:897-901.
13. Zen Y, Kawakami H, Kim JH. IgG4-related sclerosing cholangitis: all we need to know. *J Gastroenterol*. 2016;51:295-312.
14. He Y, Du X, Ding N, et al. Spectrum of IgG4-related disease on multi-detector CT: a 5-year study of a single medical center data. *Abdom Imaging*. 2015;40:3104-16.

Correspondence to:

Zhang-Xue Hu, PhD

Renal Division, Department of Medicine, West China Hospital of Sichuan University, Chengdu 610041, China

Tel: +86 28 8542 3341

Fax: +86 28 8542 3341

E-mail: hzxawy@scu.edu.cn

Shen-Ju Gou and Shao-Bin Yu contributed equally to this paper as first authors.

Received October 2017

Revised December 2017

Accepted December 2017