

# Five Patients With Emphysematous Pyelonephritis

Indu Bhushan Dubey, Vivek Agrawal, Bhupendra Kumar Jain

GTB Hospital & University  
College of Medical Sciences,  
Delhi, India

**Keywords.** emphysema,  
pyelonephritis, nephrectomy,  
computed tomography

Emphysematous pyelonephritis is an acute necrotizing infection of the renal parenchyma, resulting in presence of gas within either in the collecting system or perinephric space. We herein report our experience with 5 cases of emphysematous pyelonephritis in 2 men and 3 women managed by broad spectrum antibiotics, supportive measures including hemodialysis (2 patients), ureteral stenting (2 patients), surgical drainage of perinephric collection (1 patient), and control of diabetes mellitus (4 patients). Four patients were discharged after a mean hospital stay of 18 days. A nondiabetic male patient with a nonobstructed kidney died on the second postoperative day due to persistent septicemia despite nephrectomy. Emphysematous pyelonephritis is a potentially fatal disease requiring careful and prompt diagnosis, and individualized rational therapy. Ureteropelvic stenting should be used for drainage of pent-up collections as a lifesaving measure through relieving the obstruction. Perinephric fluid collection should be drained either percutaneously or surgically.

IJKD 2011;5:204-6  
www.ijkd.org

## INTRODUCTION

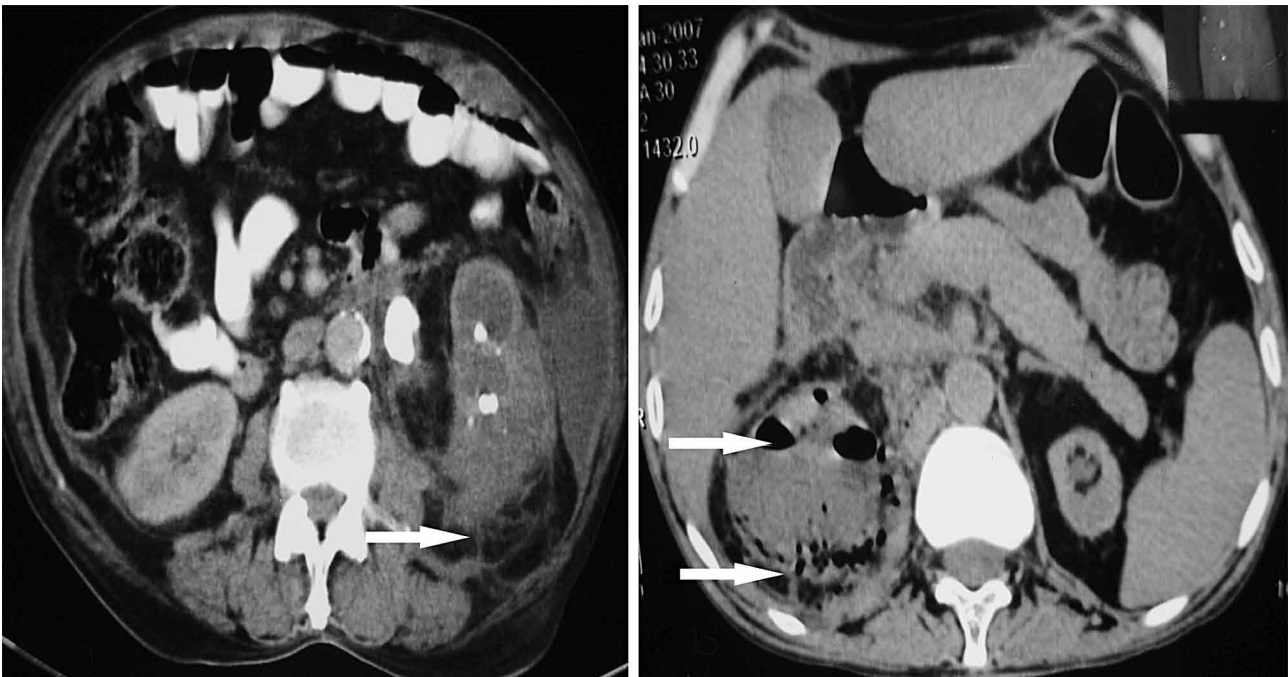
Emphysematous pyelonephritis (EP) is acute necrotizing infection of the renal parenchyma resulting in presence of gas either in the collecting system or perinephric space.<sup>1</sup> Although the presentation is often similar to uncomplicated pyelonephritis, the clinical course can be catastrophic with up to 90% mortality.<sup>2</sup> Resuscitation, broad spectrum antibiotics, percutaneous or surgical drainage, and emergent or delayed nephrectomy are essential constituents of management of EP.<sup>3</sup> We herein report our experience with 5 cases of emphysematous pyelonephritis in 2 men and 3 women managed by broad spectrum antibiotics, supportive measures including hemodialysis, ureteral stenting, surgical drainage of perinephric collection, and control of diabetes mellitus.

## CASE REPORT

Over a period of 3 years, 3 women and 2 men (4 diabetic, 1 nondiabetic) aged 28 to 73 years (mean, 51 years) presented with symptoms of acute renal

infection for which diagnosis of EP was suggested by ultrasonography and subsequently confirmed by computed tomography (CT) scan (Figure). The Table summarizes the clinical features of the 5 patients. Obstruction of the corresponding reno-ureteral unit was observed in 4 patients (multiple calyceal calculi in 2 and ureteral calculus and purulent debris each in 1). The affected kidney was palpable in patient 2. Altered mental status and ketoacidosis was a presenting feature in patient 2 who was also diabetic. Patient 5 presented with shock and anuria and died subsequently. Leukocytosis and deranged kidney function were observed in all of the patients. *Escherichia coli* was cultured from urine of all of the patients, and in patient 5, *Klebsiella pneumoniae* was also present.

All of the patients were treated with ceftriaxone, which was changed as per sensitivity to carbapenam antibiotics, where required. Diabetes mellitus was controlled with injectable insulin. Ureteral obstruction was relieved by placement of a double-J stent in patients 2 and 4. Hemodialysis was required



Computed tomography scan showed presence of gas in the renal and pararenal space (marked by arrow).

#### Demographic and Clinical Characteristics of Patients and Outcomes

Patient	Age, y	Gender	Disease		Other Features	Intervention	Outcome	Kidney Function, %*
			Side	Class <sup>4</sup>				
1	73	Male	Left	3B	Kidney calculus, hydronephrosis, perinephric collection, diabetes mellitus	Antibiotics, control of diabetes, drainage of abscess	Recovered	17
2	54	Female	Left	2	Ureteral calculus, hydronephrosis, diabetes mellitus	Antibiotics, control of diabetes, hemodialysis, ureteral stenting	Recovered	30
3	28	Female	Right	1	Kidney calculus, hydronephrosis, diabetes mellitus	Antibiotics, control of diabetes	Recovered	24
4.	45	Female	Right	3B	Ureteral obstruction by purulent debris, hydronephrosis, diabetes mellitus	Antibiotics, control of diabetes, ureteral stenting	Recovered	29
5	55	Male	Right	3B	...	Antibiotics, hemodialysis, nephrectomy	Died	...

\*Differential kidney function of the affected kidney after 3 months

to manage uremia in patients 2 and 5. Perinephric collection was drained surgically in patient 1. Patient 5 showed no improvement despite broad spectrum antibiotics, hemodialysis, and other supportive measures, and underwent right nephrectomy 48 hours after admission. Yet the patient continued to deteriorate and died on the 2nd postoperative day, because of continued sepsis-induced refractory shock and disseminated intravascular coagulopathy. The other 4 patients showed improvement on medical management and were discharged after a mean hospital stay of 18 days.

#### DISCUSSION

Emphysematous pyelonephritis was first described in 1898 as an acute perirenal necrotizing infection that is produced by gas forming uropathogens.<sup>5</sup> It is usually encountered in patients with diabetes mellitus, obstructive uropathy, or immune system incompetence.<sup>6</sup> *Escherichia coli* is the most common pathological agent incriminated in 69% to 90% of the cases.<sup>1</sup> Diagnosis of EP is difficult clinically and is usually established by imaging. Plain radiography of the kidney, ureters, and bladder may show mottling by gas in the

renal and perirenal spaces in one-third of the patients.<sup>7</sup> Ultrasonography of the abdomen can demonstrate gas, fluid collections, and urinary tract obstruction, and may be helpful in guiding the placement of percutaneous drainage catheter if a collection is seen.<sup>8</sup> Currently, the most useful tool in assessing the extent of disease and monitoring the therapeutic response is the CT.<sup>9</sup> Huang and colleagues<sup>4</sup> proposed 4 classes of EP based on CT to prognosticate the disease: class 1, gas presence in collecting system only (emphysematous pyelitis); class 2, gas presence in renal parenchyma without extension to extrarenal area; class 3A, gas and/or abscess presence in perinephric space; class 3B, gas or abscess in pararenal area; class 4, bilateral EP of any class or EP in solitary kidney.

Initial management of EP consists of fluid resuscitation, glycemic control, and broad spectrum antibiotics. Adequate urinary drainage with relief of obstruction is essential.<sup>10</sup> Hemodialysis may be lifesaving adjuvant therapy while awaiting normalization of kidney function.<sup>9,11</sup> Presence of gas in the renal parenchyma does not necessarily dictate nephrectomy, since remarkable recovery of function in the affected kidney has been reported,<sup>9</sup> as in our patients 1 to 4. In the absence of obstruction, favorable response to antimicrobial therapy is more likely and can be confirmed by disappearance of gas collections on CT scan.<sup>8</sup> Considering high mortality with medical therapy, many authors have advocated aggressive medical and interventionist approach.<sup>12</sup> However, several authors reported a positive outcome with conservative management of this disease.<sup>9,13-16</sup>

To conclude, EP requires early diagnosis for which a high index of suspicion is essential. Urgent diagnostic measures, including ultrasonography and CT, are essential. Therapy must ensure control of infection by appropriate antibiotics, glycemic control, drainage of perinephric collection, relief of ureteric obstruction, intensive monitoring, and nephrectomy, wherever necessary.

#### CONFLICT OF INTEREST

None declared.

#### REFERENCES

1. Weinrob AC, Sexton DJ. Urinary tract infections in patients with diabetes mellitus. In: Rose BD, editor. UpToDate.

Wellesley: 2007;15(3). [CD-ROM].

2. Tsitouridis I, Michaelides M, Sidiropoulos D, Arvanity M. Renal emphysema in diabetic patients: CT evaluation. *Diagn Interv Radiol.* 2010;16:221-6.
3. Darabi M, Keshvari M. Bilateral emphysematous pyelonephritis: a case report. *Urol J.* 2005; 2:118-119.
4. Huang JJ, Tseng CC. Emphysematous pyelonephritis: clinico-radiologic classification, management, prognosis, and pathogenesis. *Arch Intern Med.* 2000;160:797-805.
5. Kelly HA, MacCullum WG. Pneumaturia. *JAMA.* 1898;31:375-81.
6. Abdul-Halim H, Kehinde EO, Abdeen S, et al. Severe emphysematous pyelonephritis in diabetic patients: diagnosis and aspects of surgical management. *Urol Int.* 2005;75:123-8.
7. Yao J, Gutierrez OM, Reiser J. Emphysematous pyelonephritis. *Kidney Int.* 2007;71:562-5.
8. Hudson MA, Weyman PJ, van der Vliet AH, Catalona WJ. Emphysematous pyelonephritis: successful management by percutaneous drainage. *J Urol* 1986;136:884-6.
9. DePauw AP, Ross G Jr. Emphysematous pyelonephritis in a solitary kidney. *J Urol.* 1981;125:734.
10. Schaeffer AJ. Infections of the urinary tract. In: Walsh PC, Retik AB, Vaughan ED Jr, et al, editors. *Campbell's urology.* 8th ed. Philadelphia: WB Saunders; 2002. p. 573-4.
11. Neviackasa, JA, Bauer JH. Emphysematous pyelonephritis a report of two cases. *Mod. Med.* 1981;78:196.
12. Mohsin N, Badruddin M, Lala S, Al-Taie S. Emphysematous pyelonephritis. a case report series of four patients with review of literature. *Ren Fail.* 2009;31:597-601.
13. Pontine AR, Barnes RD, Joffe J, et al. Emphysematous pyelonephritis in diabetic patients. *Br J Urol.* 1995; 75: 71-74.
14. Chan PH, Kho VK, Lai SK, et al. Treatment of emphysematous pyelonephritis with broad spectrum antibacterials and percutaneous renal drainage: An analysis of 10 patients. *J Chin Med Assoc.* 2005;68:29-32.
15. Mallet M, Knockaert DC, Oyen RH, et al. Emphysematous pyelonephritis: No longer a surgical disease. *Eur J Emerg Med.* 2002;9:266-9.
16. Fujita S, Watanabe J, Reed AI, et al. Case of emphysematous pyelonephritis in renal allograft. *Clin Transplant.* 2005;19:559-62.

Correspondence to:

Indu Bhushan Dubey, MS

GTB Hospital & University College of Medical Sciences, Delhi, India

E-mail: dribdubey@gmail.com

Received April 2010

Revised August 2010

Accepted December 2010