

Protection Against Doxorubicin-induced Nephropathy by *Plantago major* in Rat

Zohreh Naji Ebrahimi Yazd,¹ Sara Hosseinian,¹
 Mohammad Naser Shafei,^{1,2} Alireza Ebrahimzadeh Bideskan,³
 Nazanin Entezari Heravi,¹ Soghra Parhizgar,¹ Samira Shahraki,¹
 Zahra Samadi Noshahr,¹ Somayeh Mahzari,¹ Abolfazl Khajavi Rad^{1,4}

¹Department of Physiology, School of Medicine, Mashhad University of Medical Sciences, Mashhad, Iran

²Neurocognitive Research Center, Mashhad University of Medical Sciences, Mashhad, Iran

³Department of Anatomy and Cell Biology, School of Medicine, Mashhad University of Medical Sciences, Mashhad, Iran

⁴Neurogenic Inflammation Research Center, Mashhad University of Medical Sciences, Mashhad, Iran

Keywords. *Plantago major*, doxorubicin, vitamin E, dexamethasone, nephropathy, animal study

Introduction. Nephropathy is an important side effect of doxorubicin. The aim of the current study was to investigate the protective effect of *Plantago major* extract against doxorubicin-induced functional and histological damage in rat's kidney.

Materials and Methods. Sixty Albino rats were randomly divided into 6 groups. Doxorubicin, 5 mg/kg, was injected intravenously on the 7th day of the study. Animals were treated with dexamethasone, 0.9 mg/kg, vitamin E, 100 mg/kg, and *P major* extract, 600 mg/kg and 1200 mg/kg, for 7 days before and 4 weeks after doxorubicin administration. Glomerular filtration rate, urea clearance, and urine glucose concentration were determined on the 1st day and 1, 2, 3 and 4 weeks after doxorubicin injection. Histological changes were also examined and the end of the study.

Results. Doxorubicin caused significant decreases in glomerular filtration rate and urea clearance and significant glycosuria and kidney damage. Urea clearance in the rats treated with *P major* showed no significant change between different days of the experiment. Administration of dexamethasone, vitamin E, and low- and high-dose *P major* significantly improved the glycosuria and kidney tissue damage.

Conclusions. These findings suggested that hydroalcoholic extract of *P major* protected renal tissue against doxorubicin-induced nephropathy. The protective effects of *P major* on renal lesions associated with doxorubicin may be due to its antioxidant and anti-inflammatory actions.

IJKD 2018;12:99-106
www.ijkd.org

INTRODUCTION

Doxorubicin is an anthracycline antibiotic that is used for the treatment of a wide range of malignancies including breast cancer, lymphoma, small cell lung carcinoma, and acute leukemia.¹ In spite of its high antitumor efficacy, the clinical use of doxorubicin has been restricted due to its major side effects mainly cardiotoxicity and nephrotic syndrome, characterized by severe proteinuria, hypoalbuminaemia, hyperlipidemia, and edema.

Doxorubicin-induced nephropathy is due to toxic destruction of glomerulus and tubulointerstitial damage.²

The mechanisms involved in doxorubicin-induced nephropathy are complex and may include oxidative stress, inflammation, apoptosis, and fibrosis. Recent studies have shown that an increase in free radical generation, lipid peroxidation, and reduction in antioxidant enzymes activity are principal mediators in the development of nephrotic syndrome.³ In

addition, inflammation has also a major role in the kidney injury induced by doxorubicin and is due to the local production of cytokines and other chemotactic factors.² Furthermore, doxorubicin exerts direct toxic damage to the glomerular structure leading to proteinuria. In this regard, the use of antioxidant and anti-inflammatory agents can effectively improve the renal complications created by doxorubicin.

Plantago major (*P major*) is a flowering plant that belongs to the *Plantaginaceae* family. *Plantago major* contains many effective components including glycosides, flavonoids, lipids, polysaccharides, and terpenoids.⁴ In traditional medicine, *P major* has been used for the treatment of fever, bronchitis, hypertension, and asthma.⁴ In various investigations, *P major* exhibits many pharmacologic effects including antioxidant, anti-inflammatory, analgesic, antimicrobial, and immunomodulatory actions.⁵⁻⁸ Parhizgar and colleagues reported that oral administration of *P major* extract protected against oxidative stress and kidney dysfunction induced by cisplatin in rats.⁵ The aim of this study was to investigate the effect of hydroalcoholic extract of *P major* on doxorubicin-induced kidney damage in rats.

MATERIALS AND METHODS

Extract Preparation

Plantago major whole plant was collected from the nature around Mashhad and was identified by a botanist from the Herbarium of Ferdowsi University of Mashhad (Mashhad, Iran). The plant was powdered and was extracted using an extractor with ethanol (70%). The resulting solution was purified using a rotary evaporator and kept at 4°C until use.

Chemicals

Doxorubicin was purchased from Ebewe Pharma (Austria). Vitamin E powder and dexamethasone were obtained from Osve (Iran). Serum levels of creatinine, urea, and glucose were measured using kits from Pars Azmoon (Iran).

Animals

Sixty male Albino Wistar rats (250 g to 270 g) were obtained from the Animal House of the School of Medicine, Mashhad University of Medical Sciences, Mashhad, Iran. The animals were housed

at room temperature ($25 \pm 1^\circ\text{C}$) on a regular 12-hour light-dark cycle with free access to food and water ad libitum. All experiments were approved by the ethics committee of Mashhad University of Medical Sciences.

Experimental Protocol

The animals were randomly divided into 6 groups of 10 each as follows: control group, rats that received normal saline via intravenous tail injection on the 7th day of experiment; doxorubicin group, rats received doxorubicin, 5 mg/kg, intravenous, on the 7th day of experiment; dexamethasone-doxorubicin group, rats received dexamethasone, 0.9 mg/kg, intraperitoneal, 6 consecutive days before injection of doxorubicin, and 2 weeks after that for every other day; vitamin E-doxorubicin group, rats received vitamin E powder, 100 mg/kg, in drinking water, for 5 consecutive weeks and injection of doxorubicin on the 7th day of experiment, *P major* 600 group, rats was received *P major* extract, 600 mg/kg, in drinking water, for 5 consecutive weeks, and injection of doxorubicin on the 7th day of experiment; and *P major* 1200 group, rats received *P major* extract, 1200 mg/kg, in drinking water, for 5 consecutive weeks, and injection of doxorubicin on the 7th day of experiment.

Sample Collection and Measured Parameters

Urine samples using individual metabolic cages and blood samples from the orbital sinus were collected on the 1st day and 1, 2, 3, and 4 weeks (days 14, 21, 28, and 35) after doxorubicin injection. Blood samples were centrifuged at 3000 g for 15 minutes, and serum was stored at -20°C until use. Four weeks after doxorubicin injection, the rats were anaesthetized with ether and the right kidneys were quickly removed. Then, all animals were humanely killed. Serum and urine concentrations of urea and creatinine and urine glucose concentration were measured by Convergys 100 Biochemistry Analyser using commercial kits (Pars Azmoon, Iran). Creatinine clearance for estimation of glomerular filtration rate (GFR) as well as urea clearance were calculated using the following formula:

$$\text{Creatinine clearance (mL/min)} = \frac{\text{urine creatinine (mg/dL)} \times \text{urine output (mL/min)}}{\text{plasma creatinine (mg/dL)}}$$

Histopathological Examination

The right kidneys were fixed in 10% formalin, then dehydrated in graded alcohols and embedded in paraffin. Sections of 5 μm were prepared and staining was carried out with hematoxylin-eosin. The renal sections were examined in a light microscopy for glomerular and tubulointerstitial injury.

Statistical Analysis

All data were expressed as mean ± standard error of mean. Between-group comparison was estimated using the 1-way analysis of variance, followed by the LSD post hoc test. Intragroup comparisons were analyzed using repeated measures. Differences were considered significant when the *P* value was less than .05.

RESULTS

Kidney Function

In the control group, there was no significant change in GFR, urea clearance, and urine glucose concentration between different days of the study. However, compared to day 1, GFR showed a

significant reduction on days 28 and 35 in the doxorubicin group ($P < .01$ and $P < .05$, respectively) and urea clearance showed a significant decrease on days 21 and 28 ($P < .01$ and $P < .05$, respectively; Figures 1 and 2). Compared to day 1, urine concentration of glucose significantly increased on days 21, 28, and 35 in the doxorubicin group (Figure 3).

In the dexamethasone-doxorubicin group, GFR significantly decreased on the days 28 and 35 compared with day 1 ($P < .01$; Figure 1). In this group, urea clearance showed a significant reduction on day 35 compared to day 1 ($P < .05$; Figure 2). However, urine glucose concentration demonstrated no significant alteration between different days of the experiment (Figure 3). In the vitamin E-doxorubicin group, urea clearance showed a significant increase on the day 14 and a significant decrease on day 35 of the study compared with day 1 ($P < .05$; Figure 2). Nevertheless, no significant difference was seen in GFR and urine level of glucose between different days of the study (Figure 1 and 3). Treatment of the doxorubicin-injected rats with *P major* extract (600 mg/kg)

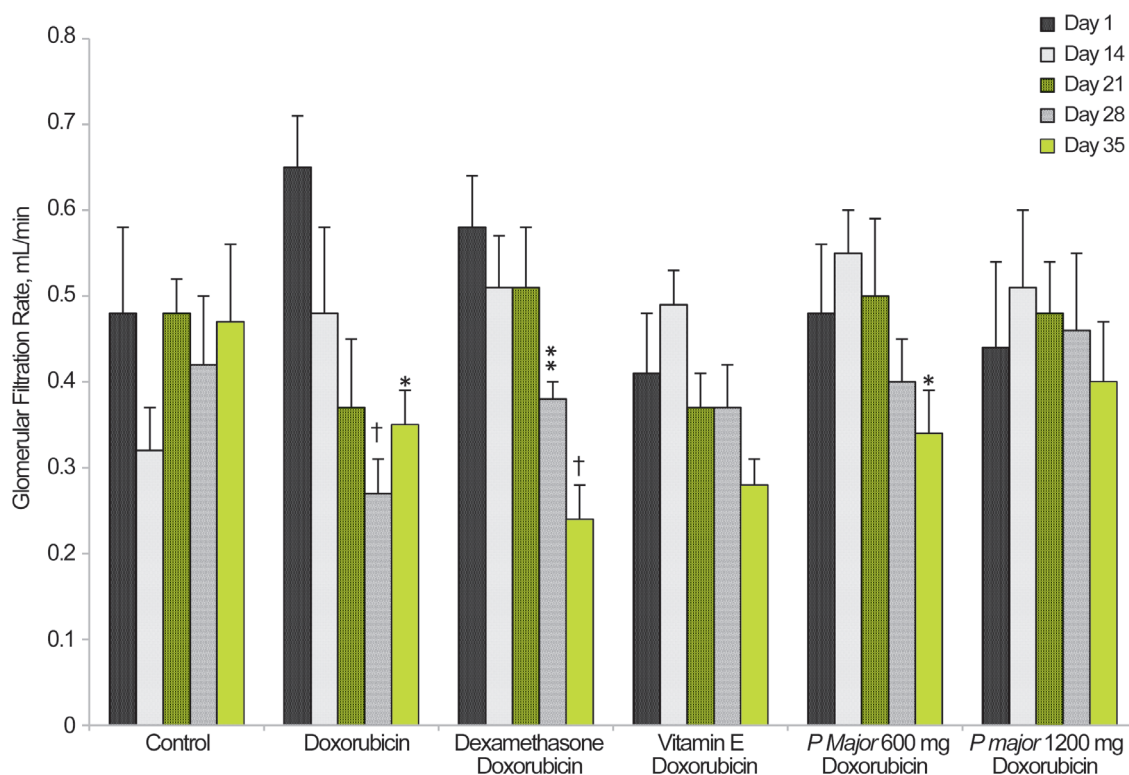


Figure 1. Glomerular filtration rate in the experimental groups. Values are the mean ± standard error of mean.

* $P < .05$ compared with day 1

† $P < .01$ compared with day 1

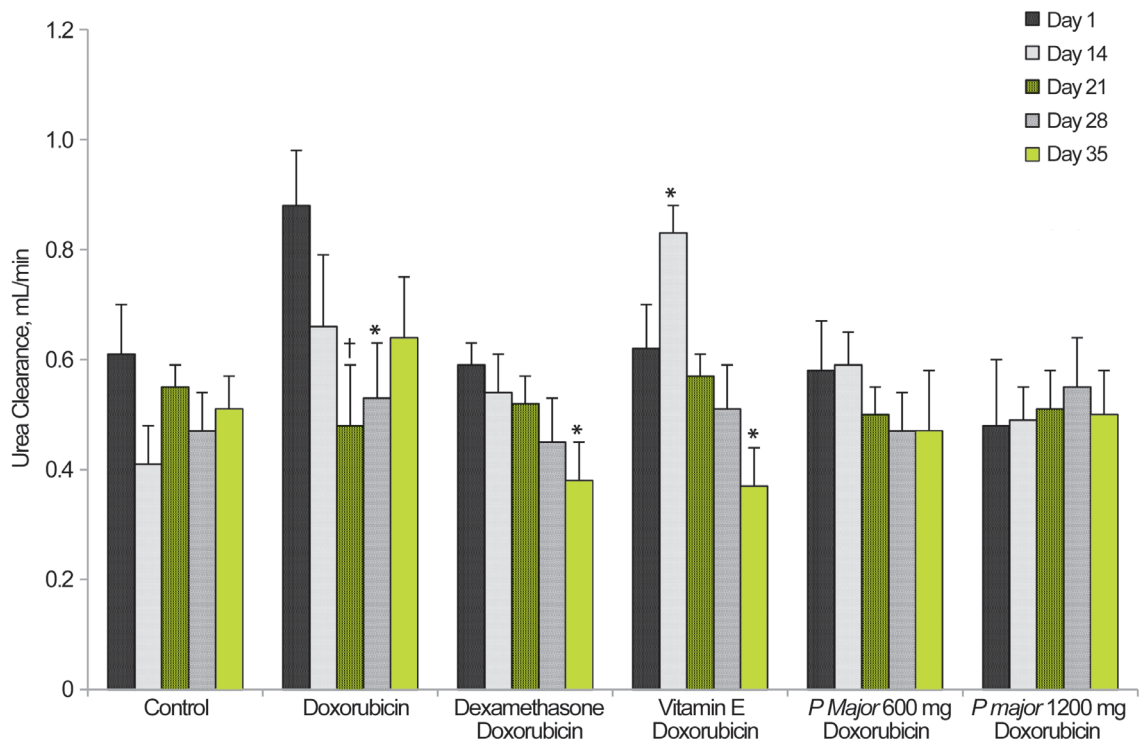


Figure 2. Urea clearance in the experimental groups. Values are the mean \pm standard error of mean.

* $P < .05$ compared with day 1

† $P < .01$ compared with day 1

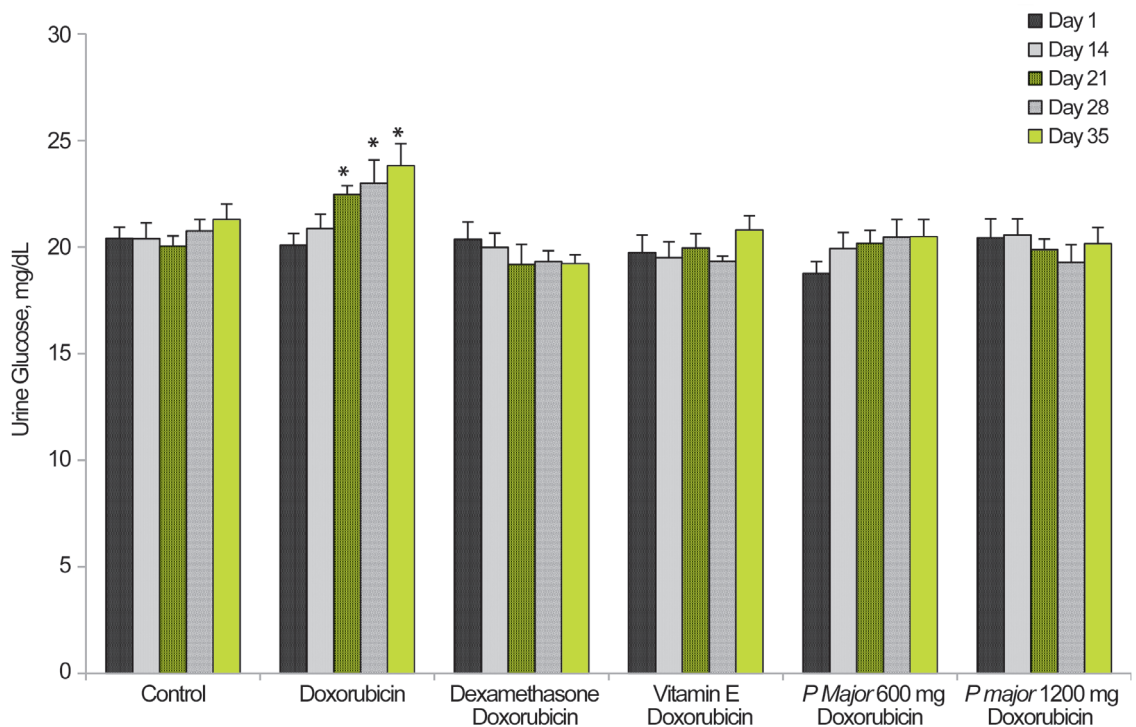


Figure 3. Urine glucose concentration in the experimental groups. Values are the mean \pm standard error of mean.

* $P < .05$ compared with day 1

significantly decreased the GFR on day 35 compared to day 1 ($P < .05$), but the urea clearance and urine

glucose level showed no significant change between different days of the experiment (Figures 1 to 3).

However, there was no significant change in GFR, urea clearance, and urine glucose concentration between different days in the *P major* 1200 group (Figures 1 to 3).

Kidney Injury

Histopathological assessment of renal tissue sections from the doxorubicin-treated animals showed glomerular and tubular degeneration, intratubular cast formation, and inflammatory cell infiltration (Figure 4). In contrast, treatment of the doxorubicin-injected rats with *P major* extract, dexamethasone, and vitamin E improved renal histopathological changes (Figure 4). The percent of kidney damage in the doxorubicin-treated

animals was significantly higher than those of the control group ($P < .001$; Figure 5). Treatment of the rats with *P major* extract, dexamethasone, and vitamin E significantly lowered the percent of kidney damage compared with the doxorubicin group ($P < .001$; Figure 5).

DISCUSSION

Nutritional intervention research has demonstrated that different *Plantago* species show biological activities and exert protection in different disease models.⁹⁻¹¹ We previously reported the beneficial effects of *P major* extract in attenuating the nephrotoxicity associated with cisplatin.⁵ In the present study, the protective effect of *P major*

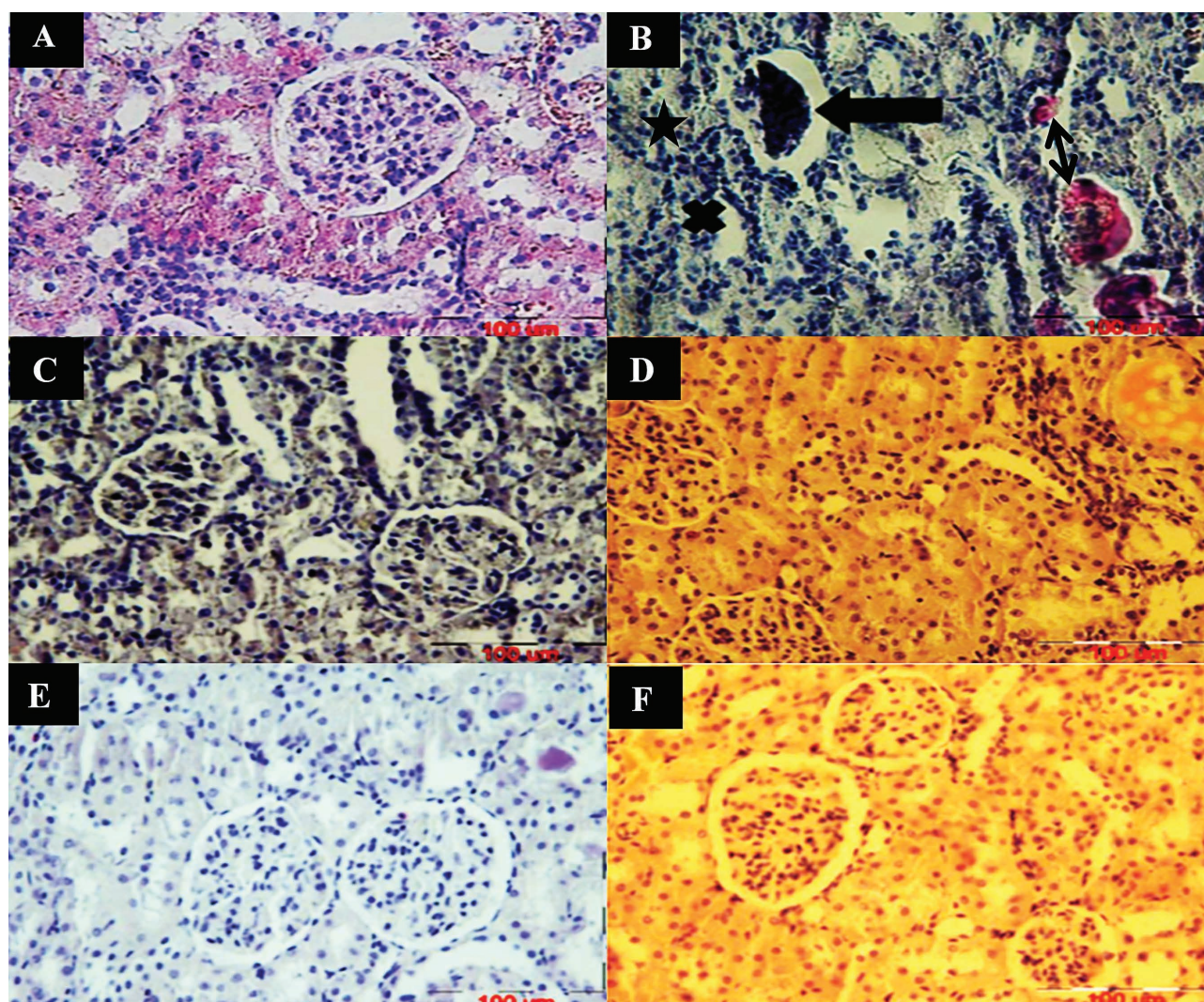


Figure 4. Light microscopy of renal section from experimental groups. **A**, Control group showed normal morphology. **B**, doxorubicin group showed glomerular atrophy (thick arrow), tubular atrophy (times), hyaline casts (double arrow), and interstitial infiltration (star). **C** to **F**, Rats treated with dexamethasone, vitamin E, and *P major* extract (600 mg/kg and 1200 mg/kg) showed mild tubular, glomerular, and interstitial changes (hematoxylin-eosin, $\times 400$).

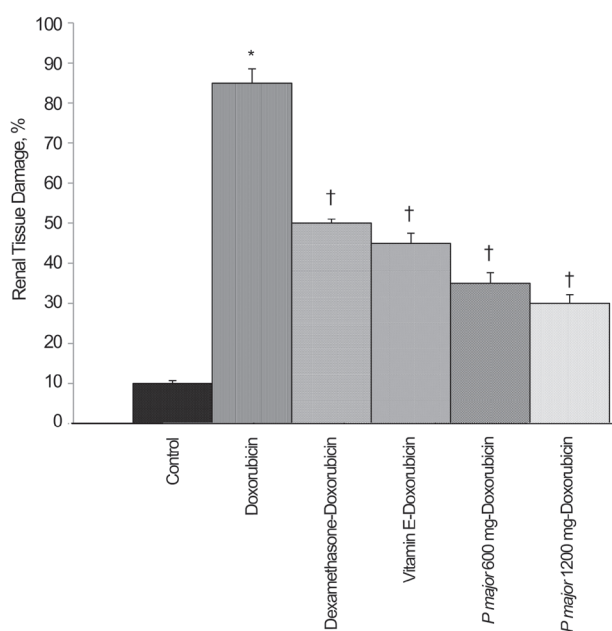


Figure 5. Percentage of renal tissue damage in the experimental groups. Values are the mean ± standard error of mean. * $P < .001$ compared with the control group † $P < .001$ compared with the doxorubicin group

extract against nephropathy induced by doxorubicin was evaluated. The current results indicated that *P major* extract improved doxorubicin-induced renal injury, as assessed by functional and histological parameters. Doxorubicin is an effective anticancer drug that the induction of nephrotic syndrome and other organ toxicities limits its clinical application. Nephrotic syndrome is an important clinical condition that its underlying mechanisms are not fully understood and the treatment is often ineffective.¹² Most remedies are aimed to resolve the nephrotic syndrome-associated secondary symptoms including edema, hyperlipidemia, and venous complications, and thus, not efficacious to prevent progression toward kidney failure. The proteinuria created by nephrotic syndrome is due to the damage to glomerular barrier components.

Doxorubicin-induced nephropathy is a valuable experimental model for finding out the processes involved in the progression of proteinuric kidney disease. Doxorubicin induces renal injury by direct toxic effect on the glomerular basement membrane, podocytes, glomerular endothelial cells, and subsequent tubulointerstitial inflammation and fibrosis.¹²⁻¹ Kidney function is also affected so that increased serum urea and creatinine concentrations, decreased urea and creatinine clearance, reduced serum albumin, massive proteinuria, and

dyslipidemia can be seen following doxorubicin administration.¹⁵⁻¹⁷ Several dosages have been reported for doxorubicin administration.^{3,18,19} In the present study, the nephropathy was created by a single-dose injection of doxorubicin. Results from the current study, in line with previous studies, revealed significant decreases in GFR and urea clearance and an increase in urine glucose levels after treatment with doxorubicin.^{16,20,21}

Histopathological examination showed that following doxorubicin administration, there were severe glomerular, interstitial, and tubular lesions including cast formation, interstitial infiltration, hemorrhage, dilated glomerular space, and glomerular atrophy. Similar results were also observed by other investigators.^{22,23} In this study, treatment of doxorubicin-injected rats with *P major* extract for 1 week before and 4 consecutive weeks after a single-dose injection of doxorubicin showed a considerable improvement in these functional parameters. Also, *P major* extract at 600 mg/kg and 1200 mg/kg could significantly decrease the renal morphological changes induced by doxorubicin. Interestingly, these effects of *P major* extract were similar and even more than those of vitamin E and dexamethasone.

The exact mechanisms underlying the improvement of nephropathy by *P major* extract are not fully elucidated. Nevertheless, it has been determined that *P major* is a source of bioactive compounds including flavonoids, glycosides, and polyphenolic compounds with potential antioxidant and anti-inflammatory effects.²⁴ Different studies have reported that free radical generation, lipid peroxidation, and antioxidant enzymes inhibition are the main mechanisms for the pathogenic effects of doxorubicin.^{25,26} Previous studies have reported that *P major* protects the activity of superoxide dismutase and catalase antioxidant enzymes and decreases the lipid peroxidation in different tissues.^{5,27}

Inflammation also involves in the pathogenesis of doxorubicin-induced nephropathy.²⁸ It has been shown that doxorubicin administration increases the activity of nuclear factor- κ B and subsequently activates the inflammatory reactions in the kidney. Also, Cheng and colleagues showed that doxorubicin markedly increased cyclooxygenase-2 expression in podocytes from transgenic mice compared with the wild-type mice.²⁹ Previous investigations have

claimed that 3 substances from *P major* including α -linolenic acid, ursolic acid, and oleanolic acid are selective inhibitors of cyclooxygenase-2.^{30,31} Furthermore, *P major* leaves extract showed anti-inflammatory activity by inhibition of nuclear factor- κ B in oral epithelial cell cultures.³² On the same basis, the protective effect of *P major* extract maybe due to its antioxidant and anti-inflammatory properties.

CONCLUSIONS

Plantago major extract markedly improved the doxorubicin-induced nephropathy. The underlying mechanism may be attributed to its antioxidant and anti-inflammatory activity. Further studies are necessary to clarify the exact mechanisms of beneficial actions of *P major* in nephropathy associated with doxorubicin.

ACKNOWLEDGMENTS

This study was part of a Master's of Science thesis and was financially supported by the Research Council of Mashhad University of Medical Sciences, Mashhad, Iran.

CONFLICT OF INTEREST

None declared.

REFERENCES

1. Katzung BG, Masters SB, Trevor AJ, editors. Basic and clinical pharmacology. 12 ed. NewYork: McGraw-Hill; 2012.
2. Lee VW, Harris DC. Adriamycin nephropathy: a model of focal segmental glomerulosclerosis. *Nephrology (Carlton)*. 2011;16(1):30-8.
3. Ayla S, Seckin I, Tanriverdi G, et al. Doxorubicin induced nephrotoxicity: protective effect of nicotinamide. *Int J Cell Biol*. 2011;2011:390238.
4. Samuelsen AB. The traditional uses, chemical constituents and biological activities of *Plantago major* L. A review. *J Ethnopharmacol*. 2000;71:1-21.
5. Parhizgar S, Hosseinian S, Hadjzadeh MAR, et al. Renoprotective Effect of *Plantago Major* Against Nephrotoxicity and Oxidative Stress Induced by Cisplatin. *Iran J Kidney Dis*. 2016;10:182-8.
6. Núñez Guillén ME, da Silva Emim JA, Souccar C, Lapa AJ. Analgesic and Anti-inflammatory Activities of the Aqueous Extract of *Plantago major* L. *Int J Pharmacogn*. 1997;35:99-104.
7. Stanisavljević IT, Stojičević SS, Veličković DT, Lazić ML, Veljković VB. Screening the antioxidant and antimicrobial properties of the extracts from plantain (*Plantago major* L.) leaves. *Sep Sci Technol*. 2008;43:3652-62.

8. Gomez-Flores R, Calderon C, Scheibel L, et al. Immunoenhancing properties of *Plantago major* leaf extract. *Phytother Res*. 2000;14:617-22.
9. Hong ST, Hong CO, Nam MH, et al. Protective Effect of *Plantago asiatica* L. Leaf Ethanolic Extract Against Ferric Nitrosylacetate-Induced Prostate Oxidative Damage in Rats. *Hangug Sigmum Wisaeng Anjeonseong Haghoeji*. 2011;26:260-5.
10. Kobeasy M, Abdel-Fatah O, El-Salam SA. Gastroprotective effect of *plantago major* L. against gastric injury induced by aspirin in rats. *J Chem Acta*. 2013;2:86-91.
11. Akbarian S-A, Asgary S, Feizi A, Iraj B, Askari G. Comparative study on the effect of *Plantago psyllium* and *Ocimum basilicum* seeds on anthropometric measures in nonalcoholic fatty liver patients. *Int J Prev Med*. 2016.10;7:114.
12. Jeansson M, Björck K, Tenstad O, Haraldsson B. Adriamycin alters glomerular endothelium to induce proteinuria. *J Am Soc Nephrol*. 2009;20:114-22.
13. Sadlier DM, Connolly SB, Kieran NE, et al. Sequential extracellular matrix-focused and baited-global cluster analysis of serial transcriptomic profiles identifies candidate modulators of renal tubulointerstitial fibrosis in murine adriamycin-induced nephropathy. *J Biol Chem*. 2004;279:29670-80.
14. Tamaki K, Okuda S, Ando T, Iwamoto T, Nakayama M, Fujishima M. TGF- β 1 in glomerulosclerosis and interstitial fibrosis of adriamycin nephropathy. *Kidney Int*. 1994;45:525-36.
15. Mohebbati R, Khajavi Rad A, Naser Shafei M, et al. The Effects of Vitamin C on Adriamycin-Induced Hypercholesterolemia in Rat. *Curr Nutr Food Sci*. 2015;11:309-14.
16. Mohebbati R, Abbasnezhad A, Khajavi Rad A, Haghshenas M, Khazdeir M. Effect of Hydroalcoholic Extract of *Curcuma longa* on Adriamycin-Induced Renal Damage in Rats. *Horiz Med Sci*. 2016;22:337-44.
17. Mansour MA, El-Kashef HA, Al-Shabanah OA. Effect of captopril on doxorubicin-induced nephrotoxicity in normal rats. *Pharmacol Res*. 1999;39:233-7.
18. Venkatesan N, Punithavathi D, Arumugam V. Curcumin prevents adriamycin nephrotoxicity in rats. *Br J Pharmacol*. 2000;129:231-4.
19. Badary OA, Abdel-Naim AB, Abdel-Wahab MH, Hamada FM. The influence of thymoquinone on doxorubicin-induced hyperlipidemic nephropathy in rats. *Toxicol*. 2000;143:219-26.
20. Mihailović-Stanojević N, Jovović D, Miloradović Z, Grujić-Milanović J, Jerkić M, Marković-Lipkovski J. Reduced progression of adriamycin nephropathy in spontaneously hypertensive rats treated by losartan. *Nephrol Dial Transplant*. 2008;24:1142-50.
21. Desassis J, Raats C, Bakker M, Van den Born J, Berden J. Antiproteinuric effect of ciclosporin A in adriamycin nephropathy in rats. *Nephron*. 1997;75:336-41.
22. Wang Y, Wang YP, Tay Y-C, Harris DC. Progressive adriamycin nephropathy in mice: sequence of histologic and immunohistochemical events. *Kidney Int*. 2000;58:1797-804.

23. Tang S, Leung J, Chan L, Eddy A, Lai K. Angiotensin converting enzyme inhibitor but not angiotensin receptor blockade or statin ameliorates murine adriamycin nephropathy. *Kidney Int.* 2008;73:288-99.
24. Zubair M. Genetic and environmental effects on polyphenols in *Plantago major*. 2010. Available from: https://www.researchgate.net/publication/47513038_Genetic_and_environmental_effects_on_polyphenols_in_Plantago_major
25. Kalaiselvi P, Pragasam V, Chinnikrishnan S, Veena CK, Sundarapandiyan R, Varalakshmi P. Counteracting adriamycin-induced oxidative stress by administration of N-acetyl cysteine and vitamin E. *Clin Chem Lab Med.* 2005;43:834-40.
26. Wei L, Surma M, Gough G, Shi S, et al. Dissecting the mechanisms of doxorubicin and oxidative stress-induced cytotoxicity: the involvement of actin cytoskeleton and ROCK1. *PLoS One.* 2015;10:e0131763.
27. Mello JC, Gonzalez MV, Moraes VW, Prieto T, Nascimento OR, Rodrigues T. Protective Effect of *Plantago major* Extract against t-BOOH-Induced Mitochondrial Oxidative Damage and Cytotoxicity. *Mol.* 2015;20:17747-59.
28. Szalay CI, Erdélyi K, Kökény G, et al. Oxidative/nitrative stress and inflammation drive progression of doxorubicin-induced renal fibrosis in rats as revealed by comparing a normal and a fibrosis-resistant rat strain. *PLoS One.* 2015;10:e0127090.
29. Cheng H, Wang S, Jo YI, et al. Overexpression of cyclooxygenase-2 predisposes to podocyte injury. *J Am Soc Nephrol.* 2007;18:551-9.
30. Ringbom T, Segura L, Noreen Y, Perera P, Bohlin L. Ursolic acid from *Plantago major*, a selective inhibitor of cyclooxygenase-2 catalyzed prostaglandin biosynthesis. *J Nat Prod.* 1998;61:1212-5.
31. Stenholm Å, Göransson U, Bohlin L. Bioassay-guided Supercritical Fluid Extraction of Cyclooxygenase-2 Inhibiting Substances in *Plantago major* L. *Phytochem Anal.* 2013;24:176-83.
32. Zubair M. Genetic variation, biochemical contents and wound healing activity of *plantago major*. *Acta Universitatis Agriculturae Sueciae.* 2012. Available from: https://pub.epsilon.slu.se/8685/1/zubair_m_120402.pdf

Correspondence to:

Abolfazl Khajavi Rad, PhD

Department of Physiology, School of Medicine, Mashhad University of Medical Sciences, Pardis, Azadi Sq, Mashhad 917794-8564, Iran

Tel: +98 513 882 8565

Fax: +98 513 882 8564

E-mail: khajavirada@mums.ac.ir

Zohreh Naji Ebrahimi Yazd and Sara Hosseini contributed equally to this publication as first authors.

Received August 2017

Accepted October 2017