

# Kaposi Sarcoma After Kidney Transplantation

Behzad Einollahi

Department of Nephrology,  
Nephrology and Urology  
Research Center, Baqiyatallah  
University of Medical Sciences,  
Tehran, Iran

Keywords. Kaposi  
sarcoma, organ recipients,  
immunosuppressive agents,  
kidney transplantation,  
herpesvirus, sirolimus

Skin cancers are the most common tumors among transplant recipients who receive immunosuppressive agents. Kaposi sarcoma (KS) is one of the most common malignancies to occur in kidney transplant recipients, especially in the Middle East countries. Its prevalence in comparison with other neoplasms is also relatively higher in Iran (> 35%). The KS-associated herpesvirus or human herpesvirus 8 is a newly discovered herpesvirus found in all forms of the KS including those among immunosuppressed transplant recipients. Kaposi sarcoma usually regresses after withdrawal or reduction of immunosuppressive agents.

A wide variety of therapies have been used for KS, including radiotherapy and administration of interferon and different chemotherapeutic regimens. Sirolimus exhibits antiangiogenic activity related to impaired production of vascular endothelial growth factor and limited proliferative response of endothelial cells to the stimulation by vascular endothelial growth factor. Therefore, it can inhibit the progression of KS. Accordingly, replacement of calcineurin inhibitors by a sirolimus can show promising results in the prevention of KS.

IJKD 2007;1:2-11  
www.ijkd.org

## INTRODUCTION

Kaposi sarcoma (KS) is an enigmatic cancer that has been a challenge for the medical community since its original description in 1872.<sup>1</sup> Renewed interest in KS was triggered by its association with the increasing number of patients that are immunocompromised, either as a result of acquired immunodeficiency syndrome (AIDS),<sup>2,3</sup> or following organ transplantation.<sup>4</sup> Kaposi sarcoma is one of the most common malignancies to occur in kidney transplant recipients,<sup>5,6</sup> especially in the developing countries.<sup>7-9</sup> The first case of post-kidney transplantation KS was reported in 1969, and since then, a number of reports have confirmed the high incidence of this cancer among immunosuppressed transplant recipients.<sup>10</sup>

The long-term use of immunosuppressive agents for prevention of allograft rejection increases the risk of malignancy approximately 100 times as high as that in the general population.<sup>11</sup> Skin cancers,

mostly squamous cell carcinoma (SCC), are the most common tumors among persons have solid-organ transplantation.<sup>11</sup> We, however, found that the most common malignancy after kidney transplantation was KS among the Iranian patients.<sup>12</sup> The prevalence rate of posttransplant malignancies in total differs between geographical areas; for example, in Europe, that rate is 1.6% and in Australia is 24%, with a mean of 6%. These differences are due to the prevalence of skin cancers in those areas.<sup>12</sup> Our 1.8% prevalence rate of malignancies in over a 19-year experience in kidney transplantation, is one of the lowest compared with other studies.<sup>12</sup> In addition to the overall prevalence, differences between geographical areas also exist in cancer types—eg, the rate of skin cancer at our center was lower compared with other studies.<sup>12</sup>

The prevalence of KS after kidney transplantation varies significantly in different geographic areas,<sup>13</sup> supporting the theory of racial or environmental

factors in its pathogenesis. The number of patients with KS has steadily increased following a dramatic increase in the number of kidney transplantations during the recent decades, particularly in of Mediterranean descent.<sup>14</sup> Most cases occur in transplant recipients of Mediterranean, Jewish, Arabic, Caribbean, or African descent; the reported incidence ranges from 0.5% in most Western countries (including the United States) up to 5.3% in Saudi Arabia.<sup>14</sup> Kaposi sarcoma, in comparison with other neoplasms, is relatively more prevalent in also Spain, Italy, and Greece with figures of about 8.4%, 11.5%, and 24% respectively.<sup>15-18</sup>

### CLINICAL VARIANTS OF KAPOSI SARCOMA

There are 4 epidemiologic forms of KS including the classic, endemic, epidemic, and immunosuppression-associated forms.<sup>19</sup> The classic variant primarily affects elderly men of the Eastern European and Mediterranean origin. Endemic or African form was proposed when in the 1950s, KS was recognized as being common in portions of Africa, accounting for 3% to 9% of the reported cancers in Uganda. This form is not typically associated with immune deficiency. Immunosuppression-associated or transplantation-associated form is the KS seen in organ transplant recipients and patients who are receiving immunosuppressive therapy for a variety of medical conditions. Particularly members of certain ethnic groups might be at the increased risk for KS. In addition, transplantation per se may lead to transmission of human herpesvirus 8 (HHV8) infection. Finally, the epidemic or AIDS-associated KS is an aggressive and frequently fatal variant. Although the incidence of KS in the American men with AIDS decreased from 40% in 1981 to less than 20% in 1992, it remains the most common AIDS-associated cancer in the United States.<sup>19</sup>

### ETHNICITY, GENDER, AND AGE VARIATIONS

The relative frequency of KS among cancers that involve our kidney transplant recipients (36.8%) is among the highest in the world, consonant with that reported from Saudi Arabia.<sup>20, 21</sup> In the reports from the other developing countries, KS is consistently the most common malignancy after kidney transplantation.<sup>22-24</sup> In developed countries,

the risk of KS is increased,<sup>25</sup> accounting for up to 10% of all posttransplant cancers.<sup>26,27</sup> Oettle was the first who noted profound racial differences in susceptibility to the endemic form of KS; black patients were considerably more prone to KS than the white and Indian patients living alongside them.<sup>28</sup> Genetic variation may explain racial differences in the incidence of posttransplant KS. In Saudi Arabia, the human leukocyte antigen-A2 was significantly more common in patients with posttransplant KS compared to controls.<sup>29</sup> However, the role of genetics in the etiology of posttransplant KS remains uncertain, and requires further investigation. Ethnic variation may arise from differences in the prevalence of HHV8 infection, an important factor in the etiopathogenesis of KS. Several cross-sectional epidemiological studies have found that HHV8 is more prevalent in regions where there is a higher prevalence of KS.<sup>30-32</sup> The seroprevalence of HHV8 antibodies in kidney allograft recipients from developing countries (especially sub-Saharan Africa) is much higher than that in the general population of Europe and the US.<sup>33-35</sup> In South Africa, standardized prevalence of HHV8 antibodies among black blood donors was 4-fold as high as that among the whites from the same area<sup>36</sup>; the prevalence rose to 39% in the general black population.<sup>37</sup> A recent South African study confirmed that kidney allograft recipients had relatively higher levels of anti-HHV8 antibodies, and also that marked racial differences existed in the prevalence of antibodies, with the lowest being in whites (1.8%) and the highest in colored patients (12.5%) in South Africa.<sup>38</sup>

The male-female ratio of posttransplant KS reportedly ranges between 3:1 and 1.5:1,<sup>29,39,40</sup> but in the developing countries, men constitute up to 93% of the kidney allograft recipients.<sup>24</sup> In all other forms of KS, the disease is much more common in men. Posttransplant KS, like the epidemic form, tends to occur in younger patients and is less strongly correlated with the onset of the disease than with the duration of immunosuppression.<sup>41</sup>

### CLINICAL ASPECTS

Kaposi sarcoma usually appears early (a mean interval of 13 months from transplantation), its onset has been documented as late as 18 years afterwards, though. The ratio of male to female patients is 3.3:1 to 1:1; the mean age at the time

of diagnosis is 43 years, which is younger than that among patients with classic KS.<sup>14</sup> Cases have been reported even in children with transplants. Ninety percent of transplant recipients with KS have cutaneous lesions, mucosal lesions, or both. For unclear reasons, visceral involvement is less common in recipients of kidney allografts as compared to liver or heart allografts (25% to 30% versus 50%).<sup>14</sup> At least partly because of this, patients who develop KS after a liver or heart transplant have shorter survivals than those with kidney transplantation. Purely visceral disease occurs in 10% of patients.<sup>14</sup> A grading system (grades 1 through 3) has been proposed to reflect the extent of the disease.<sup>14</sup> Posttransplantation KS is usually similar to the classic form, manifested as angiomatous lesions predominating on the legs and causing lymphedema. The oropharyngeal and conjunctival mucosa may be affected. Visceral disease predominantly affects the lymph nodes, gastrointestinal tract, and lungs.<sup>14</sup> The legs are affected twice as commonly as the arms.<sup>42</sup> In posttransplant KS, the course of skin disease is generally benign, but reports from the Arabian Peninsula describe an aggressive pattern in more than one-quarter of kidney transplant recipients, characterized by rapid growth within a few weeks and widespread dissemination, often with visceral involvement.<sup>43,44</sup> This aggressive cutaneous form of posttransplant KS seems to be confined to Saudi Arabia.<sup>43,44</sup>

There is a scarcity of information on postmortem findings in posttransplant KS, suggesting that subclinical disease is more common than suspected. The experience in other forms of KS suggests that the internal organs are more commonly affected than is clinically appreciated; estimates of patients with internal organ involvement by KS range from 10% to 70%.<sup>43,44</sup> This may be because the disease is indeed silent, and that the clinical manifestations of visceral disease are unusual. This is supported by the observation that in a large number of patients with KS who have routine endoscopic examinations, there are lesions in the gastrointestinal tract that are clinically occult.<sup>43,44</sup> Alternatively, patients with more extensive and aggressive KS disease die and undergo postmortem examinations.

Extracutaneous involvement most commonly involves lymph nodes followed by the intestines and lungs. Involvement of bone and kidney

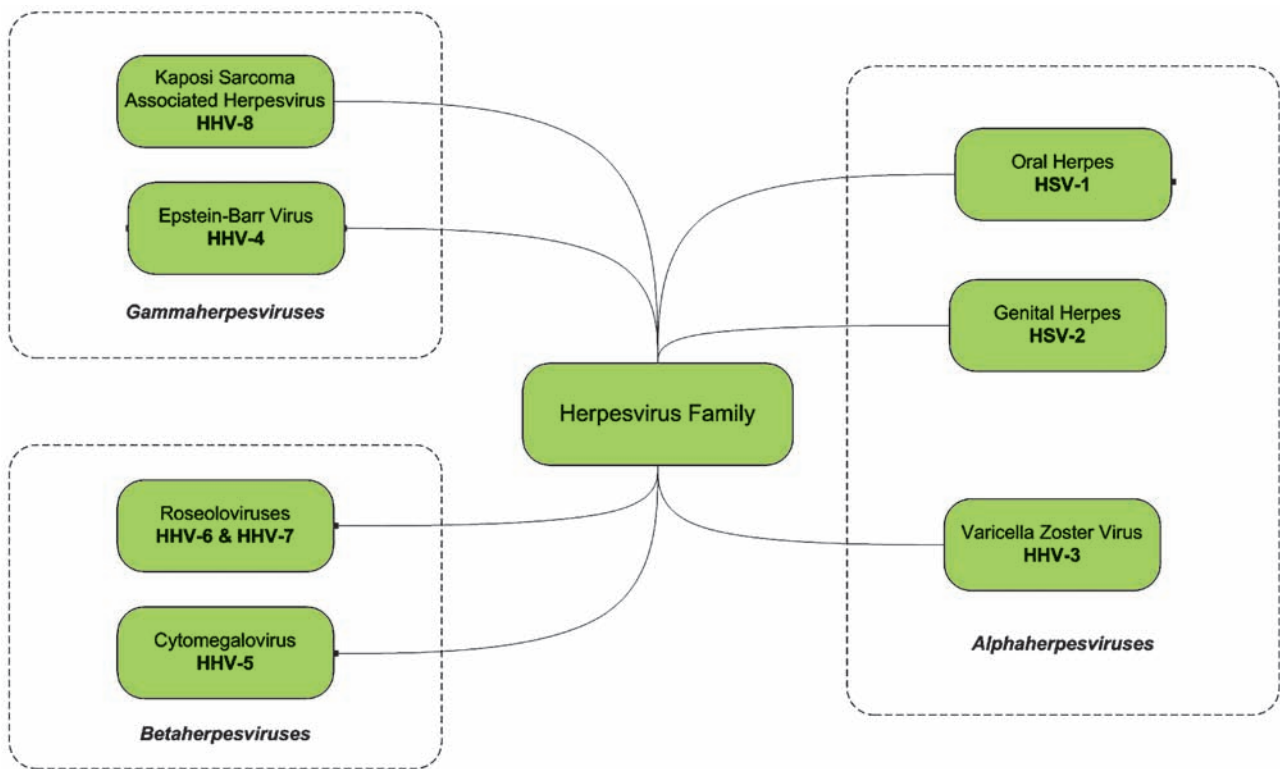
allografts are both unusual, and emphasize the value of postmortem examination.<sup>45</sup>

### ASSOCIATED HERPESVIRUS WITH KAPOSI SARCOMA

The HHV-8 also known as *KS herpesvirus* (KSHV),<sup>46</sup> and is associated with body cavity-based lymphomas and multicentric Castleman disease.<sup>47-49</sup> The HHV-8 is transmitted sexually,<sup>36,50</sup> but other routes of transmission probably exist because, in some cases, infection has been shown to be acquired in the childhood living in HHV-8-endemic areas such as the Mediterranean Europe and sub-Saharan Africa.<sup>51-53</sup> Whether the HHV-8 is transmitted through blood transfusion remains controversial.<sup>54</sup> However, Hladik and colleagues provided strong evidence that the HHV-8 is also transmitted by blood transfusion.<sup>55</sup> Transmission of the HHV-8 has been associated with the use of drugs that are administered parenterally and transplantation of infected organs.<sup>55</sup> The HHV-8 infection has been seen in patients undergoing cardiac surgery who received multiple units of non-leukocyte-reduced blood. Several case reports of KS have described an association with blood transfusion. Infectious HHV-8 has been recovered from a blood donor, and the viral DNA has been detected in blood donors in Africa.<sup>55,56</sup>

Herpesviruses are divided into three subfamilies (Figure), and both KSHV (HHV-8) and Epstein-Barr virus (EBV) are members of the gammaherpesvirus subfamily.<sup>57</sup> Gammaherpesviruses play an important role in cellular proliferation and the development of malignancies. Molecular epidemiologic data suggest that HHV-8 may be an ancient pathogen of humans that has spread very slowly in the population.<sup>58</sup> Alternatively, the virus may have become pathogenic to humans more recently (ie, within the past several thousand years), originating from a nonhuman primate host in Africa and slowly spreading to the Mediterranean populations. In either case, any attempt to trace the origin and distribution of HHV-8 must be taken into consideration the more recent rapid intercontinental dissemination of the virus before and during the AIDS epidemic.

The 165-kb *KSHV* genome was sequenced within 2 years after its discovery,<sup>59</sup> and provided important clues about the way in which this virus might induce uncontrolled cellular proliferation. Several viral gene products of the HHV-8 are able



The herpesvirus family.

to affect both cell cycle regulation and the control of apoptosis. The HHV-8 contains viral oncogenes that are important in the pathogenesis of tumor formation; the HHV-8 can transform primary human endothelial cells, which are the cells affected in KS.<sup>60</sup> Latency-associated nuclear antigen 1, a latent nuclear antigen of HHV-8, may contribute to oncogenesis by targeting the retinoblastoma protein transcriptional regulatory pathway.<sup>61</sup> The HHV-8 encodes cyclin K that inhibits the transcription of oncostatin M, a protein with growth-suppressive effects that prevent tumorigenesis.<sup>62</sup> Viral interferon (IFN) regulatory factor induces cellular transformation and prevents apoptosis mediated by p53 tumor suppressor, thereby facilitating uncontrolled cellular proliferation.<sup>63</sup> Viral interleukin-6 blocks host production of IFN- $\alpha$ , preventing the cell cycle arrest that is normally triggered by this cytokine.<sup>64</sup> The *KSHV* encodes a viral G protein-coupled receptor (VGPCR) that induces multifocal KS-like lesions in transgenic mice. The VGPCR may induce transformation via activation of nuclear factor-kappa B and induction of proinflammatory cytokines.<sup>65,66</sup> The *KSHV* induces genetic reprogramming of both vascular and lymphatic cells so that they more

closely resemble each other as opposed to their corresponding uninfected phenotypes.<sup>67</sup>

The *KSHV* also encodes interleukin-6 and three functional chemokines that can be secreted by infected cells and that affect the replication and migration of uninfected cells.<sup>68</sup> The viral cytokine interleukin-6 induces B-cell proliferation, whereas the chemokines may activate angiogenesis and inhibit the immune type 1 helper T-cell responses.<sup>69</sup>

## EPIDEMIOLOGY OF KAPOSI SARCOMA AND HHV-8

### HHV-8 Infection in Humans

Using the standard polymerase-chain-reaction assays, the HHV-8 DNA can be detected in the peripheral-blood cells of only about half of the infected persons, indicating that viremia is not prominent. However, this technique, as well as the less sensitive Southern blot hybridization assay, can detect viral DNA in virtually all lesions of the KS. Identification of a small percentage of lesions as negative for HHV-8 almost always results from misdiagnosis or suboptimal preparation of specimens. The HHV-8 is clearly associated with KS, body-cavity-related

B-cell lymphoma (primary effusion lymphoma), and some plasma-cell forms of multicentric Castleman disease.<sup>19</sup> Reports of the involvement of the HHV-8 in other diseases, such as multiple myeloma, sarcoidosis, and posttransplantation skin tumors, have not been confirmed. Serologic assays to detect HHV-8-specific antibodies have a high sensitivity, and such methods are preferable to polymerase chain reaction, particularly for detecting previous exposure to the virus. Antibody responses to HHV-8 antigens appear to be lifelong in most persons, but they may be lost in patients at the end stage of AIDS. The results of serologic studies support the notion that infection with HHV-8 is nearly universal in patients with KS, since specific antibodies are detectable in 70% to 90% of all patients with KS and almost 100% of immunocompetent patients with the disease. The results of an indirect immunofluorescence assay for the latency-associated nuclear antigen and of an enzyme-linked immunosorbent assay that uses recombinant antigens made from KSHV open-reading-frame proteins 65 and K8.1A are highly concordant. When properly performed in standardized formats, these assays can be used in combination for diagnostic purposes.<sup>19</sup>

#### Rates of Infection in Various Populations

Results of serologic studies show that, unlike other human herpesviruses, the HHV-8 is not ubiquitous. The infection rates instead parallel the incidence of KS, with low rates in the United States, many parts of Europe, and Asia; intermediate rates in Mediterranean countries; and the highest rates in Central Africa (Uganda, Zambia, and South Africa).<sup>19</sup> The seroprevalence of the HHV-8 among blood donors ranges from 0.2% in Japan, where the KS is rare, to up to 10% in the United States, and to more than 50% in many African populations. The rates in Italy and other Mediterranean countries fall between these extremes.<sup>19</sup> Within this range, there are at-risk populations with particularly high seroprevalence rates. Regardless of their human immunodeficiency virus serostatus, homosexual men have a higher rate of KS than the general male population and can have rates of asymptomatic infection approaching 40%.<sup>19</sup>

Most primary HHV-8 infections appear to be asymptomatic. Posttransplantation KS has also

resolved when immunosuppressive regimens were discontinued.<sup>19</sup>

#### Transmission

The HHV-8 can be transmitted sexually and by other means. Sexual transmission predominates in developed countries with a low prevalence of the virus, and it is thought to be more readily transmissible through homosexual than through heterosexual activities. In contrast, other modes of transmission predominate in African countries, where infection can occur during childhood. Maternal-infant transmission, whether during labor and delivery or transplacentally, accounts for a portion of the HHV-8 infections in areas where infection is highly endemic.<sup>70</sup> However, the HHV-8 infection also occurs later in childhood and during adolescence in such areas, a point that suggests transmission of the virus through some forms of nonsexual contact. The exact routes of transmission are not known, although the HHV-8 has been detected in both saliva and semen from infected persons. Kaposi sarcoma develops in 0.1% to 1% of transplant recipients in areas with a low prevalence of the disease and in up to 5% of such patients in areas with a high prevalence.<sup>19</sup> The clinical disease predominantly results from reactivation of the virus, but it may also represent a primary infection transmitted by the transplanted organs. In one series of 220 kidney transplant recipients, the seroprevalence of HHV-8 increased from 6% on the day of transplantation to 18% at one year and KS developed in 2 of these patients within 26 months after transplantation.<sup>71</sup>

#### TREATMENT

Based on our own observations, we would concur that the mainstay of treatment of posttransplant KS is reduction of immunosuppression. In our study, reduction of immunosuppression in patients with limited disease resulted in remission in all of cases; in addition, kidney allograft function remained preserved.<sup>71</sup> This suggests that discontinuation of immunosuppressives is unnecessary as the primary therapeutic option in patients with the disease limited to the skin. Although KS usually regresses after manipulation of immunosuppression, a withdrawal or reduction of such therapy in kidney transplant recipients leads to the loss of the graft in approximately half of patients.<sup>19</sup> In our study,



discontinuation of immunosuppressives following the diagnosis of KS caused complete remission of this cancer in almost all patients and seemed to be relatively safe for kidney allograft function.<sup>71</sup> We have suggested a management algorithm based on progressive reduction and ultimate cessation of immunosuppression. In other reports, varying degrees of success have been achieved, but patients with visceral KS universally have a grim prognosis.<sup>72</sup> The current recommendation for treatment of the superficial nodes involvement is discontinuation of immunosuppression.<sup>43</sup>

Which immunosuppressive agent is withdrawn or reduced appears to be immaterial. Our own bias was to withdraw the most potent immunosuppressive agent, namely cyclosporine, because it may have direct oncogenic potential.<sup>73</sup> On the other hand, some authors have suggested that steroids have a major role in the development of KS,<sup>74,75</sup> and their withdrawal may induce regression of KS lesions.<sup>74,76</sup>

A problem with many published reports is that no time-frame is given within which initial treatment outcomes are justified, before resorting to other modalities of treatment. In a recent report, patients were managed with reduction of immunosuppression for a minimum of 1 month only before other forms of therapy were introduced.<sup>72</sup> Some reports have shown that extensive local lesions may take several months to regress, an experience shared by others, and may in fact show initial deterioration before improvement becomes manifest. From our experience, for isolated skin lesions, we would tentatively recommend an observation period of 2 to 4 months before implementing more potent therapies. Serial photographs of lesions provide a useful objective tool for evaluation of the number, size, and color of lesions. Regression can also be monitored by serial assessments of the size of lesions.<sup>13</sup>

A wide variety of therapies have been used for KS, including radiotherapy, IFN, and different chemotherapeutic regimens. The IFN- $\alpha$  may be effective, but it should be used with caution, because of the risk of graft rejection.<sup>77</sup> In our study, 2 patients who had no response to a reduction or discontinuation of immunosuppressive agents cured by local radiation therapy and 1 patient received vincristine with complete response.<sup>71</sup> Foscarnet has been used successfully in a patient.<sup>78</sup> Anti-CD20

also has been used successfully in another patient.<sup>79</sup> On the other hand, there is an interesting report of spontaneous regression of KS during pregnancy.<sup>80</sup> Another study reports the regression of KS after conversion from cyclosporine to mycophenolate mofetil.<sup>81</sup>

The HHV-8 up-regulates the vascular endothelial growth factor (VEGF) receptor Flk-1/KDR in the endothelial cells. In vitro infection of human primary endothelial cells with HHV-8 causes long-term proliferation and survival of cells. Blocking the interaction between the VEGF and Flk-1/KDR can abolish VEGF-induced proliferation. Sirolimus, an immunosuppressive drug used in kidney transplantation,<sup>82</sup> exhibits antiangiogenic activity related to impaired production of the VEGF and limited proliferative response of the endothelial cells to stimulation by the VEGF, and therefore inhibiting the progression of KS.<sup>83</sup> As mentioned before, the *KSHV* encodes the VGPCR, implicated in the initiation of KS. It was demonstrated that KS-genesis involves stimulation of tuberin (TSC2) phosphorylation by the VGPCR, promoting the activation of mammalian target of rapamycin (mTOR) through both direct and paracrine mechanisms. Pharmacologic inhibition of mTOR with sirolimus prevented the VGPCR sarcomagenesis, while overactivation of this pathway was sufficient to render the endothelial cells oncogenesis. Moreover, mice haploinsufficient for TSC2 are predisposed to vascular sarcomas remarkably similar to KS. Collectively, these results implicate mTOR in KS initiation and suggest that the sarcomagenic potential of *KSHV* may be a direct consequence of the profound sensitivity of the endothelial cells to the VGPCR dysregulation of the TSC2/mTOR pathway.<sup>84</sup> Indeed, pharmacological inhibition of mTOR with sirolimus has shown promising results in preventing the VGPCR tumorigenesis in an animal model for KS. These observations are further validated by coincident reports demonstrating the efficacy of sirolimus as an immunosuppressive and antitumoral solution for posttransplant KS patients. Campistol and colleagues were the first to report complete regression of KS in 2 patients after conversion to sirolimus.<sup>85</sup> Stallone and coworkers also have recently reported complete regression of cutaneous KS in 15 patients after conversion from cyclosporine to sirolimus.<sup>82</sup> However, none of their patients had visceral sarcoma. Zmonarski

and coworkers from Poland, where the tumor is not common, also have reported regression of KS in 2 patients after conversion from calcineurin inhibitors to a sirolimus-based regimen.<sup>86</sup> One patient had palatal mucosa and cutaneous lesions, while the other patient had pulmonary lesions and mediastinal lymphadenopathies, in addition to the previous lesions. Mohsin and colleagues reported a patient with both cutaneous and visceral KS who was successfully treated by conversion from a cyclosporine-based to a sirolimus-based immunosuppression regimen.<sup>87</sup> Yilmaz and coworkers reported a kidney transplant recipient with cutaneous KS who had a complete remission in response to sirolimus therapy.<sup>88</sup> Lebbe and colleagues showed the improvement of KS in 14 patients by switching from a calcineurin inhibitor to sirolimus.<sup>89</sup> Collectively, these data suggest that inhibition of the Akt/TSC/mTOR signaling pathway may provide a novel molecular-based approach for the treatment of patients who currently have a paucity of therapeutic options.<sup>90</sup>

There are a few reports regarding novel treatment options for KS, including the use of imatinib in AIDS-associated KS and sirolimus in kidney transplant KS patients.<sup>82,91</sup> Imatinib is a tyrosine-kinase inhibitor that induces apoptosis in *Bcr-Abl*-positive cell lines, platelet-derived growth factor-positive cells, and *c-kit* positive gastrointestinal stromal cells. Limited information exists regarding its effects on KS cells.<sup>91</sup> Though the drug safety profile is good, it can induce severe adverse events.<sup>92</sup> Because imatinib is metabolized through the CYP3A3 enzyme, it can result in adverse drug interactions. Its safety in patients with renal insufficiency or a kidney allograft is unknown. There is currently no evidence of imatinib effectiveness in transplant-associated KS patients; and therefore, there is no basis for its prescription in this group of patients.

### PREVENTION

Given that candidates for organ transplantation who are seropositive for HHV-8—and thus at risk for KS—can now be identified, chemoprevention should be available in this high-risk population. Such strategies in HHV-8-seropositive candidates for organ transplantation should be directed against the virus itself, and the immunosuppressive regimen should be carefully monitored to avoid

the possibility of rejection. Laboratory studies of the susceptibility of HHV-8 to antiviral drugs suggest that the virus is resistant to acyclovir and penciclovir, but sensitive to ganciclovir, foscarnet, and cidofovir.<sup>93</sup> Cidofovir potently inhibits the synthesis of HHV-8 DNA, and the concentration of adefovir required to block the replication of HHV-8 DNA is lower than that of foscarnet.<sup>94</sup> The clinical usefulness of antiviral drugs (foscarnet, ganciclovir, cidofovir, and adefovir) that have in vitro activity against HHV8 has not yet been adequately documented.

### REFERENCES

1. Kaposi M. Idiopathisches multiples pigmentsarkom der Haut. *Archiv Fur Dermatologie und Syphilis*. 1872;3:265-73.
2. Biggar RJ, Horm J, Lubin JH, Goedert JJ, Greene MH, Fraumeni JF Jr. Cancer trends in a population at risk of acquired immunodeficiency syndrome. *J Natl Cancer Inst*. 1985;74:793-7.
3. Centers for Disease Control (CDC). Revision of the CDC surveillance case definition for acquired immunodeficiency syndrome. Council of State and Territorial Epidemiologists; AIDS Program, Center for Infectious Diseases. *MMWR Morb Mortal Wkly Rep*. 1987;36 Suppl 1:1S-15S.
4. Farge D. Kaposi's sarcoma in organ transplant recipients. The Collaborative Transplantation Research Group of Ile de France. *Eur J Med*. 1993;2:339-43.
5. Sheil AG. Malignancy in organ transplantation recipients. *Transplant Proc*. 1996;28:1162.
6. Kyllonen L, Pukkala E, Eklund B. Cancer incidence in a kidney-transplanted population. *Transpl Int*. 1994;7 Suppl 1:S350-2.
7. Bakr MA, Sobh M, el-Agroudy A, et al. Study of malignancy among Egyptian kidney transplant recipients. *Transplant Proc*. 1997;29:3067-70.
8. Ecdar ST, Sever MS, Yildiz A, et al. Kaposi's sarcoma after renal transplantation in Turkey. *Clin Transplant*. 1998;12:472-5.
9. Haberal M, Karakayali H, Emiroglu R, Basaran O, Moray G, Bilgin N. Malignant tumors after renal transplantation. *Artif Organs*. 2002 ;26:778-81.
10. Lessan-Pezeshki M, Einollahi B, Khatami MR, Mahdavi M. Kidney transplantation and Kaposi's sarcoma: review of 2050 recipients. *Transplant Proc*. 2001;33:2818.
11. Einollahi B, Noorbala MM, Lessan Pezeshki M, et al. Incidence of postrenal transplantation malignancies: a report of two centers in Tehran, Iran. *Transplant Proc*. 2001;33:2812.
12. Nafar M, Einollahi B, Hemati K, Gholi FP, Firouzan A. Development of malignancy following living donor kidney transplantation. *Transplant Proc*. 2005;37:3065-7.
13. Frances C. Kaposi's sarcoma after renal transplantation. *Nephrol Dial Transplant*. 1998;13:2768-73.

14. Euvrard S, Kanitakis J, Claudy A. Skin cancers after organ transplantation. *N Engl J Med*. 2003;348:1681-91.
15. Marcen R, Pascual J, Tato AM, et al. Influence of immunosuppression on the prevalence of cancer after kidney transplantation. *Transplant Proc*. 2003;35:1714-6.
16. Stefoni S, Scolari MP, Sestigiani E, et al. Renal transplantation and malignancies: A single-centre experience (25 years). *G Ital Nefrol*. 2002;19:650-7.
17. Pedotti P, Cardillo M, Rossini G, et al. Incidence of cancer after kidney transplant: results from the North Italy transplant program. *Transplantation*. 2003;76:1448-51.
18. Zavos G, Bokos J, Papaconstantinou J, Boletis J, Gazouli M, Pappas P, Kostakis A. Study of "de novo" malignancies among greek renal transplant recipients. *Transplant Proc*. 2003;35:1399-403.
19. Antman K, Chang Y. Kaposi's sarcoma. *N Engl J Med*. 2000;342:1027-38.
20. Qunibi WY, Barri Y, Alfurayh O, Almeshari K, Khan B, Taher S, Sheth K. Kaposi's sarcoma in renal transplant recipients: a report on 26 cases from a single institution. *Transplant Proc*. 1993;25:1402-5.
21. Akhtar M, Bunuan H, Ali MA, Godwin JT. Kaposi's sarcoma in renal transplant recipients. Ultrastructural and immunoperoxidase study of four cases. *Cancer*. 1984;53:258-66.
22. Thiagarajan CM, Divakar D, Thomas SJ. Malignancies in renal transplant recipients. *Transplant Proc*. 1998;30:3154-5.
23. Samhan M, al-Mousawi M, Nampoory MR, Muzairai I, Costandi JN. Malignancy in renal recipients. *Transplant Proc*. 1999;31:3233-5.
24. Moosa MR, Walele AA, Daar AS. Renal transplantation in developing countries. In: Morris PJ, editor. *Kidney transplantation, principles and practice*. 5th ed. Philadelphia: WB Saunders; 2001. p. 659-92.
25. Harwood AR, Osoba D, Hofstader SL, et al. Kaposi's sarcoma in recipients of renal transplants. *Am J Med*. 1979;67:759-65.
26. Penn I. The occurrence of malignant tumors in immunosuppressed states. *Prog Allergy*. 1986;37:259-300.
27. Montagnino G, Bencini PL, Tarantino A, Caputo R, Ponticelli C. Clinical features and course of Kaposi's sarcoma in kidney transplant patients: report of 13 cases. *Am J Nephrol*. 1994;14:121-6.
28. Oettle AG. Geographical and racial differences in the frequency of Kaposi's sarcoma as evidence of environmental or genetic causes. *Acta Un Int Cancer*. 1962;18:330-63.
29. Qunibi W, Akhtar M, Sheth K, Ginn HE, Al-Furayh O, DeVol EB, Taher S. Kaposi's sarcoma: the most common tumor after renal transplantation in Saudi Arabia. *Am J Med*. 1988;84:225-32.
30. Cattani P, Capuano M, Cerimele F, et al. Human herpesvirus 8 seroprevalence and evaluation of nonsexual transmission routes by detection of DNA in clinical specimens from human immunodeficiency virus-seronegative patients from central and southern Italy, with and without Kaposi's sarcoma. *J Clin Microbiol*. 1999;37:1150-3.
31. Kedes DH, Ganem D, Ameli N, Bacchetti P, Greenblatt R. The prevalence of serum antibody to human herpesvirus 8 (Kaposi sarcoma-associated herpesvirus) among HIV-seropositive and high-risk HIV-seronegative women. *JAMA*. 1997;277:478-81.
32. Gao SJ, Kingsley L, Li M, et al. KSHV antibodies among Americans, Italians and Ugandans with and without Kaposi's sarcoma. *Nat Med*. 1996;2:925-8.
33. Davis DA, Humphrey RW, Newcomb FM, et al. Detection of serum antibodies to a Kaposi's sarcoma-associated herpesvirus-specific peptide. *J Infect Dis*. 1997;175:1071-9.
34. Simpson GR, Schulz TF, Whitby D, et al. Prevalence of Kaposi's sarcoma associated herpesvirus infection measured by antibodies to recombinant capsid protein and latent immunofluorescence antigen. *Lancet*. 1996;348:1133-8.
35. Lennette ET, Blackbourn DJ, Levy JA. Antibodies to human herpesvirus type 8 in the general population and in Kaposi's sarcoma patients. *Lancet*. 1996;348:858-61.
36. Sitas F, Carrara H, Beral V, et al. Antibodies against human herpesvirus 8 in black South African patients with cancer. *N Engl J Med*. 1999;340:1863-71.
37. Wojcicki JM, Newton R, Urban MI, et al. Risk factors for high anti-HHV-8 antibody titers (> or =1:51,200) in black, HIV-1 negative South African cancer patients: a case control study. *BMC Infect Dis*. 2003;3:21.
38. Stein L, Carrara H, Norman R, Alagiozoglou L, Morris L, Sitas F. Antibodies against human herpesvirus 8 in South African renal transplant recipients and blood donors. *Transpl Infect Dis*. 2004;6:69-73.
39. al-Suleiman M, Haleen A, al Khader A. Kaposi's sarcoma after renal transplantation. *Transplant Proc*. 1987;19:2243-4.
40. Szende B, Toth A, Perner F, Nagy K, Takacs K. Clinicopathologic aspects of 8 Kaposi's sarcomas among 1009 renal transplant patients. *Gen Diagn Pathol*. 1997;143:209-13.
41. Penn I. Kaposi's sarcoma in organ transplant recipients: report of 20 cases. *Transplantation*. 1979;27:8-11.
42. Gotti E, Remuzzi G. Post-transplant Kaposi's sarcoma. *J Am Soc Nephrol*. 1997;8:130-7.
43. al-Sulaiman MH, al-Khader AA. Kaposi's sarcoma in renal transplant recipients. *Transplant Sci*. 1994 Sep;4(1):46-60.
44. Shaheen FA, al-Sulaiman MH, Ramprasad KS, al-Khader AA. Kaposi's sarcoma in renal transplant recipients. *Ann Transplant*. 1997;2:49-58.
45. Moosa MR. Kaposi's sarcoma in kidney transplant recipients: a 23-year experience. *QJM*. 2005;98:205-14.
46. International Agency for Research on Cancer (IARC). Epstein-Barr virus and Kaposi's sarcoma herpesvirus/human herpesvirus 8. Lyon (France): IARC; 1997. p. 375-494.
47. Kapelushnik J, Ariad S, Benharroch D, et al. Post renal transplantation human herpesvirus 8-associated lymphoproliferative disorder and Kaposi's sarcoma. *Br J Haematol*. 2001;113:425-8.



48. Soulier J, Grollet L, Oksenhendler E, et al. Kaposi's sarcoma-associated herpesvirus-like DNA sequences in multicentric Castleman's disease. *Blood*. 1995;86:1276-80.
49. Cesarman E, Chang Y, Moore PS, Said JW, Knowles DM. Kaposi's sarcoma-associated herpesvirus-like DNA sequences in AIDS-related body-cavity-based lymphomas. *N Engl J Med*. 1995;332:1186-91.
50. Martin JN, Ganem DE, Osmond DH, Page-Shafer KA, Macrae D, Kedes DH. Sexual transmission and the natural history of human herpesvirus 8 infection. *N Engl J Med*. 1998;338:948-54.
51. Gessain A, Maucleire P, van Beveren M, Plancoulaine S, Ayoub A, Essame-Oyono JL, Martin PM, de The G. Human herpesvirus 8 primary infection occurs during childhood in Cameroon, Central Africa. *Int J Cancer*. 1999;81:189-92.
52. Bourbouli D, Whitby D, Boshoff C, et al. Serologic evidence for mother-to-child transmission of Kaposi sarcoma-associated herpesvirus infection. *JAMA*. 1998;280:31-2.
53. Andreoni M, El-Sawaf G, Rezza G, et al. High seroprevalence of antibodies to human herpesvirus-8 in Egyptian children: evidence of nonsexual transmission. *J Natl Cancer Inst*. 1999 Mar 3;91(5):465-9.
54. Dodd RY. Human herpesvirus-8: what (not) to do? *Transfusion*. 2005;45:463-5.
55. Hladik W, Dollard SC, Mermin J, et al. Transmission of human herpesvirus 8 by blood transfusion. *N Engl J Med*. 2006;355:1331-8.
56. Dollard SC, Nelson KE, Ness PM, et al. Possible transmission of human herpesvirus-8 by blood transfusion in a historical United States cohort. *Transfusion*. 2005;45:500-3.
57. Moore PS, Gao SJ, Dominguez G, et al. Primary characterization of a herpesvirus agent associated with Kaposi's sarcoma. *J Virol*. 1996;70:549-58.
58. Hayward GS. KSHV strains: the origins and global spread of the virus. *Semin Cancer Biol*. 1999;9:187-99.
59. Russo JJ, Bohenzky RA, Chien MC, et al. Nucleotide sequence of the Kaposi sarcoma-associated herpesvirus (HHV-8). *Proc Natl Acad Sci U S A* 1996;93:14862-7.
60. Flore O, Rafii S, Ely S, O'Leary JJ, Hyjek EM, Cesarman E. Transformation of primary human endothelial cells by Kaposi's sarcoma-associated herpesvirus. *Nature*. 1998;394:588-92.
61. Radkov SA, Kellam P, Boshoff C. The latent nuclear antigen of Kaposi sarcoma-associated herpesvirus targets the retinoblastoma-E2F pathway and with the oncogene Hras transforms primary rat cells. *Nat Med*. 2000;6:1121-7.
62. Lundquist A, Barre B, Bienvu F, Hermann J, Avril S, Coqueret O. Kaposi sarcoma-associated viral cyclin K overrides cell growth inhibition mediated by oncostatin M through STAT3 inhibition. *Blood*. 2003;101:4070-7.
63. Nakamura H, Li M, Zarycki J, Jung JU. Inhibition of p53 tumor suppressor by viral interferon regulatory factor. *J Virol*. 2001;75:7572-82.
64. Chatterjee M, Osborne J, Bestetti G, Chang Y, Moore PS. Viral IL-6-induced cell proliferation and immune evasion of interferon activity. *Science*. 2002;298:1432-5.
65. Schwarz M, Murphy PM. Kaposi's sarcoma-associated herpesvirus G protein-coupled receptor constitutively activates NF-kappa B and induces proinflammatory cytokine and chemokine production via a C-terminal signaling determinant. *J Immunol*. 2001;167:505-13.
66. Pati S, Cavrois M, Guo HG, et al. Activation of NF-kappaB by the human herpesvirus 8 chemokine receptor ORF74: evidence for a paracrine model of Kaposi's sarcoma pathogenesis. *J Virol*. 2001;75:8660-73.
67. Wang HW, Trotter MW, Lagos D, et al. Kaposi sarcoma herpesvirus-induced cellular reprogramming contributes to the lymphatic endothelial gene expression in Kaposi sarcoma. *Nat Genet*. 2004;36:687-93.
68. Moore PS, Boshoff C, Weiss RA, Chang Y. Molecular mimicry of human cytokine and cytokine response pathway genes by KSHV. *Science*. 1996;274:1739-44.
69. Stine JT, Wood C, Hill M, et al. KSHV-encoded CC chemokine vMIP-III is a CCR4 agonist, stimulates angiogenesis, and selectively chemoattracts TH2 cells. *Blood*. 2000;95:1151-7.
70. Mayama S, Cuevas LE, Sheldon J, et al. Prevalence and transmission of Kaposi's sarcoma-associated herpesvirus (human herpesvirus 8) in Ugandan children and adolescents. *Int J Cancer*. 1998;77:817-20.
71. Firoozan A, Hosseini Moghaddam SM, Einollahi B, Pour-Reza-Gholi F, Nafar M, Basiri A, Ebrahimi-Rad R. Outcome of Kaposi's sarcoma and graft following discontinuation of immunosuppressive drugs in renal transplant recipients. *Transplant Proc*. 2005;37:3061-4.
72. Shepherd FA, Maher E, Cardella C, Cole E, Greig P, Wade JA, Levy G. Treatment of Kaposi's sarcoma after solid organ transplantation. *J Clin Oncol*. 1997;15:2371-7.
73. Hojo M, Morimoto T, Maluccio M, et al. Cyclosporine induces cancer progression by a cell-autonomous mechanism. *Nature*. 1999;397:530-4.
74. Trattner A, Hodak E, David M, Sandbank M. The appearance of Kaposi sarcoma during corticosteroid therapy. *Cancer*. 1993;72:1779-83.
75. Guo WX, Antakly T, Cadotte M, Kachra Z, Kunkel L, Masood R, Gill P. Expression and cytokine regulation of glucocorticoid receptors in Kaposi's sarcoma. *Am J Pathol*. 1996;148:1999-2008.
76. Bruet A, Mahe A, Sei JF, et al. Kaposi's sarcoma complicating long-term corticotherapy for severe asthma. *Rev Med Interne*. 1990;11:322-4.
77. Magnone M, Holley JL, Shapiro R, et al. Interferon-alpha-induced acute renal allograft rejection. *Transplantation*. 1995;59:1068-70.
78. Luppi M, Barozzi P, Rasini V, et al. Severe pancytopenia and hemophagocytosis after HHV-8 primary infection in a renal transplant patient successfully treated with foscarnet. *Transplantation*. 2002;74:131-2.
79. Corbellino M, Bestetti G, Scalapogna C, et al. Long-term remission of Kaposi sarcoma-associated herpesvirus-related multicentric Castleman disease with anti-CD20 monoclonal antibody therapy. *Blood*. 2001;98:3473-5.
80. Bisacchi D, Noonan DM, Carlone S, Albini A, Pfeffer U. Kaposi's sarcoma and human chorionic gonadotropin: mechanisms, moieties and mysteries. *Biol Chem*. 2002;383:1315-20.

81. Hussein MM, Mooij JM, Roujouleh HM. Regression of post-transplant Kaposi sarcoma after discontinuing cyclosporin and giving mycophenolate mofetil instead. *Nephrol Dial Transplant*. 2000;15:1103-4.
82. Stallone G, Schena A, Infante B, et al. Sirolimus for Kaposi's sarcoma in renal-transplant recipients. *N Engl J Med*. 2005;352:1317-23.
83. Volkow P, Zinser JW, Correa-Rotter R. Molecularly targeted therapy for Kaposi's sarcoma in a kidney transplant patient: case report, "what worked and what did not". *BMC Nephrol*. 2007;8:6.
84. Sodhi A, Chaisuparat R, Hu J, et al. The TSC2/mTOR pathway drives endothelial cell transformation induced by the Kaposi's sarcoma-associated herpesvirus G protein-coupled receptor. *Cancer Cell*. 2006;10:133-43.
85. Campistol JM, Gutierrez-Dalmau A, Torregrosa JV. Conversion to sirolimus: a successful treatment for posttransplantation Kaposi's sarcoma. *Transplantation*. 2004;77:760-2.
86. Zmonarski SC, Boratynska M, Rabczynski J, Kazimierzak K, Klinger M. Regression of Kaposi's sarcoma in renal graft recipients after conversion to sirolimus treatment. *Transplant Proc*. 2005;37:964-6.
87. Mohsin N, Budruddin M, Pakkyara A, et al. Complete regression of visceral Kaposi's sarcoma after conversion to sirolimus. *Exp Clin Transplant*. 2005;3:366-9.
88. Yilmaz R, Akoglu H, Kirkpantur A, et al. A novel immunosuppressive agent, sirolimus, in the treatment of Kaposi's sarcoma in a rural transplant recipient. *Ren Fail*. 2007;29:103-105.
89. Lebbe C, Euvrard S, Barrou B, et al. Sirolimus conversion for patients with posttransplant Kaposi's sarcoma. *Am J Transplant*. 2006;6:2164-8.
90. Montaner S. Akt/TSC/mTOR activation by the KSHV G protein-coupled receptor: emerging insights into the molecular oncogenesis and treatment of Kaposi's sarcoma. *Cell Cycle*. 2007;6:438-43.
91. Koon HB, Bublely GJ, Pantanowitz L, et al. Imatinib-induced regression of AIDS-related Kaposi's sarcoma. *J Clin Oncol*. 2005;23:982-9.
92. Quintas-Cardama A, Kantarjian H, O'Brien S, et al. Granulocyte-colony-stimulating factor (filgrastim) may overcome imatinib-induced neutropenia in patients with chronic-phase chronic myelogenous leukemia. *Cancer*. 2004;100:2592-7.
93. Kedes DH, Ganem D. Sensitivity of Kaposi's sarcoma-associated herpesvirus replication to antiviral drugs. Implications for potential therapy. *J Clin Invest*. 1997;99:2082-6.
94. Neyts J, De Clercq E. Antiviral drug susceptibility of human herpesvirus 8. *Antimicrob Agents Chemother*. 1997;41:2754-6.

Correspondence to:  
 Behzad Einollahi, MD  
 Department of Nephrology, Nephrology and Urology Research  
 Center, Baqiyatallah Hospital, Mollasadra Ave, Vanak Sq,  
 Tehran, Iran  
 Tel: +98 21 8803 7667  
 Fax: +98 21 8803 7673  
 E-mail: einollahi@bmsu.ac.ir

Received March 2007  
 Revised June 2007