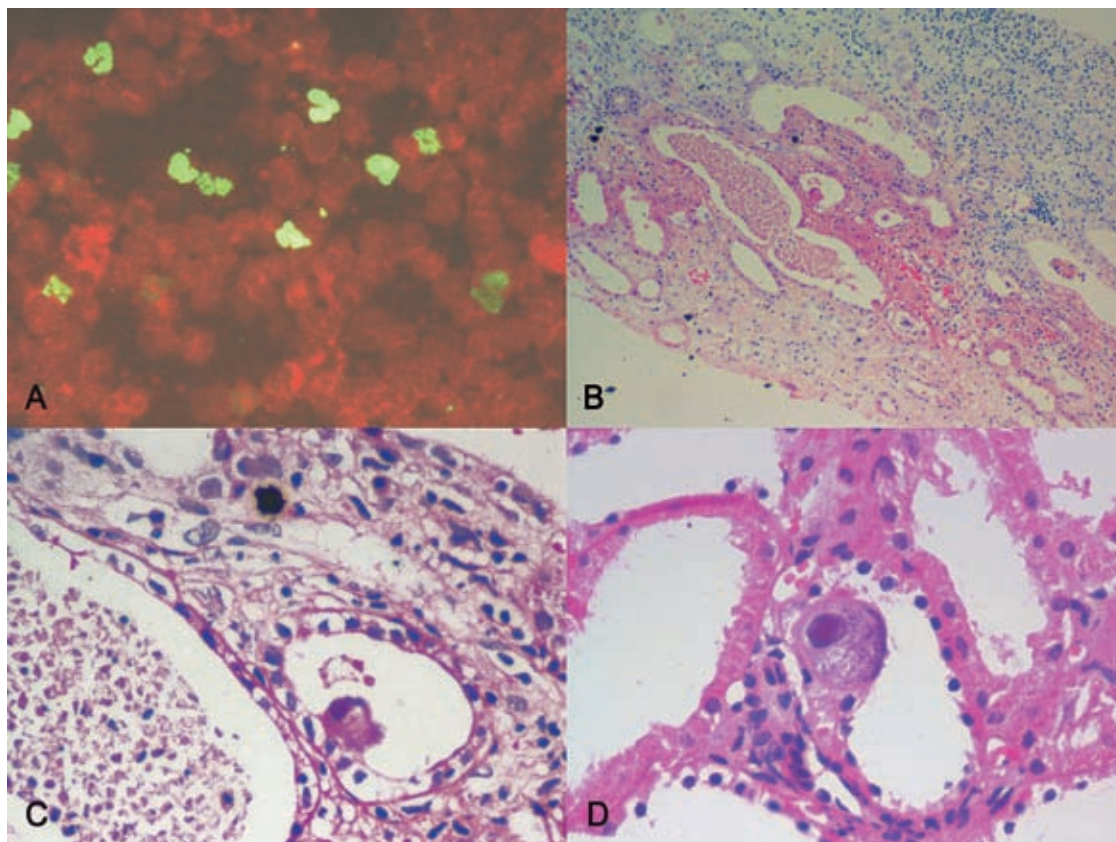


Cytomegalovirus-Related Tubulointerstitial Nephritis in a Kidney Allograft

IJKD 2009;3:11
www.ijkd.org



A 20-year-old man presented with elevated serum creatinine level 3 months after kidney transplantation. Cytomegalovirus (CMV) pp65 antigen was detected by indirect immunofluorescent method. Figure A shows contaminated cells in phosphorous green ($\times 400$). Kidney needle biopsy was performed and tubulointerstitial nephritis with CMV cytopathic effects was observed on pathologic examination. No obvious evidence of active rejection was seen. The specimens stained by hematoxylin-eosin revealed typical features of CMV-related tubulointerstitial nephritis with casts (Figure B, $\times 100$; Figure C, $\times 200$). Figure D shows CMV inclusions in the tubular epithelia cells ($\times 400$).

Mahmoud Parvin

Department of Pathology, Shahid Labbafinejd Medical Center,
Shahid Beheshti University (MC), Tehran, Iran
E-mail: mahmoudparvin@yahoo.com