

Psoriasis in a Patient on Peritoneal Dialysis

A Two-sided Mirror

Laurynas Rimsevicius,^{1,2} Diana Sukackiene,^{1,2} Giedre Tamulyte,¹ Greta Kirkilaite,¹ Marius Miglinas^{1,2}

¹Faculty of Medicine, Vilnius University, Vilnius, Lithuania
²Nephrology Center, Vilnius University Hospital Santariskiu Klinikos, Vilnius, Lithuania

Keywords. peritoneal dialysis, hemodialysis, psoriasis

Psoriasis vulgaris is not frequently seen in patients with renal replacement therapy, especially in patients on peritoneal dialysis. Dialysis also has been reported to improve psoriatic skin lesions with a much higher response rate for peritoneal dialysis than haemodialysis. Conversely, we present a case of a man who developed psoriasis after 16 months of peritoneal dialysis. Discontinuation of icodextrin as a possible factor provoking systemic inflammation had no impact on the course of the disease. In this report, we review the existing studies and counsel caution against optimistic expectations of benefits from dialysis in patients with psoriasis.

IJKD 2017;11:70-3
www.ijkd.org

INTRODUCTION

Psoriasis vulgaris is not frequently seen in patients with renal replacement therapy. A few small-sample studies decades ago reported improvement of psoriatic skin lesions in patients on peritoneal dialysis (PD) or hemodialysis.¹⁻⁶ Conversely, we present a clinical case with newly developed psoriasis during PD. To our knowledge, there has been only 1 similar case of new-onset psoriasis during PD published in 2014 by Geerse and colleagues,⁷ and a few cases of psoriasis development during hemodialysis, mostly coming from the 1980s.⁸⁻¹¹

CASE REPORT

A 52-year-old man was on predialysis program since 2008 due to malignant hypertension and progressive chronic kidney disease. A Tenckhoff catheter was inserted in January 2014 and automated PD was initiated. The initial prescription consisted of 10-L overnight cycler with 5 exchanges over 9 hours. Later, long icodextrin dwell was added due to edematous state. The patient was twice temporary switched to hemodialysis due to surgical treatment of inguinal and recurrent umbilical hernias. After the surgeries, he carried on nocturnal intermittent PD with irregular use of icodextrin and high-percentage glucose solution during the daytime. In May 2015,

the patient started to complain of skin dryness and newly originated itchy, squamous plaques on his hairy part of the scalp skin (Figure 1), on his back, and in external ear canal. The exit site of PD catheter was involved by Koebner phenomenon due to persistent traumatization (Figure 2).

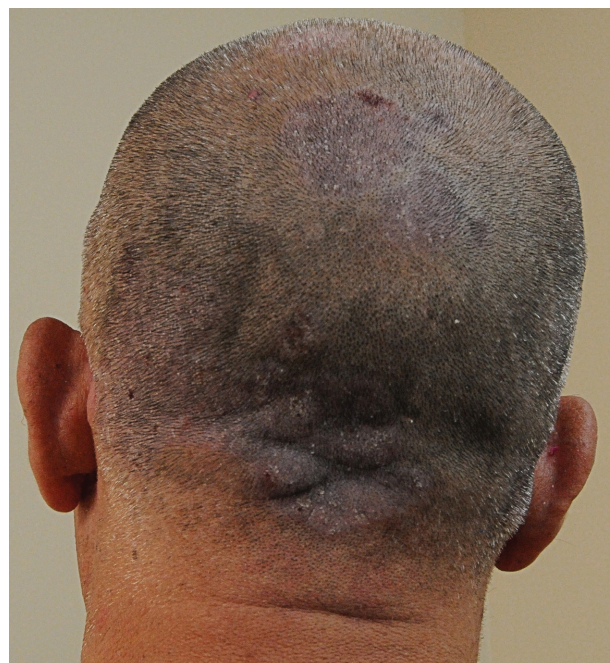

Figure 1. Newly originated itchy squamous plaques on the hairy part of the scalp skin.

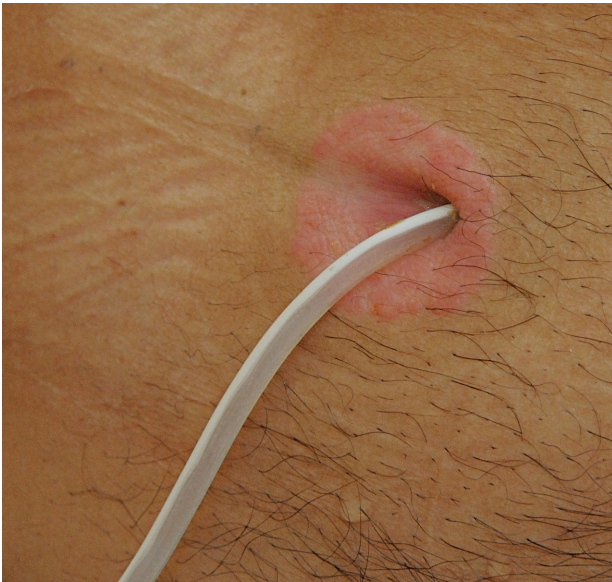


Figure 2. Koebner phenomenon at the exit site of peritoneal catheter due to persistent traumatization.

The patient had no past history of psoriasis or newly prescribed medication. We discontinued icodextrin as a potential trigger for a period of 2 months; however, there was no improvement. Slight improvement in skin lesions was noted after administering emollients and topical corticosteroids. After this improvement, the patient had his first 3 episodes of PD-associated peritonitis.

DISCUSSION

It is known that dialysis can lead to various skin lesions or worsen them.¹²⁻¹⁴ However, psoriasis is quite rare between patients on hemodialysis with a prevalence of 2.7%.¹⁵ In recent literature, we found 5 cases of hemodialysis patients with new-onset psoriasis. Breathnach and colleagues published a report about a patient treated for 4 years with hemodialysis; Levy and Clutterbuck reported recurrent psoriasis over the needling sites along fistula after 3 hemodialysis sessions in a patient with antineutrophil cytoplasmic antibody vasculitis; Yamamoto and coworkers reported 2 patients with end-stage renal disease; Triga and coworkers published a clinical case of end-stage renal disease due to polycystic kidney disease treated with hemodialysis for 5 years.⁸⁻¹¹ Manifestation of psoriasis on PD seems to be even less prevalent.

Several authors had previously reported beneficial effects of dialysis, in particular, with

much higher response rate for PD than hemodialysis, on clearing of psoriatic lesion. These publications are demonstrated in the Table. Majority of reports presents positive effects on psoriatic skin lesions of relatively short-term (up to 12 months) or intermittent dialysis.²⁻⁴ In our case, psoriatic skin changes evolved after treatment with PD for 16 months. Furthermore, reported new-onset psoriasis during hemodialysis generally presents after several months or even years of dialysis.^{7,8,10,16-17}

Another possible hypothesis for psoriasis development is related to pathogenesis of this disease. Chronic systemic inflammation is provoked by systemic disorders such as cardiovascular diseases, diabetes mellitus, and chronic kidney disease. Additionally, the interaction between blood and dialytic membranes provokes secretion of interleukins and other factors that induce systemic inflammation.¹⁷ This immunological activity plays an important role in development of psoriasis. Dysregulation of T helper 1/T helper 2 response and cytokines, such as tumor necrosis factor- α levels, is conditioned by both hemodialysis and PD and depends on duration of treatment.¹⁸ In addition, several authors reported increased levels of interleukin-6 and tumor necrosis factor- α in the effluents of patients receiving PD with icodextrin, suggesting enhanced (peritoneal) inflammatory response.^{19,20} Conversely, use of glucose and lactate-buffered solution released lower concentrations of interleukin-6 and tumor necrosis factor- α .²¹ In our case, discontinuation of icodextrin had no impact to psoriasis lesions.

Peritoneal catheter exit-site care was of a big importance in our patient, as it was involved by Koebner phenomenon. The lesion improved with topical treatment. Possibly it can promote higher exit-site or tunnel infection and increase the risk for peritonitis. Exit-site lesion is not a typical indication for catheter removal. However, this patient had 3 episodes of peritonitis, and we considered to replace his PD catheter through a new tunnel.

We would expect the patient to recover from his skin lesions soon, as he was waitlisted as a candidate for kidney transplantation and would be on calcineurin inhibitor. Therefore, we counsel caution against optimistic expectations of benefits from dialysis in patients with psoriasis. There is a need to revise epidemiology of psoriasis in patients with end-stage renal disease.

Publications of Psoriasis Treatment With Dialysis

Study	Number of Patients	Kidney Disease Stage	Type of Dialysis	Duration of Dialysis	Positive Effect on Psoriasis	Outcome
McEvoy and Kelly (1976) ⁵	1	End stage	Hemodialysis	12 months	1/1	Improvement after 3 dialysis sessions
Buselmeier et al (1978) ²³	5	3	Hemodialysis	Various	4/5	3 patients had kidney transplants without recurrence of psoriasis; 1 patient, moderate improvements after 2 months of twice-weekly hemodialysis; 1 patient, no improvement after single hemodialysis.
Nissenson et al (1979) ²⁴	7	None	Sham or true hemodialysis	...	Subjective 7/7	No objective improvement at any time.
Whittier et al (1983) ⁴	5	None	Sham or true peritoneal dialysis	4 weeks	4/5	2 patients completely cleared, 2 patients had greater than 75% clearing, 1 patient had no substantial response.
Sobh et al (1987) ²	40	None	Randomly distributed hemodialysis, peritoneal dialysis, or modified Goeckermans treatment	10 dialysis sessions	Peritoneal dialysis > hemodialysis > Goeckermans treatment	Degree of improvement differed insignificantly, duration of remission differed significantly.
Kuruville et al (1998) ³	20	None	10 on hemodialysis, 10 on peritoneal dialysis	6 months	4/8 on hemodialysis 6/10 on peritoneal dialysis	Temporary effect
Thomas et al (2005) ⁶	1	End stage	Hemodialysis	3 months	1/1	Improvement after 2 weeks

CONFLICTS OF INTEREST

None declared.

REFERENCES

- Menter A, Korman NJ, Elmets CA, et al. Guidelines of care for the management of psoriasis and psoriatic arthritis. Section 3. Guidelines of care for the management and treatment of psoriasis with topical therapies. *J Am Acad Dermatol.* 2009;60:643-59.
- Sobh MA, Abdel Rasik MM, Moustafa FE, el-Sharabasy MM, Rezk RA, el-Shamy SI. Dialysis therapy of severe psoriasis: a random study of forty cases. *Nephrol Dial Transplant.* 1987;2:351-8.
- Kuruville M, Mathew T, Sugathan P, Nair LV. Effect of dialysis on psoriasis : A clinical study. *Indian J Dermatol Venereol Leprol.* 1998;64:146-9.
- Whittier FC, Evans DH, Anderson PC, Nolph KD. Peritoneal dialysis for psoriasis: a controlled study. *Ann Intern Med.* 1983;99:165-8.
- McEvoy J, Kelly AM. Psoriatic clearance during haemodialysis. *Ulster Med J.* 1976;45:76-8.
- Thomas EA, Pawar B, Sadiq S. Effect of HD on psoriasis. *Indian J Nephrol.* 2005;15:101-2.
- Geerse DA, Suijkerbuijk J, van Poppelen KM, Litjens EJ, Cornelis T. New-onset psoriasis during peritoneal dialysis. *Perit Dial Int.* 2014;34:802-3.
- Triga K, Dousdampanis P, Aggelakou-Vaitis S, Gellner K. New-onset psoriasis in a maintenance hemodialysis patient. *Hemodial Int.* 2012;16:109-12.
- Breathnach SM, Boon NA, Black MM, Jones NF, Wing AJ. Psoriasis developing during dialysis. *Br Med J.* 1979;1:236.
- Levy JB, Clutterbuck EJ. Images in nephrology. Recurrence of psoriasis in an arteriovenous fistula. *Nephrol Dial Transplant.* 1999;14:2738-9.
- Yamamoto T, Yokozeki H, Nishioka K. Psoriasis under haemodialysis. *J Eur Acad Dermatol Venereol.* 2006;20:1139-40.
- Avermaete A, Altmeyer P, Bacharach-Buhles M. Skin changes in dialysis patients: a review. *Nephrol Dial Transplant.* 2001;16:2293-6.
- Altmeyer P, Kachel HG, Junger M, Koch KM, Holzmann H. [Skin changes in long-term dialysis patients. clinical study]. *Hautarzt.* 1982;33:303-9.
- Murphy M, Carmichael AJ. Renal itch. *Clin Exp Dermatol.* 2000;25:103-6.
- Kolla PK, Desai M, Pathapati RM, et al. Cutaneous manifestations in patients with chronic kidney disease on maintenance hemodialysis. *ISRN Dermatol.* 2012;2012:679619.
- Saougou I, Papagoras C, Markatseli TE, Voulgari PV, Drosos AA. A case report of a psoriatic arthritis patient on hemodialysis treated with tumor necrosis factor blocking agent and a literature review. *Clin Rheumatol.* 2010;29:1455-9.

17. Pertosa G, Grandaliano G, Gesualdo L, Schena FP. Clinical relevance of cytokine production in hemodialysis. *Kidney Int Suppl.* 2000;76:S104-S111.
18. Maksic D, Colic M, Stankovic-Popovic V, Radojevic M, Bokonjic D. Systemic and intraperitoneal proinflammatory cytokines profiles in patients on chronic peritoneal dialysis. *Med Pregl.* 2007;60 Suppl 2:53-7.
19. Moriishi M, Kawanishi H. Icodextrin and intraperitoneal inflammation. *Perit Dial Int.* 2008;28 Suppl 3:S96-S100.
20. Plum J, Lordnejad MR, Grabensee B. Effect of alternative peritoneal dialysis solutions on cell viability, apoptosis/necrosis and cytokine expression in human monocytes. *Kidney Int.* 1998;54:224-35.
21. Libetta C, Esposito P, Sepe V, et al. Effects of different peritoneal dialysis fluids on the TH1/TH2 balance. *Eur Cytokine Netw.* 2011;22:24-31.
22. Mele C, Salerno MP, Romagnoli J, De SC, Castriota M, Citterio F. Complete clinical remission of psoriasis 6 months after renal transplantation. *Transplant Proc.* 2013;45:2788-9.
23. Buselmeier TJ, Kjellstrand CM, Dahl MV, et al. Treatment of psoriasis with dialysis. *Proc Eur Dial Transplant Assoc.* 1978;15:171-7.
24. Nissenson AR, Rapaport M, Gordon A, Narins RG. Hemodialysis in the treatment of psoriasis. A controlled trial. *Ann Intern Med.* 1979;91:218-20.

Correspondence to:
Laurynas Rimsevicius, MD PhD
Nephrology Center, Vilnius University hospital Santariskiu
klinikos
Santariskiu Street 2, Vilnius LT-08661, Lithuania
Tel.: +370 5 2365 282
E-mail: laurynas.rimsevicius@gmail.com

Received April 2016
Accepted September 2016