

Glomerulonephritis as a Type of Kidney Injury in Multiple Myeloma

A Report of 2 Cases

Mohsen Vakili Sadeghi,¹ Roghaeh Akbari²

¹Department of Internal Medicine, Clinical Research Development Unit of Rouhani Hospital, Babol University of Medical Sciences, Babol, Iran

²Department of Internal Medicine, Transplant Center of Shahid Beheshti Hospital, Clinical Research Development Unit of Rouhani Hospital, Babol University of Medical Sciences, Babol, Iran

Renal involvement in multiple myeloma has multiple etiologies. Glomerulonephritis rarely occurs in multiple myeloma and numerous case reports in the literature explain their correlation. We report 2 cases of glomerulonephritis, one membranous glomerulonephritis and the other focal segmental glomerulosclerosis, in which multiple myeloma was confirmed after several months in the first case and synchronous with the second. Glomerulonephritis can be an uncommon, but not rare, cause of proteinuria in multiple myeloma.

IJKD 2017;11:249-52
www.ijkd.org

Keywords. focal segmental glomerulosclerosis, multiple myeloma, membranous glomerulosclerosis

INTRODUCTION

Multiple myeloma (MM) is a type of plasma cell dyscrasia. Renal involvement frequently occurs in this malignancy. Light chain deposition disease, cast nephropathy, hypercalcaemia, amyloidosis, plasma cell infiltration, and renal damage due to infection and drugs are multiple causes of renal involvement.¹ Glomerulonephritis (GN) is not a usual manifestation in MM, and only case reports in the literature discuss about this problem. We report 2 cases of MM and GN.

CASE REPORT

Case 1

The first patient was a 44-year-old man with lower extremity edema admitted in 2013. The 24-hour urine collection revealed 2900 mg of protein. Histological evaluation of a kidney biopsy revealed idiopathic membranous (GN) and focal tubulointerstitial nephritis (Figure 1).

Workup for secondary causes included antinuclear antibody, antineutrophil cytoplasmic antibody, double-stranded DNA, Wright, 2-mercaptoethanol Brucella agglutination test, and Coombs' Wright were negative. The patient was treated with

prednisolone, cyclosporine, diltiazem, valsartan, and spironolactone. After 1 year, the patient presented with nausea, vomiting, and oliguria. Further evaluation revealed plural effusion and ascites. Serum creatinine level was 15.5 mg/dL. Two weeks prior to admission, hemoglobin level was 8 g/dL, erythrocyte sedimentation rate was 95 mm/h, C-reactive protein was 3+, serum total protein level was 7.5 g/dL, serum albumin level was 3.3 g/dL, and 24-hour urine protein was 3362 mg. Kidney biopsy was repeated, which showed cast nephropathy plus membranous GN. The patient was referred to the hematologist and bone

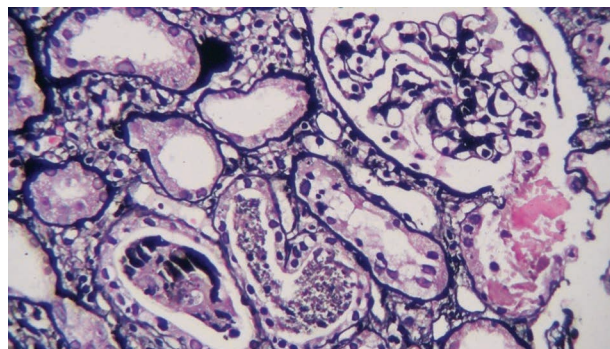


Figure 1. Membranous glomerulonephritis.

marrow biopsy revealed more than 50% of plasma cells in the bone marrow that confirmed multiple myeloma. Serum protein electrophoresis revealed one β_2 and one γ monoclonal spikes. Immunofixation electrophoresis was inaccessible in our center. Serum immunoglobulins G, M, and A levels were decreased to less than normal ranges. Hemodialysis was started and chemotherapy with vincristine, adriamycin, and dexamethasone plus thalidomide was started on. Creatinine level decreased to 2 mg/dL and monoclonal spikes and proteinuria responded after 4 courses of chemotherapy.

Case 2

The second case was a 55-year-old woman with chest wall and pelvic pain, slightly aggravated with movement, in 2011. Chest and pelvic radiographies were normal. Hemoglobin level was 9.8 g/dL, serum calcium level was 10 mg/dL, serum creatinine level was 0.9 mg/dL, erythrocyte sedimentation rate was 12 mm/h, and 24-hour urine showed 1253 mg of protein. Her skull radiography had a few punch-out lesion, and her bone marrow aspiration contained 10% to 15% of plasma cells. The patient went to Tehran and a repeat bone marrow biopsy revealed dysplastic changes and 7% to 8% of plasma cells. The patient was followed up with serial laboratory tests which showed hemoglobin increase to 11.8 g/dL; serum protein electrophoresis result was almost normal several times except once, when a small β_2 -globulin spike was detected. Albumin was 4.8 g/dL and total protein was 8.3 g/dL.

After 1 year, chest wall pain continued and serum albumin, protein, and erythrocyte sedimentation rate were normal. At 14 months, urine protein electrophoresis showed a spike of light chain globulin, serum immunoglobulins M, G, and A levels were lower than normal, and creatinine was 1.1 mg/dL. Serum β_2 -microglobulin level was 5.2 $\mu\text{g/L}$. At 16 months, renal biopsy revealed idiopathic focal segmental glomerulosclerosis (FSGS; Figure 2).

At 18 months, bone marrow biopsy showed more than 30% of plasma cells. At 19 months, fracture of the clavicle occurred and whole body bone scan revealed multiple sites of increased uptake compatible with malignant bone lesions. About 10% of monoclonal gamma band spike was detected in serum protein electrophoresis, and erythrocyte sedimentation rate was 80 mm/h. Treatment with

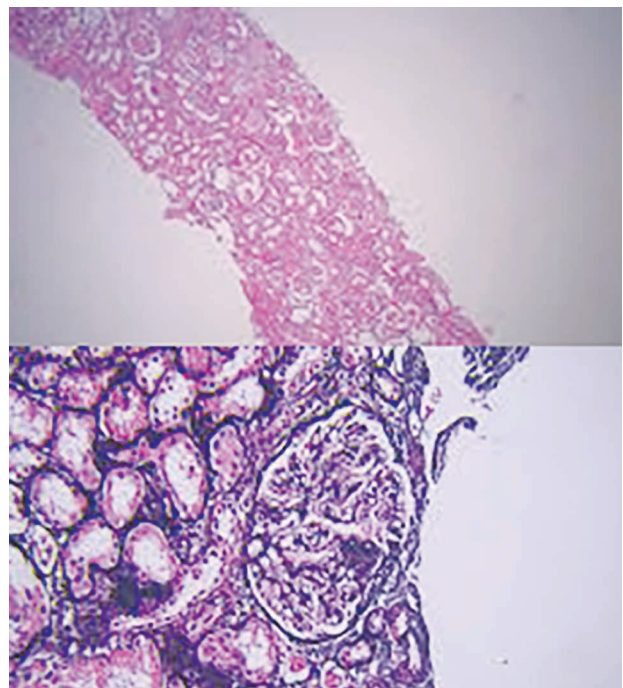


Figure 2. Focal segmental glomerulosclerosis.

thalidomide, bortezomib, and dexamethasone was started, and proteinuria decreased to 300 mg/24 h, erythrocyte sedimentation rate decreased to 30 mm/h, and serum protein electrophoresis was normal after 7 courses of treatment.

DISCUSSION

Proteinuria in MM can be due to light chain proteinuria, which is the most common cause. Light chain is excreted into glomerular tubules, and when the tubular absorptive capacity is exhausted, light chain and Tamm-Horsfall protein result in cast nephropathy.¹ Amyloidosis and toxic interstitial nephritis are other causes. Toxic interstitial nephritis may be due to nonsteroidal anti-inflammatory drugs, toxic antibiotics, and contrast nephropathy.^{1,2}

Pamidronate therapy can result in collapsing FSGS.³ In one case report, zoledronic acid, another bisphosphonate, also caused collapsing FSGS.⁴ Glomerulonephritis is not usual in multiple myeloma.² Glomerulonephritis can occur several months before diagnosis of MM. Sirsat and Deshpande reported a case of proliferative (crescentic) GN in which bone pain occurred after 6 months and MM was diagnosed.⁵ But in more case reports, MM was diagnosed in a patient when evaluated for GN.

Different type of GNs are reported in association with monoclonal gammopathy and MM. Park and coworkers reported a case of fibrillary GN in a known case of MM.⁶ Mcleish and colleagues reported a case with mesangial proliferative GN in a known case of MM.⁷ Some of case reports reported proliferative (crescentic) rapidly progressive GN as the first presentation of MM.^{5,8,9}

Membranoproliferative GN in MM is frequent in case reports in the literature. Sethi and coworkers reviewed renal biopsies of membranoproliferative GN patients at Mayo clinic, which were performed on 106 patients over a period of 6 years. Monoclonal gammopathy in serum or urine was observed in 28 of the patients. Monoclonal gammopathy of uncertain significance was the most common cause, similar to a case series of FSGS. Multiple myeloma, low grade lymphoma, and chronic lymphocytic leukemia were other more common causes.¹⁰

Regarding membranoproliferative GN, only 1 article reported membranous GN in 2 cases of MM, and in one of them, MM was diagnosed 5 years after the first presentation of nephritic syndrome and in the other one, membranoproliferative GN was diagnosed after MM.¹¹

In our first case, despite all other reports, nephritic syndrome was membranous, not membranoproliferative GN that occurred 1 year before MM diagnosis. As to our knowledge, this is the second case report of membranous GN associated with MM.

Finally, FSGS has been reported in association with MM. Shah and colleagues reported a case of primary FSGS and smoldering MM.¹² Based on the Mayo Clinic databases, a case series was published in 2005. Thirteen patients with idiopathic FSGS and a monoclonal plasma cell disorder were evaluated, of whom 9 patients had monoclonal gammopathy of undetermined significance and 4 patients had MM. Treatment of myeloma resulted in a decrease of proteinuria.¹³ This is similar to our second case in which the patient's renal biopsy was idiopathic FSGS and her proteinuria disappeared with MM treatment. Overall, Mayo clinic researchers recommend ruling out a plasma cell dyscrasia in patients with FSGS and membranoproliferative GN.

Glomerulonephritis was also reported in other plasma cell disorders; Crosthwaite and coworkers reported a case of rapidly progressive GN following amyloidosis,¹⁴ and Meyrier and colleagues reported

Waldenstrom macroglobulinemia in a case with proliferative glomerulonephritis.⁹

Sethi and Rajkumar explained pathophysiology of monoclonal gammopathy-induced proliferative GN using 2 mechanisms: (1) "activation of the classical pathway of complement resulting in immunoglobulin-positive C3-positive GN," which is the direct pathway; and (2) deposition of alternative components of complement resulting in only C3 precipitation and immunoglobulin-negative C3-positive GN, which is the indirect pathway.¹⁵

In conclusion, different types of GN can be seen in MM. Membranous GN is a very rare type. We published the second case report of the membranous GN in a patient with MM. Multiple myeloma should be considered as a cause of kidney disease in the patients with idiopathic GN.

ACKNOWLEDGEMENTS

We thank the Clinical Research Development Unit of Rouhani Hospital of Babol.

CONFLICT OF INTEREST

None declared.

REFERENCES

1. Kaushansky K, Williams hematology. 8th ed. P. 109.
2. Leung N, Nasr SH. Myeloma-related kidney disease. *Am J Kidney Dis.* 2014;21:36-47.
3. Markowitz GS, Appel GB, Fine PL, et al. Collapsing focal segmental glomerulosclerosis following treatment with high-dose pamidronate. *J Am Soc Nephrol.* 2001;12:1164-72.
4. Neyra JA, Vaidya OU, Hendricks A, et al. Collapsing focal segmental glomerulosclerosis resulting from a single dose of zoledronate. *Nephron Extra.* 2014;4:168-74.
5. Sirsat RA, Deshpande RB. Multiple myeloma presenting as proliferative (crescentic) glomerulonephritis. *J Postgrad Med.* 1994;40:92-3.
6. Park JH, Kim BR, Chun BG, et al. Coexistence of fibrillary glomerulonephritis in a patient with multiple myeloma. *Intern Med.* 2012;51:1379-81.
7. McLeish KR, Gohara AF, Gillespie C, et al. Mesangial proliferative glomerulonephritis associated with multiple myeloma. *Am J Med Sci.* 1985;290:114-16.
8. Grace T, Moscoso S, Marcus V, et al. Crescentic Glomerulonephritis in IgA Multiple Myeloma: A Case Report. *Nephron Extra.* 2011;1:69-72.
9. Meyrier A, Simon P, Mignon F, et al. Rapidly Progressive ('Crescentic') Glomerulonephritis and Monoclonal Gammopathies. *Nephron.* 1984;38:156-62.
10. Sethi S, Zand L, Leung N, et al. Membranoproliferative glomerulonephritis secondary to monoclonal gammopathy.

- Clin J Am Soc Nephrol. 2010;5:770-82.
11. Thachil J, Sadik W, Shawki H, et al. Membranous glomerulonephritis—an under-reported histological finding in multiple myeloma. *Nephrol Dial Transplant*. 2009;24:1695-6.
 12. Shah R, Shah N, Shah A, et al. Steroid-resistant nephrotic syndrome secondary to primary focal segmental glomerulosclerosis and smoldering multiple myeloma. *Proc Bayl Univ Med Cent*. 2014;27:19-21.
 13. Dingli D, Larson DR, Plevak MF, et al. Focal and segmental glomerulosclerosis and plasma cell proliferative disorders. *Am J Kidney Dis*. 2005;46:278-82.
 14. Crosthwaite A, Skene A. Peter Mount Rapidly progressive glomerulonephritis complicating primary AL amyloidosis and multiple myeloma. *Nephrol Dial Transplant*. 2010;25:2786-9.
 15. Sethi S, Rajkumar SV. Monoclonal gammopathy-associated proliferative glomerulonephritis. *Mayo Clin Proc*. 2013;88:1284-93.

Correspondence to:

Roghaeh Akbari, MD

Department of Internal Medicine, Transplant Center of Shahid Beheshti Hospital, Clinical Research Development Unit of Rouhani Hospital, Ganjafrooz St, Babol, Iran

Tel: +98 911 112 3168

Fax: +98 113 223 8284

E-mail: roghayeh.akbari@yahoo.com

Received April 2016

Revised October 2016

Accepted November 2016