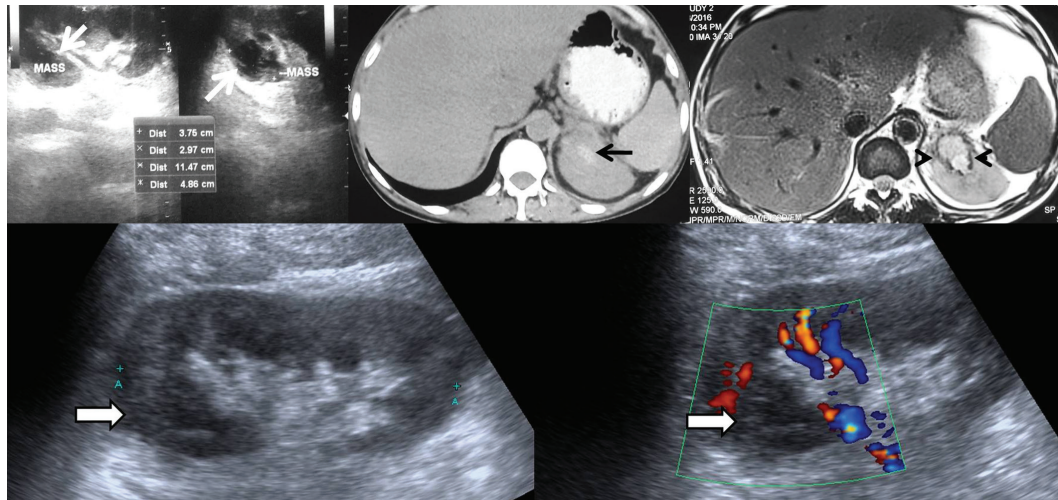


Spontaneous Hemorrhage in a Renal Abscess Mimicking Renal Neoplasm

IJKD 2016;10:176-9
www.ijkl.org



A 41-year-old nondiabetic nonhypertensive man presented with increased frequency of micturition and low-grade fever. He had a history of pulmonary tuberculosis and antitubercular drug therapy. Blood hemoglobin level was 7 g/dL; total leucocyte count, $14.2 \times 10^3/L$; and serum creatinine, 2.62 mg/dL. Leucocytes (25 to 30 per high-power field) and erythrocytes (1 to 2 per high-power field) were noted in urinalysis. Ultrasonography before admission had revealed a complex cystic mass measuring approximately 37×30 mm in the upper pole of the left kidney; noncontrast computed tomography had documented hemorrhage; and magnetic resonance urography had shown peripheral hypointense hemosiderin rim suggestive of chronic hemorrhage. Differentiation between a complex cystic renal cell carcinoma and infective etiology could not be made on the basis of imaging. Repeat ultrasonography (in 2 weeks) after admission revealed 20×22 -mm avascular heteroechoic area in the upper pole of the left kidney, which had significantly reduced in size compared to the previous scan. This was consistent with resolving renal abscess. The patient did well on conservative management.

Spontaneous renal hemorrhage is an unusual and severe complication of urinary tract infection. Causes of spontaneous renal hemorrhage are various, including benign and malignant tumors (angiomyolipoma, adenoma, renal cell carcinoma, metastasis, and sarcoma), vascular lesions (polyarteritis nodosa, aneurysm, infarction, and arteriovenous malformation), infections, and others such as renal cysts and drugs.^{1,2} Tumors account for 50% to 70% of spontaneous renal hemorrhage cases, while infections constitute only 2% of the causes.^{1,2} Hemorrhage in a complex renal lesion can also be seen in renal abscess and only the clinicoradiological correlation and meticulous follow-up is helpful in narrowing down the list of differential diagnoses in these difficult cases.

Binit Sureka,^{1*} Saurabh Jain,² Vikas Jain,² Kalpana Bansal¹

¹Department of Radiology, Institute of Liver and Biliary Sciences, New Delhi, India

²Department of Renal Transplant and Urology, Institute of Liver and Biliary Sciences, New Delhi, India

*E-mail: binitsurekapgi@gmail.com

REFERENCES

1. Zhang JQ, Fielding JR, Zou KH. Etiology of spontaneous perirenal hemorrhage: a meta-analysis. *J Urol.* 2002;167:1593-6.
2. Albi G, del CL, Tagarro D. Wunderlich's syndrome: causes, diagnosis and radiological management. *Clin Radiol.* 2002;57:840-5.