

# Oral Lesions in Kidney Transplant Patients

Mahnaz Sahebamee,<sup>1</sup> Maryam Shakur Shahabi,<sup>2</sup>  
 Mohammad Reza Nikoobakht,<sup>3</sup> Jalil Momen Beitollahi,<sup>1</sup>  
 Arash Mansourian<sup>1</sup>

<sup>1</sup>Department of Oral Medicine,  
 Dental Research Center,  
 Tehran University of Medical  
 Sciences, Tehran, Iran

<sup>2</sup>Tehran University of Medical  
 Sciences, Tehran, Iran

<sup>3</sup>Urology Research Center,  
 Sina Hospital, Tehran University  
 of Medical Sciences, Tehran,  
 Iran

**Keywords.** gingival  
 overgrowth, oral candidiasis,  
 kidney transplantation

**Introduction.** Oral hygiene in kidney transplant recipients contributes to maintenance of the transplanted organ and its function. Thus, an investigation of oral lesions could be counted as a notable work. These patients have the potential to be involved with lesions developed as a result of the administration of immunosuppressive drugs. The aim of this study was to investigate oral lesions in a group of kidney transplant recipients.

**Materials and Methods.** The present study was a cross-sectional research on 100 patients with a kidney transplant for at least 3 months. Oral mucosa was assessed clinically for any lesion. Additional data on systemic diseases, transplant duration, and medications were recorded.

**Results.** Twenty-four percent of the patients had at least 1 oral lesion. The most common lesion was oral candidiasis in 16% of the participants (13 cases of acute pseudomembranous and 3 cases of chronic oral candidiasis). Gingival enlargement was seen in 7% of the kidney transplant recipients, and 2% had a coated tongue.

**Conclusions.** Elimination of oral fungal lesions in kidney transplant recipients is highly recommended. We hope this study can shed light on this particular aspect of healthcare in kidney transplant recipients.

IJKD 2010;4:232-6  
 www.ijkd.org

## INTRODUCTION

Posttransplant healthcare after costly kidney transplantation must be inclusive for maintenance of the allograft and its function. An investigation of oral lesions could be counted as a notable work.<sup>1</sup> To the best knowledge of the authors, no comprehensive report about oral lesions of these patients has been published in Iran.

All kidney transplant recipients undergo immunosuppression that makes them prone to complications, including the development of some oral lesions. Cyclosporine A, prednisolone, mycophenolate mofetil, azathioprine, and tacrolimus are the main prescribed drugs to prevent transplant rejection. Gingival enlargement (GE) in kidney transplant recipients is usually related to the administered drugs, especially cyclosporine.

In combination with calcium channel blockers such as nifedipin, diltiazem, and verapamil, cyclosporine causes intensified GE.<sup>2-7</sup> Gingival enlargement results in esthetic, functional, and phonetic problems.<sup>3</sup> Recent studies<sup>8,9</sup> displayed complete or partial improvement of GE by switching from cyclosporine to tacrolimus in kidney transplant recipients. Depending on the medications they have to use, kidney transplant patients are also susceptible to viral and fungal infections of the oral cavity. Furthermore, infectious complications in immunosuppressed patients increase the risk for development of cancers such as Kaposi sarcoma.<sup>2,10</sup>

The aim of this study was the investigation of oral lesions in a group of kidney transplant recipients in Tehran, Iran.

**MATERIALS AND METHODS**

This cross-sectional study was performed on 100 patients who received a kidney allograft in Sina Hospital of Tehran University of Medical Sciences and were on regular follow-up. The inclusion criteria were having received transplant at least 3 months earlier, a normal kidney allograft function, and a minimum age of 18 years. Informed consent was taken from all the participants, and information on age, gender, transplant duration, dialysis duration, and medications were extracted from the patients' medical records.

Oral lesions were diagnosed clinically by an oral medicine specialist. Pseudo membranous candidiasis was diagnosed based on whitish or yellowish plaques throughout oral mucosa which could be scraped off. Erythematous or chronic atrophic candidiasis was diagnosed based on erythematous patches mostly existed on the palate and posterior region of tongue. Hyperplastic candidiasis was considered when a whitish plaque was seen which could not be scraped. Gingival enlargement was diagnosed according to the Carranzas' classification.<sup>11</sup>

**RESULTS**

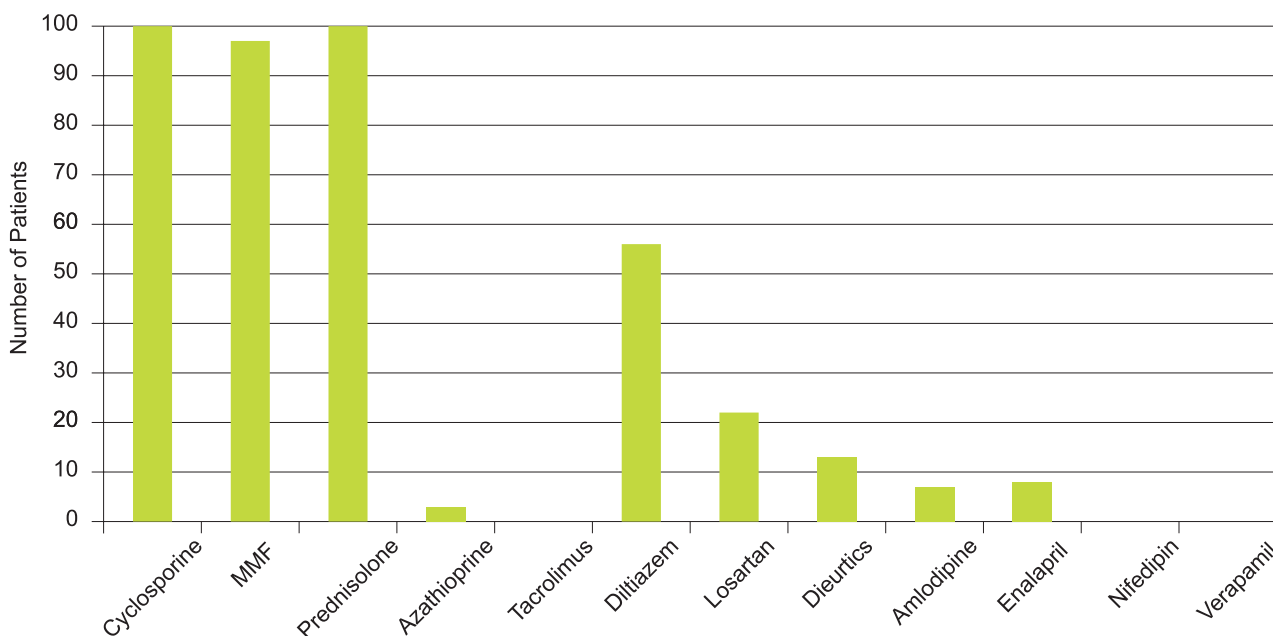
One hundred patients with a mean age of 42.9 ± 12.4 years (range, 18 to 68 years) were studied. Twelve of the participants did not have any history

of dialysis and the rest were on dialysis for 1 month to 7 years. The time from kidney transplantation ranged from 3 months to 25 years. Ninety-seven percent of the patients were receiving triple immunosuppressive drugs protocol including cyclosporine, prednisolone, and mycophenolate mofetil. None of the patients received tacrolimus. The Figure shows the drugs administered in the studied population.

On oral examinations, 24% of the patients had at least one oral lesion (Table 1). The most common oral lesion was oral candidiasis detected in 16% of the kidney transplant recipients (13 patients with acute pseudomembranous and 3 with chronic types). Pseudomembranous candidiasis was found on the dorsal surface of the tongue, the palatal region, and attached gingiva of the anterior buccal

**Table 1.** Oral Lesions in 100 Kidney Transplant Recipients

Oral Lesion	Number of Patients
Oral candidiasis	16
Acute pseudomembranous	13
Chronic erythematous	2
Chronic hyperplastic	1
Gingival enlargement	7
Grade 1	7
Grade 2	0
Grade 3	0
Coated tongue	2
<b>Total</b>	<b>24</b>



Administered medications in 100 kidney transplant recipients. MMF indicates mycophenolate mofetil.

**Table 2.** Association Between Gingival Enlargement and Oral Candidiasis and Age, Transplant Duration and Previous Dialysis Duration

Parameter	P	
	Gingival Enlargement	Oral Candidiasis
Age	.46	.44
Transplant duration	.89	.95
Previous dialysis duration	.07	.20

**Table 3.** Association of Gingival Enlargement and Oral Candidiasis With Effective Offending Medications

Medication	P	
	Gingival Enlargement	Oral Candidiasis
Cyclosporine	.15	< .001
Prednisolone	.15	< .001
Mychophenolate mofetil	.12	< .001
Diltiazem	.004	.40
Losartan	.04	.03
Amlodipine*	...	.12
Enalapril*	...	.15

\*None of the patients with gingival enlargement were using these medicines.

areas. Chronic candidiasis lesions were observed on the palate, together with papillary hyperplasia and angular cheilitis. Hyperplastic candidiasis was also observed on the palate and under maxillary dentures. Seven percent of the patients displayed grade 1 GE. Two percent of patients had a coated tongue. Normal variants were reported in the oral mucosa of the participants, including geographic tongue in 2 patients, hairy tongue in 1, pigmentation on tongue in 1, lingual varices in 1, and leukoedema in 1.

Logistic regression equation between oral candidiasis and GE with parameters of age, transplant time, and dialysis duration did not indicate any significant association (Table 2). The association of GE and oral candidiasis with effective offending medications was evaluated, and the results are shown in Table 3.

## DISCUSSION

We studied oral lesions in kidney transplant recipients who had undergone transplantation at least 3 months earlier. Kidney transplant recipients receive high doses of immunosuppressive drugs in the first months after transplantation that would be tapered gradually. Although high doses of these drugs early after transplantation provide

additional potential of opportunistic infections, prescription of prophylactic antifungal agents such as nystatin and fluconazole for at least 3 months after transplantation could prevent candidiasis in the oral cavity. Immunosuppressive drugs are then reduced to the maintenance dose after this period of time and withdrawal of prophylactic antifungal. Therefore, study of the oral lesions such as oral candidiasis seems to be reasonable after at least 3 months of transplantation.

Among the 100 kidney transplant recipients enrolled in the present study, the most common oral lesions were oral candidiasis (16%), GE (7%), and coated tongue (2%). Normal variants such as geographic tongue, hairy tongue, pigmentation on tongue, lingual varices, and leukoedema were also observed in a small number of these patients. Overall, 24% of the patients had at least one lesion, while it was 60% in the study of de la Rosa-Garcia and colleagues.<sup>1</sup> Nonetheless, they reported oral candidiasis in 18.7% of their 90 kidney transplant recipients, which was in agreement with our report of this lesion. A figure of 7.4% has been also reported by Lopez-Pintor and coworkers for oral candidiasis.<sup>12</sup> Although the most common type of oral candidiasis on Garcia and colleagues' research was erythematous, the majority of oral candidiasis cases in our study were pseudomembranous. Our results on oral candidiasis agree well with the 15.5% reported by Al-Mohaya and colleagues<sup>13</sup> in 58 kidney allograft recipients. The rate of oropharyngeal candidiasis in Gupta and coworkers' report<sup>14</sup> was 10.5%, of which 63.5 % were pseudomembranous.

Logistic regression equation between oral candidiasis and parameters of age, transplant duration, and previous dialysis duration did not indicate any significant association. Al-Mohaya and colleagues' did not find any association between candidiasis, age, and gender, either. Medications, however, may have an role in development of oral lesions in his population. Most of our patients were taking antihypertensive drugs. Reduction of salivary flow as a side effect of antihypertensive drugs is one of the risk factors for oral candidiasis in kidney transplant patients. Reduction of salivary flow originated from loss of salivary proteins like immunoglobulins and the absence of washing potential of saliva cause decreasing resistance to different infections in the oral cavity.

Gingival enlargement is another common lesion in kidney transplant recipients derived from cyclosporine use that is reported in most of the previous studies. Additionally, most of the studies explained synergistic effect of calcium channel blockers in development of GE. Clinically, GE appears initially on interdental papilla and anterior labial regions. Usually, it is limited to the attached gingiva, but it could develop coronally and interfere with occlusion, mastication, and speaking.<sup>4</sup> All of our patients were consuming cyclosporine, and 7% displayed grade 1 GE (interdental papilla involvement). This is in line with the study of Cezario and associates (7.25%) as well as with Rose and colleagues' research (7%).<sup>3,15</sup> There are very different reports about GE in various studies. King and colleagues found that 22% of their kidney transplant recipients had GE, similar to present study, in which grade 1 GE was the most prevalent type.<sup>16</sup> Although there was not any significant association between cyclosporine and GE severity according to another study by King and colleagues,<sup>17</sup> they found a significant association between those in their latest publication.<sup>16</sup> However, no significant association was found between serum level of cyclosporine and GE in our previous study.<sup>18</sup> In another study by Thomason and coworkers,<sup>19</sup> the kidney transplant recipient had not received any calcium channel blockers, and GE was seen in 16% of them. Interestingly, Al-Mohayaa and colleagues reported GE in 74% of their patients. The reason of this extensive discrepancy probably is the interference of some habitual factors in these studies. Also, patients with simultaneous consumption of cyclosporine and calcium channel blockers showed increased frequency in GE. Regarding the fact that 6 of 7 patients with GE were using diltiazem in the present study, it was impossible to survey independent effects of cyclosporine on GE. Furthermore, GE was resulted from synergistic effect of cyclosporine and calcium channel blockers, which is in agreement with some studies.<sup>3,4,13,17</sup> Calcium channel blockers are used in kidney transplant recipients to control blood pressure after transplantation. They can cause GE independently; however, in combination with calcineurin inhibitors like cyclosporine or tacrolimus, they may have synergistic effects on gingival tissues. Calcium channel blockers, as calcium antagonist drugs, act in parallel with cyclosporine, which decreases

free cytosolic calcium. Synthesis and releasing process of collagenase and metalloproteinases from gingival fibroblasts are calcium-dependent stages. Furthermore, administration of these drugs inhibits collagenolysis by interrupting the synthesis and releasing of collagenase. Imbalance between production and break-down of collagen could be one of the GE development-related mechanisms in kidney transplant recipients.<sup>13</sup>

We could not show any association between GE and parameters of transplant duration, age, or previous dialysis duration. On the contrary, Cezario and colleagues<sup>3</sup> found a significant association between transplant duration and GE, which was confirmed by Vescovi and colleagues, too.<sup>20</sup> The other reports indicate contradictory results, and the link between GE and factors such as age, gender, and clinical characteristics of dialysis and transplantation requires further elucidation.

One of the influential factors on the outcome and complications after transplantation is the immunosuppressive drug protocols. Each transplant center applies a specific protocol. The triple-drug protocol in Sina Hospital included cyclosporine, prednisolone, and mycophenolate mofetil, administered in 97% of the patients in this study. The remaining 3% received azathioprine instead of mycophenolate mofetil. Elevated level of blood glucose has also been introduced as another influential factor in development of GE in kidney transplant recipients.<sup>13</sup> The presence of diabetes mellitus as underlying disease in some of these patients is notable and expectable. In addition to the explained factors, doses of immunosuppressive drugs after transplantation, individual's genetic potentials against long-term drug metabolites, degree of gingival sensitivity to drugs, and previous gingival conditions such as inflammation are the other potential variables in incitement of GE in different individuals. The lower frequency of GE in this study compared with others can be attributed to the type of drug protocol, pretransplant examinations and control of oral conditions, and encouragement of the patients to use oral hygiene equipment.

## CONCLUSIONS

We found oral candidiasis as the most prevalent oral lesion in kidney transplant recipients, as it had been previously reported to be the most prevalent

one. Regarding the suppressed immune system of kidney transplant recipients, we suggest more emphasis on the use of antifungal drugs and oral hygiene. It is recommended that any oral lesion be eliminated before transplantation. Since there are only limited reports on oral lesions of this population from Iran, we hope this study can shed light on this particular aspect of healthcare in kidney transplant recipients.

#### ACKNOWLEDGEMENTS

This research was supported by grant provided by Tehran University of Medical Sciences and health Services. We hereby dedicate our warmest thanks to the staff of Sina Hospital for their help.

#### CONFLICT OF INTEREST

None declared.

#### REFERENCES

- de la Rosa-Garcia E, Mondragon-Padilla A, Irigoyen-Camacho ME, Bustamante-Ramirez MA. Oral lesions in a group of kidney transplant patients. *Med Oral Patol Oral Cir Bucal*. 2005;10:196-204.
- Greenberg MS, Glick M, Ship JA. *Burket's oral medicine*. 11th ed. India: BC Decker Inc; 2008.
- Cezario ES, Cota LO, Ferreira SD, et al. Gingival overgrowth in renal transplant subjects medicated with tacrolimus in the absence of calcium channel blockers. *Transplantation*. 2008;85:232-6.
- Ciavarella D, Guiglia R, Campisi G, et al. Update on gingival overgrowth by cyclosporine A in renal transplants. *Med Oral Patol Oral Cir Bucal*. 2007;12:E19-25.
- Kataoka M, Kido J, Shinohara Y, Nagata T. Drug-induced gingival overgrowth--a review. *Biol Pharm Bull*. 2005;28:1817-21.
- Lafzi A, Farahani RM, Shoja MA. Amlodipine-induced gingival hyperplasia. *Med Oral Patol Oral Cir Bucal*. 2006;11:E480-2.
- Lucas VS, Roberts GJ. Oro-dental health in children with chronic renal failure and after renal transplantation: a clinical review. *Pediatr Nephrol*. 2005;20:1388-94.
- Walker RG, Cottrell S, Sharp K, et al. Conversion of cyclosporine to tacrolimus in stable renal allograft recipients: quantification of effects on the severity of gingival enlargement and hirsutism and patient-reported outcomes. *Nephrology (Carlton)*. 2007;12:607-14.
- Thorp M, DeMattos A, Bennett W, Barry J, Norman D. The effect of conversion from cyclosporine to tacrolimus on gingival hyperplasia, hirsutism and cholesterol. *Transplantation*. 2000;69:1218-20.
- Razeghi E, Hadadi A, Khashayar P, Pourmand G. Kaposi's sarcoma in renal transplantation: report of three cases. *Clin Nephrol*. 2009;71:214-6.
- Newman M, Takei H, Carranza F. *Carranza's Clinical Periodontology*. 10th ed. Newyork: Saunders, 2006.
- Lopez-Pintor RM, Hernandez G, de Arriba L, de Andres A. Comparison of oral lesion prevalence in renal transplant patients under immunosuppressive therapy and healthy controls. *Oral Dis*. 2010;16:89-95.
- Al-Mohaya MA, Darwazeh AM, Bin-Salih S, Al-Khudair W. Oral lesions in Saudi renal transplant patients. *Saudi J Kidney Dis Transpl*. 2009;20:20-9.
- Gupta KL, Ghosh AK, Kochhar R, Jha V, Chakrabarti A, Sakhuja V. Esophageal candidiasis after renal transplantation: comparative study in patients on different immunosuppressive protocols. *Am J Gastroenterol*. 1994;89:1062-5.
- Rose B, Wilkins D, Li W, et al. Human papillomavirus in the oral cavity of patients with and without renal transplantation. *Transplantation*. 2006;82:570-3.
- King GN, Healy CM, Glover MT, et al. Prevalence and risk factors associated with leukoplakia, hairy leukoplakia, erythematous candidiasis, and gingival hyperplasia in renal transplant recipients. *Oral Surg Oral Med Oral Pathol*. 1994;78:718-26.
- King GN, Fullinaw R, Higgins TJ, Walker RG, Francis DM, Wiesenfeld D. Gingival hyperplasia in renal allograft recipients receiving cyclosporin-A and calcium antagonists. *J Clin Periodontol*. 1993;20:286-93.
- Sahebamee M. Correlation of blood levels of cyclosporine and its metabolites and local factors with gingival overgrowth in Iranian renal allograft patients. *Acta Med Iran*. 1997;35:11-5.
- Thomason JM, Seymour RA, Ellis JS. Risk factors for gingival overgrowth in patients medicated with ciclosporin in the absence of calcium channel blockers. *J Clin Periodontol*. 2005;32:273-9.
- Vescovi P, Meleti M, Manfredi M, Merigo E, Pedrazzi G. Cyclosporin-induced gingival overgrowth: a clinical-epidemiological evaluation of 121 Italian renal transplant recipients. *J Periodontol*. 2005;76:1259-64.
- Greenberg MS, Cohen G. Oral infection in immunosuppressed renal transplant patients. *Oral Surg Oral Med Oral Pathol*. 1977;43:879-85.
- Muzyka BC. Oral fungal infections. *Dent Clin North Am*. 2005;49:49-65, viii.

Correspondence to:

Maryam Shakur Shahabi, DDS, MSc  
Dental Faculty, Tehran University of Medical Sciences, Ghods St, Enghelab Ave, Tehran, Iran  
Tel: +98 21 2200 3908  
Fax: +98 21 2200 8823  
E-mail: maryam.shahabi@gmail.com

Received November 2009

Revised April 2010

Accepted April 2010