

# Protective Effect of Grape Seed Extract on Gentamicin-Induced Acute Kidney Injury

Javid Safa,<sup>1,2</sup> Hassan Argani,<sup>1,3</sup> Bahar Bastani,<sup>4</sup>  
Nariman Nezami,<sup>1,2,5</sup> Babak Rahimi Ardebili,<sup>1</sup> Amir Ghorbanihaghjo,<sup>6</sup>  
Hassan Kalagheichi,<sup>1</sup> Akbar Amirfirouzi,<sup>1</sup> Mehran Mesgari,<sup>1</sup>  
Jafar Soleimany Rad<sup>1</sup>

<sup>1</sup>Drug Applied Research Center, Tabriz University of Medical Sciences, Tabriz, Iran

<sup>2</sup>Department of Nephrology, Tabriz University of Medical Sciences, Tabriz, Iran

<sup>3</sup>Department of Nephrology, Shahid Beheshti University of Medical Sciences, Tehran, Iran

<sup>4</sup>Division of Nephrology, Saint Louis University School of Medicine, Saint Louis, Missouri, USA

<sup>5</sup>Young Researchers Club, Tabriz Islamic Azad University, Tabriz, Iran

<sup>6</sup>Biotechnology Research Center, Tabriz University of Medical Sciences, Tabriz, Iran

**Keywords.** gentamicin, toxicity, chemically-induced kidney diseases, antioxidants, grape seed extract, animal model

**Introduction.** This study was designed to determine the protective effect of red grape seed extract (RGSE) on gentamicin-induced nephrotoxicity in rats.

**Materials and Methods.** Thirty male Wistar rats were divided into 3 groups to receive RGSE, for 60 days followed by intraperitoneal injection of saline solution (as placebo) for 8 days (group 1); RGSE followed by gentamicin for 8 days (group 2); and gentamicin without pre-medication of RGSE (group 3). Oral RGSE, 40 mg/kg/d, and intraperitoneal injection of gentamicin, 100 mg/kg/d, were administered in these groups of rats. Blood and urine samples were collected on days 0 and 68 of the study. Then, the kidneys were removed for pathologic examination.

**Results.** On day 68, serum creatinine and blood urea nitrogen concentrations were highest in group 3, which was significantly higher than in group 1 ( $P = .001$  and  $P = .004$ , respectively), while slightly higher than in group 2 ( $P = .30$  and  $P = .50$ , respectively). Fractional excretion of sodium was not significantly different between the three groups. Histopathological evaluation showed that rats in group 3 had significantly higher degrees of severe acute tubular necrosis and interstitial mononuclear cell infiltration than the rats in groups 1 and 2 ( $P < .001$ ).

**Conclusions.** This animal study suggests that pretreatment with RGSE protects against gentamicin-induced acute kidney injury as evident on tissue histology. However, this was not accompanied with significant improvement in biochemical markers of kidney injury.

IJKD 2010;4:285-91  
www.ijkd.org

## INTRODUCTION

Gentamicin is a commonly used aminoglycoside antibiotic that is effective against most of gram-negative microorganisms. It has high antibacterial efficacy, rapid onset of action, low rate of true resistance, synergy with  $\beta$ -lactam antibiotics, and low cost; however, therapeutic doses of gentamicin can cause nephrotoxicity, and it is among the

most common causes of acute kidney injury.<sup>1</sup> Although the change in gentamicin dosing from multiple-daily to once-daily doses has reduced the risk of acute kidney injury, in 10% to 30% of patients, especially when administered for more than 7 days in an intensive care unit,<sup>2-4</sup> it contributes to both increased morbidity and healthcare cost.<sup>5</sup>

Nephrotoxicity caused by gentamicin is characterized by nonoliguric acute kidney failure. It decreases renal blood flow rate and urinary concentrating ability, and eventually leads to renal insufficiency.<sup>6</sup> Pathologically, gentamicin-induced nephrotoxicity is characterized by tubular damage, which is localized predominantly in the proximal tubules.<sup>7</sup> This is due to extensive accumulation of gentamicin in the kidney cortex. Although the polyanionic inositol phospholipids are believed to be the major anionic-membrane-binding sites for aminoglycosides, *megalyn*, a member of the low-density lipoprotein receptor family of glycoproteins, has been shown to mediate, at least in part, the proximal tubular uptake of aminoglycosides.<sup>8,9</sup> After endocytosis, aminoglycosides accumulate in lysosomes. These lysosomes eventually swell up with excessive lipid debris, giving the classic electron-microscopic appearance of myelin figures.<sup>6</sup>

Gentamicin induces superoxide stress anions and hydroxyl radical production in the mitochondria,<sup>10,11</sup> and acts as an iron chelator. Iron-gentamicin complex is a potent catalyst of free radical formation.<sup>12</sup> Moreover, gentamicin enhances the generation of reactive oxygen species, which could be important mediators for nephrotoxicity.<sup>13,14</sup>

It has been shown that chelators and antioxidants reduce gentamicin-induced oxidative stress, both in vitro and in vivo.<sup>15-20</sup> Various agents have been shown to reduce gentamicin-induced renal injury, including vitamin E, vitamin C, melatonin, zinc, glycyrrhizin, Ginkgo biloba extract, diallyl disulfide, manganese chloride, garlic extract, chelerythrine, transresveratrol, selenium, lycopene, taurine, clusterin, curcumin, *Hemidesmus indicus*, *Rhazya stricta*, carnosine, spirulina, caffeic acid phenethyl ester, and L-carnitine.<sup>19-27</sup>

Red grape seed extract (RGSE) contains plant flavonoids, ie, proanthocyanidins oligomers. Flavonoids are potent antioxidants and exert many health-promoting effects.<sup>28-30</sup> The antioxidant effect of proanthocyanidin oligomers is approximately 50 times greater than that of vitamin C and vitamin E.<sup>31</sup> Since the antioxidant properties of RGSE have been shown in the previous studies, and free oxygen radicals mediate gentamicin-induced nephrotoxicity, we designed this study on the effects of RGSE on gentamicin-induced nephrotoxicity.

## MATERIALS AND METHODS

### Animals and Diet

Thirty adult male Wistar rats, weighing 180 g to 200 g, were provided from our local veterinary research institute. The rats were acclimated for 4 weeks before enrolling in the study. They were maintained in controlled room with a temperature of  $23 \pm 2^\circ\text{C}$ , humidity of  $60 \pm 5\%$ , and a 12-hour light-dark cycle without any stressful stimuli. All the rats were housed in plastic cages under standard condition and had free access to water and standard diet. The diet comprised of 3000 Kcal/kg, 20% crude protein, 0.6% lysine, 0.8% methionine and cystine, 0.6% calcium, 0.4% absorbable phosphate, 0.5% sodium chloride, 6% crude lipid, and 6% crude fiber. The Animal-Humane ethics committee of Tabriz University of Medical Sciences approved the study protocol.

The rats were assigned randomly into 3 groups; 10 rats per each group. Group 1, the negative control group, were treated with 40 mg/kg/d of RGSE, orally for 60 days, followed by 0.9% sodium chloride (2.5 mL) as placebo, injected intraperitoneally for additional 8 days. Group 2, the case group, were treated with 40 mg/kg/d of RGSE, orally for 60 days, followed by 100 mg/kg/d (2.5 mL) of gentamicin (Razi Pharmaceuticals, Tehran, Iran), injected intraperitoneally for additional 8 days. Group 3, the positive control group, did not receive RGSE during the initial 60 days, but received 100 mg/kg/d of gentamicin (2.5 mL) for 8 days.

### Red Grape Seed Extract Preparation

Red grape seed extract was produced through 5 steps in the Drug Applied Research Center (DARC), Tabriz University of Medical Sciences, as follows: after removing red grape seeds from their pulps, they were dried by exposure to  $70^\circ\text{C}$  temperature for 30 minutes. The dried seeds were grinded into a powder. The powder was dissolved in N-Hexan, centrifuged for 30 minutes, and then sieved. The yielded dross underwent this process for 3 times. In the 3rd step, the dross was dissolved in methanol, centrifuged for 30 minutes and was sieved for 3 more times. The solution (comprised of methanol solvent plus grape seeds extract) was dried at  $4^\circ\text{C}$ . The extract was separated from solvent, collected, and stored in refrigerator. The antioxidant power of the product was determined by diphenyl picrylhydrazyl procedure as  $\text{RC}_{50} =$

$4 \times 10^3$  mg/mL.<sup>32,33</sup> Finally, starch was added to the extract at 1:1 ratio to form pellets, which were easily chewable and eatable by the rats.

### Biochemical and Histological Evaluations

Blood sampling (via ethmoid sinuses) and 24-hour urine collection (by urine collectors specifically designed in our laboratory) were done on the 1st and the 68th days of the study. After centrifuging whole blood samples at 5000 rpm for 5 minutes at 4°C, erythrocytes were removed and the serum samples were stored at -70°C until biochemical analysis were done. Blood urea nitrogen (BUN), and serum and urine creatinine levels were measured by urease and Jaffe methods, respectively, using the Alcyon Autoanalyzer (Abbott Park, Chicago, Illinois, USA). Serum and urine sodium concentrations were determined by Corning 480 flame photometer (Halstead, Essex, UK). Fractional excretion of sodium ( $FE_{Na}$ ) was calculated by the standard formula as described below:

$$FE_{Na} = (\text{urine sodium} \times \text{serum creatinine}) / (\text{urine creatinine} \times \text{serum sodium}) \times 100$$

At the end of the study, the rats were sacrificed during deep anesthesia and their kidneys were removed after cutting off the pedicles, and were fixed by immersion in 10% formaldehyde for 1 day. After dehydration, the specimens were embedded in paraffin and cut into multiple 3- $\mu$ m sections and stained with hematoxylin-eosin for light microscopic evaluation.

The degree of tubular injury was scored based on the Klausner classification.<sup>34</sup> The histological injuries were semiquantitatively scored as minimal (score 1, < 5% of tubules involved), mild (score 2, 5% to 25% of tubules involved), moderate (score 3, 25% to 75% of tubules involved), and severe (score 4, > 75% of tubules involved), by an expert pathologist blinded to the study groups.

### Data Analyses

Statistical analyses were performed by the SPSS software (Statistical Package for the Social Sciences, version 11.0, SPSS Inc, Chicago, Ill, USA). Results were presented as mean values  $\pm$  standard deviation. The paired *t* test and analysis of variance were used for comparisons between parametric data. The Mann-Whitney U test and chi-square test were used for analysis of nonparametric and categorical data, respectively. Correlations were tested using the Pearson linear correlation. *P* values less than .05 were considered significance.

### RESULTS

Serum creatinine and BUN levels, urine volume, and  $FE_{Na}$  before and after injections, are shown in the Table. At baseline, there were no significant differences in serum creatinine or BUN levels between the three groups. At the end of the experiments (day 68), serum creatinine and BUN were highest in the rats of group 3 that received gentamicin but not RGSE; they were significantly higher in group 3 than in group 1 with RGSE but no gentamicin ( $P = .001$  and  $P = .004$ , respectively), but they did not reach statistical significance when compared with the values in group 2 with both gentamicin and RGSE ( $P = .30$  and  $P = .50$ , respectively). In group 1, serum creatinine and BUN concentrations did not change significantly during the study period. There were also no significant differences in the 24-hour urine volumes or the of  $FE_{Na}$  values between the three groups neither at baseline, nor at the end of the study period.

### Histopathological Findings

In group 1, no significant dilatation/atrophy was seen in the proximal and distal tubules. Tubular epithelium appeared normal, and there was no interstitial infiltration with mononuclear

Serum Creatinine, Blood Urea Nitrogen (BUN), Daily Urine Volume, and Fractional Excretion of Sodium ( $FE_{Na}$ ) in the Three Rat Groups Receiving Red Grape Seed Extract (RGSE) and/or Gentamicin

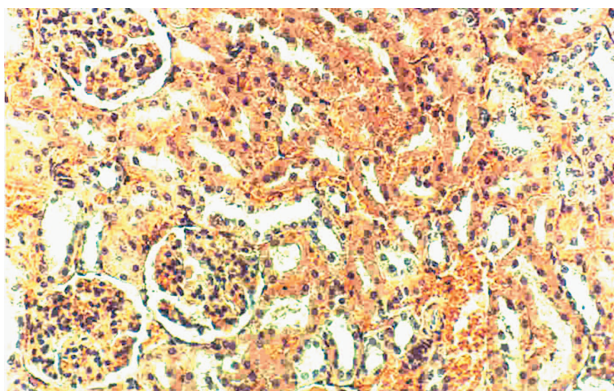
Variables	Group 1 RGSE+, Gentamicin-			Group 2 RGSE+, Gentamicin+			Group 3 RGSE-, Gentamicin+		
	Baseline	Day 68	<i>P</i>	Baseline	Day 68	<i>P</i>	Baseline	Day 68	<i>P</i>
Serum creatinine, mg/dL	0.79 $\pm$ 0.10	0.83 $\pm$ 0.10*	.50	0.76 $\pm$ 0.16	1.73 $\pm$ 0.64	.003	0.65 $\pm$ 0.04	2.22 $\pm$ 1.35*	.001
BUN, mg/dL	53.0 $\pm$ 9.4	51.8 $\pm$ 12.8†	.80	45.4 $\pm$ 10.6	141.6 $\pm$ 80.5	.005	37.8 $\pm$ 0.8	165.4 $\pm$ 86.0†	.002
Urine volume, mL/24 h	5.47 $\pm$ 1.21	5.15 $\pm$ 0.67	.70	4.72 $\pm$ 0.73	4.62 $\pm$ 0.56	.90	4.60 $\pm$ 0.90	5.00 $\pm$ 0.79	.50
$FE_{Na}$ , %	1.6 $\pm$ 1.4	1.4 $\pm$ 1.1	.80	0.5 $\pm$ 0.9	0.5 $\pm$ 1.1	.10	1.2 $\pm$ 1.3	1.4 $\pm$ 1.3	.90

\*Group 3 versus group 1,  $P = .001$

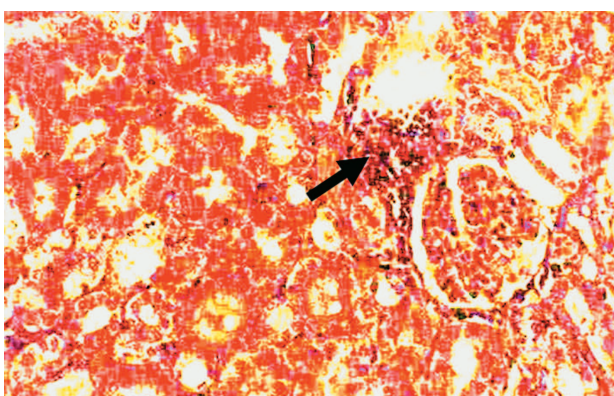
†Group 3 versus Group 1,  $P = .004$

cells. Glomeruli were also normal (Figure 1). In group 2, there was a mild-to-moderate degree of tubular damage. Tubular lumens were almost normal. Mild interstitial lymphocytic infiltrate and vascular congestion were seen in the cortex (Figure 2). Tubular damage was estimated as mild to moderate based on the Klausner classification. In group 3, lumens of the majority of the tubules of the cortex were very much dilated with flattened epithelium and loss of continuity of the epithelial cells. Epithelial cells nuclei were dense in both proximal and distal tubules. There was severe lymphocytic infiltration in the interstitium of the cortex. Interstitial fibroblasts had dense nuclei (Figure 3). Tubular damage was estimated as moderate to severe based on the Klausner classification.

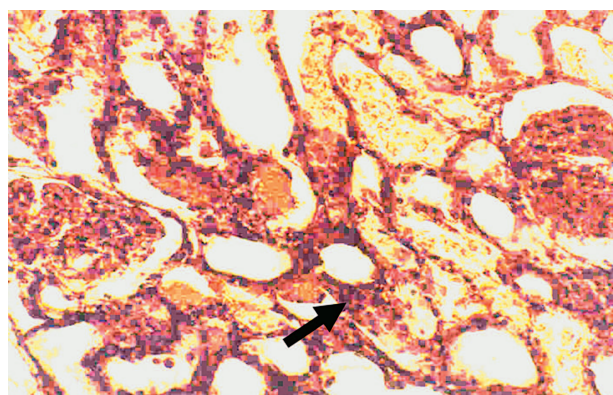
In a semi-quantitative analysis of tubulo-interstitial injury, according to the Klausner's method, mean values for groups 1, 2, and 3 were zero,  $1.60 \pm 0.25$ , and  $2.6 \pm 0.25$ , respectively. The



**Figure 1.** Normal appearance of renal tubules, interstitium, and glomeruli of rats in group 1 (hematoxylin-eosin,  $\times 400$ ).



**Figure 2.** There was a mild degree of lymphocytic interstitial infiltration (arrow) in the kidneys of rats in group 2. Tubular damage was estimated as mild to moderate (hematoxylin-eosin,  $\times 400$ ).



**Figure 3.** Lumens of the majority of tubules in rats of group 3 are very much dilated with flattened epithelium, lack of continuity, and loss of epithelial cells. Epithelial cells nuclei are dense in both proximal and distal tubules. There is moderate-to-severe lymphocytic infiltration in the cortical interstitium (arrow). Tubular damage was estimated as moderate to severe (hematoxylin-eosin,  $\times 400$ ).

scores were significantly higher in groups 2 and 3 versus group 1, and in group 3 versus group 2 ( $P < .001$ ). This finding showed that RGSE had, to some extent, protected the rat tubulo-interstitium from gentamicin nephrotoxicity.

## DISCUSSION

Reactive oxygen species have been implemented in gentamicin nephrotoxicity.<sup>13,14</sup> Several agents that scavenge or interfere with the production of reactive oxygen species have been used to ameliorate gentamicin nephrotoxicity.<sup>35</sup> It has been shown that RGSE can increase the activity of antioxidant enzymes and can prevent lipoperoxidation.<sup>36-40</sup> The present study extends the beneficial role of RGSE, in reduction of gentamicin nephrotoxicity.

Red grape seed extract, now available as a dietary supplement, contains a number of polyphenols including procyanidins and proanthocyanidins, which are powerful free radical scavengers.<sup>32-41</sup> It has been shown to have a protective effect in acetaminophen hepatotoxicity by reducing hepatocyte cell death.<sup>42,43</sup> Both acetaminophen hepatotoxicity and aminoglycoside nephrotoxicity are thought to be due to the free radical accumulation. Thus, the protective mechanism of RGSE may be similar in these models of nephrotoxicity and hepatotoxicity.

The exact chemical characteristics and the mechanism of action of RGSE have not yet been completely understood, and the experimental findings are inconsistent. Some studies have shown

that RGSE has beneficial effects in prevention of colorectal cancer,<sup>44</sup> and it also prevents low-density lipoprotein oxidation,<sup>38-40</sup> predominantly through its antioxidant properties.<sup>37</sup> Another effect of RGSE is its DNA protection. It inhibits oxidative damage to DNA in the ischemia-reperfusion injury model.<sup>30</sup> Red grape seed extract also blocks cell death signaling. Long-term treatment with RGSE would increase expression of *bcl-xl* and prevents DNA fragmentation.<sup>42,43</sup> Moreover, RGSE also reduces pro-inflammatory cytokines and has an anti-inflammatory effect.<sup>45,46</sup> The inflammatory cytokines play an important role in acute kidney injury associated with gentamicin nephrotoxicity.<sup>47,48</sup>

Another mechanism in gentamicin-induced kidney damage is the disturbances in glomerular filtration regulation by nitric oxide.<sup>49</sup> Nitric oxide might be decreased as a result of its reaction with superoxide anions produced by gentamicin.<sup>50,51</sup> Red grape seed extract could prevent deterioration of glomerular filtration rate by increasing nitric oxide production.<sup>52</sup>

In the present study, RGSE significantly reduced histological damage induced by gentamicin injection, as shown by a previous study as well.<sup>36</sup> Furthermore, serum creatinine and BUN incremented less in the rats treated with RGSE; however, the difference did not reach statistical significance. This could be due to our small sample size, short duration of exposure to gentamicin, or lack of concomitant administration of gentamicin and RGSE. In a study by El-Ashmawy and colleagues,<sup>36</sup> intraperitoneal gentamicin, 80 mg/kg/d, for 2 weeks, induced pronounced histopathological changes with a significant increase in levels of BUN, serum creatinine, and renal tissue malondialdehyde, suggestive of increased lipid peroxidation. Pretreatment with grape seed extract for 7 days and its simultaneous administration with gentamicin for 2 weeks significantly protected from nephrotoxicity through its antioxidant activity. Moreover, grape seed extract significantly protected the rats from gentamicin-induced genotoxicity, as evidenced by reduced number of aberrant cells and chromosomal aberrations in bone marrow.

## CONCLUSIONS

Our preliminary observation suggests some protective effect, especially histologically, by RGSE on gentamicin-induced nephrotoxicity. However,

while there was a trend in lower levels of rise in serum creatinine and BUN after premedication with RGSE, this finding was not supported by statistical significance. Future studies with larger number of animals, longer exposure to gentamicin, and co-administration of RGSE and gentamicin are warranted in order to confirm beneficiary effects of RGSE in humans.

## CONFLICT OF INTEREST

None declared.

## REFERENCES

1. Kahlmeter G, Dahlager JI. Aminoglycoside toxicity - a review of clinical studies published between 1975 and 1982. *J Antimicrob Chemother.* 1984;13 Suppl A:9-22.
2. Ferriols-Lisart R, Alos-Alminana M. Effectiveness and safety of once-daily aminoglycosides: a meta-analysis. *Am J Health Syst Pharm.* 1996;53:1141-50.
3. Ferrara LA, Marotta T, Rubba P, et al. Effects of alpha-adrenergic and beta-adrenergic receptor blockade on lipid metabolism. *Am J Med.* 1986;80:104-8.
4. Paterson DL, Robson JM, Wagener MM. Risk factors for toxicity in elderly patients given aminoglycosides once daily. *J Gen Intern Med.* 1998;13:735-9.
5. Eisenberg JM, Koffer H, Glick HA, et al. What is the cost of nephrotoxicity associated with aminoglycosides? *Ann Intern Med.* 1987;107:900-9.
6. Kosek JC, Mazze RI, Cousins MJ. Nephrotoxicity of gentamicin. *Lab Invest.* 1974;30:48-57.
7. Wiland P, Szechcinski J. Proximal tubule damage in patients treated with gentamicin or amikacin. *Pol J Pharmacol.* 2003;55:631-7.
8. Sastrasinh M, Knauss TC, Weinberg JM, Humes HD. Identification of the aminoglycoside binding site in rat renal brush border membranes. *J Pharmacol Exp Ther.* 1982;222:350-8.
9. Moestrup SK, Cui S, Vorum H, et al. Evidence that epithelial glycoprotein 330/megalin mediates uptake of polybasic drugs. *J Clin Invest.* 1995;96:1404-13.
10. Walker PD, Shah SV. Evidence suggesting a role for hydroxyl radical in gentamicin-induced acute renal failure in rats. *J Clin Invest.* 1988;81:334-41.
11. Cuzzocrea S, Mazzon E, Dugo L, et al. A role for superoxide in gentamicin-mediated nephropathy in rats. *Eur J Pharmacol.* 2002;450:67-76.
12. Priuska EM, Schacht J. Formation of free radicals by gentamicin and iron and evidence for an iron/gentamicin complex. *Biochem Pharmacol.* 1995;50:1749-52.
13. Kehrer JP. Free radicals as mediators of tissue injury and disease. *Crit Rev Toxicol.* 1993;23:21-48.
14. Nakajima T, Hishida A, Kato A. Mechanisms for protective effects of free radical scavengers on gentamicin-mediated nephropathy in rats. *Am J Physiol.* 1994;266:F425-31.
15. Abdel-Naim AB, Abdel-Wahab MH, Attia FF. Protective

- effects of vitamin e and probucol against gentamicin-induced nephrotoxicity in rats. *Pharmacol Res.* 1999;40:183-7.
16. Sha SH, Schacht J. Antioxidants attenuate gentamicin-induced free radical formation in vitro and ototoxicity in vivo: D-methionine is a potential protectant. *Hear Res.* 2000;142:34-40.
  17. Kumar KV, Shifow AA, Naidu MU, Ratnakar KS. Carvedilol: a beta blocker with antioxidant property protects against gentamicin-induced nephrotoxicity in rats. *Life Sci.* 2000;66:2603-11.
  18. Ben Ismail TH, Ali BH, Bashir AA. Influence of iron, deferoxamine and ascorbic acid on gentamicin-induced nephrotoxicity in rats. *Gen Pharmacol.* 1994;25:1249-52.
  19. Kadkhodae M, Khastar H, Arab HA, Ghaznavi R, Zahmatkesh M, Mahdavi-Mazdeh M. Antioxidant vitamins preserve superoxide dismutase activities in gentamicin-induced nephrotoxicity. *Transplant Proc.* 2007;39:864-5.
  20. Sohn EJ, Kang DG, Lee HS. Protective effects of glycyrrhizin on gentamicin-induced acute renal failure in rats. *Pharmacol Toxicol.* 2003;93:116-22.
  21. Parlakpınar H, Tasdemir S, Polat A, et al. Protective effect of chelerythrine on gentamicin-induced nephrotoxicity. *Cell Biochem Funct.* 2006;24:41-8.
  22. Silan C, Uzun O, Comunoglu NU, Gokcen S, Bedirhan S, Cengiz M. Gentamicin-induced nephrotoxicity in rats ameliorated and healing effects of resveratrol. *Biol Pharm Bull.* 2007;30:79-83.
  23. Karahan I, Atessahin A, Yılmaz S, Ceribasi AO, Sakin F. Protective effect of lycopene on gentamicin-induced oxidative stress and nephrotoxicity in rats. *Toxicology.* 2005;215:198-204.
  24. Girton RA, Sundin DP, Rosenberg ME. Clusterin protects renal tubular epithelial cells from gentamicin-mediated cytotoxicity. *Am J Physiol Renal Physiol.* 2002;282:F703-9.
  25. Soliman KM, Abdul-Hamid M, Othman AI. Effect of carnosine on gentamicin-induced nephrotoxicity. *Med Sci Monit.* 2007;13:BR73-83.
  26. Parlakpınar H, Tasdemir S, Polat A, et al. Protective role of caffeic acid phenethyl ester (cafe) on gentamicin-induced acute renal toxicity in rats. *Toxicology.* 2005;207:169-77.
  27. Koppie JD, Ding H, Letoha A, et al. L-carnitine ameliorates gentamicin-induced renal injury in rats. *Nephrol Dial Transplant.* 2002;17:2122-31.
  28. Singh RP, Tyagi AK, Dhanalakshmi S, Agarwal R, Agarwal C. Grape seed extract inhibits advanced human prostate tumor growth and angiogenesis and upregulates insulin-like growth factor binding protein-3. *Int J Cancer.* 2004;108:733-40.
  29. Puiggros F, Llopiz N, Ardevol A, Blade C, Arola L, Salvado MJ. Grape seed procyanidins prevent oxidative injury by modulating the expression of antioxidant enzyme systems. *J Agric Food Chem.* 2005;53:6080-6.
  30. Balu M, Sangeetha P, Murali G, Panneerselvam C. Modulatory role of grape seed extract on age-related oxidative DNA damage in central nervous system of rats. *Brain Res Bull.* 2006;68:469-73.
  31. Shi J, Yu J, Pohorly JE, Kakuda Y. Polyphenolics in grape seeds—biochemistry and functionality. *J Med Food.* 2003;6:291-9.
  32. Szabo MR, Iditoiu C, Chambre D, Lupea AX. Improved DPPH determination for antioxidant activity spectrophotometric assay. *Chem Pap.* 2007;61:214-6.
  33. Miller HE, Rigelhof F, Marquart L, Prakash A, Kanter M. Antioxidant content of whole grain breakfast cereals, fruits and vegetables. *J Am Coll Nutr.* 2000;19:312S-319S.
  34. Klausner JM, Paterson IS, Goldman G, et al. Postischemic renal injury is mediated by neutrophils and leukotrienes. *Am J Physiol.* 1989;256:F794-802.
  35. Ali BH. Agents ameliorating or augmenting experimental gentamicin nephrotoxicity: some recent research. *Food Chem Toxicol.* 2003;41:1447-52.
  36. El-Ashmawy IM, El-Nahas AF, Salama OM. Grape seed extract prevents gentamicin-induced nephrotoxicity and genotoxicity in bone marrow cells of mice. *Basic Clin Pharmacol Toxicol.* 2006;99:230-6.
  37. Feng Y, Liu YM, Fratkins JD, LeBlanc MH. Grape seed extract suppresses lipid peroxidation and reduces hypoxic ischemic brain injury in neonatal rats. *Brain Res Bull.* 2005;66:120-7.
  38. Natella F, Belevi F, Gentili V, Ursini F, Scaccini C. Grape seed proanthocyanidins prevent plasma postprandial oxidative stress in humans. *J Agric Food Chem.* 2002;50:7720-5.
  39. Shafiee M, Carbonneau MA, Urban N, Descomps B, Leger CL. Grape and grape seed extract capacities at protecting LDL against oxidation generated by Cu<sup>2+</sup>, AAPH or SIN-1 and at decreasing superoxide THP-1 cell production. A comparison to other extracts or compounds. *Free Radic Res.* 2003;37:573-84.
  40. Vigna GB, Costantini F, Aldini G, et al. Effect of a standardized grape seed extract on low-density lipoprotein susceptibility to oxidation in heavy smokers. *Metabolism.* 2003;52:1250-7.
  41. Clifton PM. Effect of grape seed extract and quercetin on cardiovascular and endothelial parameters in high risk subjects. *J Biomed Biotech.* 2004;2004:272-8.
  42. Ray SD, Parikh H, Hickey E, Bagchi M, Bagchi D. Differential effects of IH636 grape seed proanthocyanidin extract and a DNA repair modulator 4-aminobenzamide on liver microsomal cytochrome 4502E1-dependent aniline hydroxylation. *Mol Cell Biochem.* 2001;218:27-33.
  43. Ray SD, Kumar MA, Bagchi D. A novel proanthocyanidin IH636 grape seed extract increases in vivo Bcl-XL expression and prevents acetaminophen-induced programmed and unprogrammed cell death in mouse liver. *Arch Biochem Biophys.* 1999;369:42-58.
  44. Nomoto H, Iigo M, Hamada H, Kojima S, Tsuda H. Chemoprevention of colorectal cancer by grape seed proanthocyanidin is accompanied by a decrease in proliferation and increase in apoptosis. *Nutr Cancer.* 2004;49:81-8.
  45. Terra X, Valls J, Vitrac X, et al. Grape-seed procyanidins act as antiinflammatory agents in endotoxin-stimulated RAW 264.7 macrophages by inhibiting NFκB signaling pathway. *J Agric Food Chem.* 2007;55:4357-65.
  46. Jayaprakasha GK, Selvi T, Sakariah KK. Antibacterial and antioxidant activities of grape seed extracts. *Food Res*

- Inter. 2003;36:117-22.
47. Zager RA. "Subclinical" gentamicin nephrotoxicity: a potential risk factor for exaggerated endotoxin-driven TNF-alpha production. *Am J Physiol Renal Physiol*. 2007;293:F43-9.
48. Bledsoe G, Crickman S, Mao J, et al. Kallikrein/kinin protects against gentamicin-induced nephrotoxicity by inhibition of inflammation and apoptosis. *Nephrol Dial Transplant*. 2006;21:624-33.
49. Ghaznavi R, Faghihi M, Kadkhodae M, Shams S, Khastar H. Effects of nitric oxide on gentamicin toxicity in isolated perfused rat kidneys. *J Nephrol*. 2005;18:548-52.
50. Ghaznavi R, Kadkhodae M. Comparative effects of selective and non-selective nitric oxide synthase inhibition in gentamicin-induced rat nephrotoxicity. *Arch Toxicol*. 2007;81:453-7.
51. Goto T, Fujigaki Y, Sun DF, Yamamoto T, Hishida A. Plasma protein extravasation and vascular endothelial growth factor expression with endothelial nitric oxide synthase induction in gentamicin-induced acute renal failure in rats. *Virchows Arch*. 2004;444:362-74.
52. Shao ZH, Hsu CW, Chang WT, et al. Cytotoxicity induced by grape seed proanthocyanidins: role of nitric oxide. *Cell Biol Toxicol*. 2006;22:149-58.

Correspondence to:  
Bahar Bastani, MD  
Division of Nephrology, Saint Louis University School of  
Medicine  
3635 Vista Ave  
St Louis, MO 63110  
USA  
Tel: +1 314 577 8765  
Fax: +1 314 771 0784  
E-mail: bastanib@slu.edu

Received September 2009  
Revised May 2010  
Accepted June 2010