

Dermatologic Manifestations in End-stage Renal Disease

Mohammad Ali Shafiee,¹ Fatemeh Akbarian,² Kinza Khalil Memon,²
Mehdi Aarabi,^{2,3} Behrouz Boroumand⁴

¹Division of General Internal Medicine, Toronto General Hospital, University of Toronto, Toronto, Canada

²Department of Medicine, University of Toronto, Toronto, Canada

³Joint, Bone, and Connective tissue Research Center, Golestan University of Medical Sciences, Gorgan, Iran

⁴Department of Nephrology, Rasool Akram Hospital, Iran University of Medical Sciences, Tehran, Iran

Keywords. chronic kidney disease, skin lesions, end-stage renal disease, dialysis

End-stage renal disease (ESRD) is a rapidly growing global health problem within the past decades due to increased life expectancy, diabetes mellitus, hypertension, and vascular diseases. Since ESRD is not curable definitively, patients suffering from ESRD have a very low quality of life; therefore, symptomatic management is the cornerstone of medical treatment. Uremia affects almost all body organs, such as skin, through different mechanisms including biochemical, vascular, neurologic, immunologic, hematologic, endocrine, and electrolyte and volume balance disturbances. Some of these conditions are associated with significant morbidity, and patients with ESRD commonly present with a spectrum of dermatologic disorders. Each one has its own unique presentation and treatment approaches. In this review article, we discuss the clinical presentation, pathophysiology, and treatment of the most common skin disorders associated with ESRD.

IJKD 2015;9:339-53
www.ijkd.org

INTRODUCTION

Mounting prevalence of end-stage renal disease (ESRD) is a major public health problem worldwide, with millions of individuals affected. These patients suffer from a multitude of symptoms with very low quality of life, accompanied by a particularly high prevalence of dermatologic disorders. It is interesting to note that about between 50% to 100% of patients with ESRD have at least 1 dermatological disorder (Figure 1).^{1,2}

Cutaneous disorders may range from benign to life-threatening conditions, sometimes representing the earliest sign of kidney disease.³ Chronic kidney disease is associated with dysfunction of multiple organ systems, including the skin which serves as an important diagnostic window to various systemic diseases.^{1,3,4} It has been suggested that dermatological disorders are related to the duration and severity of kidney disease, many of which are exacerbated by hemodialysis therapy rendering these patients a poor quality of life.⁵

From the pathophysiologic point, these changes

are caused by multiple factors such as accumulation of uremic toxins, volume overload, effects of dialysis equipment and techniques such as needle insertion and subcutaneous bleeding during dialysis treatment, metabolic and immunologic derangements, nutritional factors, and side effects of drugs.⁶ Early recognition and treatment of skin changes can relieve the associated suffering and perhaps could also provide some cure or at least reduce the adverse outcomes, which may improve quality of life in these patients.⁷ The cutaneous changes may appear any time throughout the course of kidney disease occurring from the beginning to the progression to the terminal stage.³ However, majority of patients become more symptomatic in the advanced stages of the disease.

The commonly reported cutaneous abnormalities include pruritus, xerosis, cutaneous hyperpigmentation, and half and half nails as well as Meurcki lines, which are relatively benign as compared to more serious conditions of perforating disorders, calcifying disorders, and

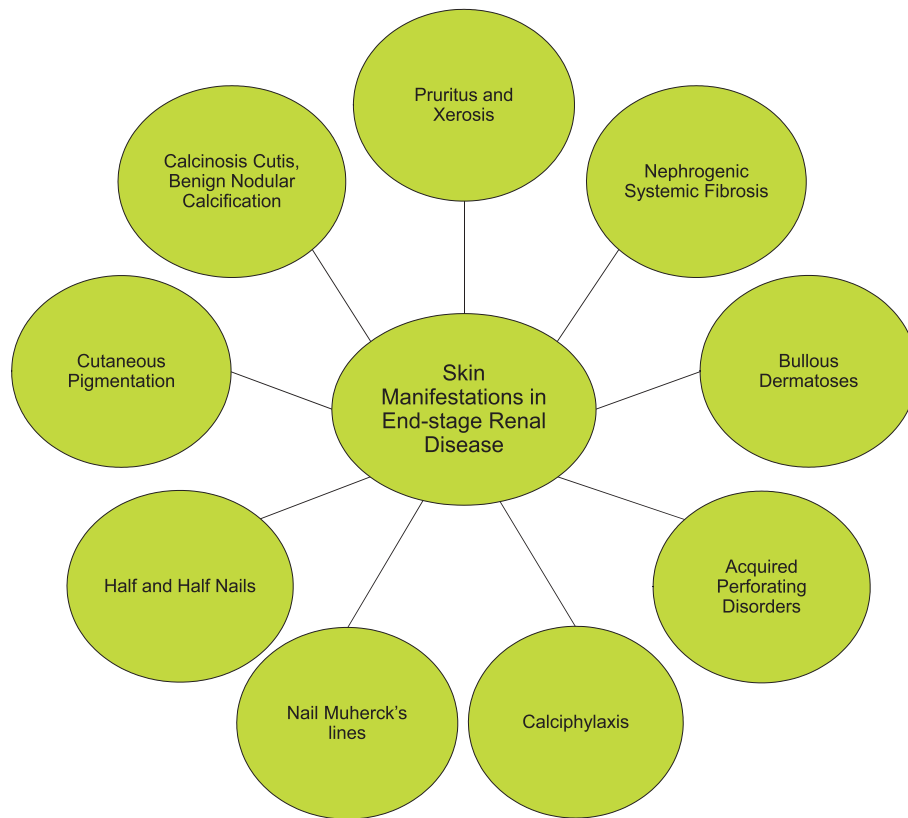

Figure 1. Dermatologic findings in end-stage renal disease.

bullous dermatoses, carrying significant morbidity.⁸ Each manifestation presents with unique clinical features. We focus on commonly encountered cutaneous entities of kidney failure and classify them according to their pathophysiology.

PRURITUS AND XEROSIS

Clinical Presentation

Pruritus is the most frequent cutaneous symptom of ESRD, experienced by 58% to 90% of patients undergoing maintenance dialysis.² It remains a distressing problem for patients, causing serious discomfort and skin damage, and it is often associated with sleeping problems and diminished quality of life.^{9,10} Pruritus can be localized or generalized. The most frequently involved body areas are the back, limbs, chest, and face.⁹ The affected skin may either appear normal or exhibit excoriations, lesions of lichen simplex chronicus, prurigo nodularis, and keratosis papules.¹¹ Skin trauma due to pruritus might also contribute to koebnerization of acquired perforating dermatosis.³ Koebner reaction refers to the lesions which could result from trauma or irritation of the skin.

Pathophysiology

A number of different mechanisms have been proposed to explain the origin of pruritus. Xerosis is a frequent skin problem (60% to 90%) in dialysis patients that predisposes to pruritus (Figure 2). Dryness of skin is caused by primary dermal changes associated with uremia, such as atrophy of sweat glands with impaired sweat secretion, disturbed stratum corneum hydration, sebaceous

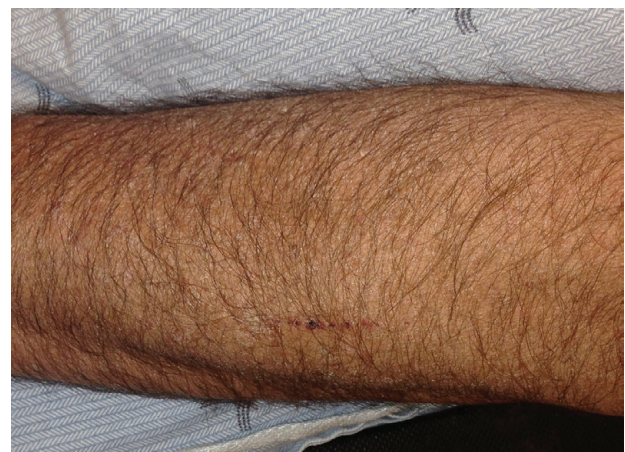

Figure 2. Xerosis in a dialysis patient (used with permission).

gland atrophy, and abnormal terminal branching of free cutaneous nerve fiber endings.⁹ Male sex, old age, high predialysis level of blood urea nitrogen, and high levels of β 2-microglobulin, calcium, and phosphate are the risk factors for pruritus.¹¹ The other factors that may play a role include secondary hyperparathyroidism, hypervitaminosis A, iron deficiency anemia, abnormal levels of magnesium and aluminum, as well as increased histamine and mast cells.^{2,3}

There are 2 main hypotheses of the mechanisms of pruritus. The opioid hypothesis suggests that the overexpression of opioid μ receptors is responsible for pruritus, which can be prevented by central κ opioid receptor stimulation. This theory is supported by successful treatment of patients with opioid antagonists. On the other hand, the immune hypothesis considers pruritus as a manifestation of systemic inflammation as shown by higher levels of pro-inflammatory mediators like C-reactive protein and interleukin-6.^{9,10} Calcium-phosphorus product which determines calcium phosphate precipitation in the skin also has an important role in pruritus. Side effects of some drugs such as angiotensin-converting enzyme inhibitors and the effect of some kinds of dialysis membrane could be other causes of pruritus.¹¹

Treatment

Treatment depends on the etiology of pruritus, and it should be individualized according to patient's needs. For example, if it is due to xerosis, skin moisturizing is the key of treatment. Moisturizing of skin with topical lubricants and keratolytics are, however, only of minimal advantage despite the presence of xerosis.³ For more localized areas of pruritus, the use of topical corticosteroids, pramoxine hydrochloride, and topical capsaicin cream (0.025%) is suggested. The latter acts by depleting substance P from cutaneous type C sensory nerve endings, which activates μ opioid receptors leading to the itch.^{3,9,10,12} Systemic medications including oral activated charcoal, gabapentin, an anticonvulsant as well as thalidomide, an immune modulator. These have shown significant benefit in ameliorating the pruritus symptoms, but their use is reserved for the patients with therapy-resistant pruritus.¹³ Other oral medications are nalfurafine, a κ opioid agonist, ondansetron, a selective serotonin antagonist and

cholestyramine which have been reported to have variable efficacy.^{9,10,14}

Based on the opioid theory, the use of naltrexone, an opioid antagonist, has shown benefits in short-term treatment of pruritus.¹¹ Phototherapy with ultraviolet B is effective in reducing pruritus in dialysis patients.¹⁴ It is suggested that it acts by suppressing histamine release as well as vitamin A levels in the epidermis which are known pruritogenic substrates responsible for itching; however, its potential for skin cancer should be considered seriously.^{7,11} Besides these therapies, it has been demonstrated that higher dialysis quality, administration of erythropoietin, and a good nutritional state also play a role in alleviating pruritus in hemodialysis patients.^{10,14} Above all these therapies the definitive cure for pruritus remains kidney transplantation.¹²

CALCINOSIS CUTIS

Clinical Presentation

Calcinosis cutis, a form of metastatic calcification, refers to the deposition of insoluble calcium salts into the skin and subcutaneous tissue and is commonly seen in patients with chronic kidney disease (Figure 3).¹⁵ In metastatic calcification, there is precipitation of calcium salts in normal tissue due to underlying abnormality of calcium or phosphate metabolism.³ Calcinosis cutis occurs in about 1% of patients with ESRD on maintenance dialysis, annually.¹¹ Clinically, it appears as yellow-white adamant tumors characterized by papules, plaques, and nodules of different sizes within the skin.¹⁵ The most commonly involved sites are peri-articular areas and finger tips.^{2,3,8} Peri-

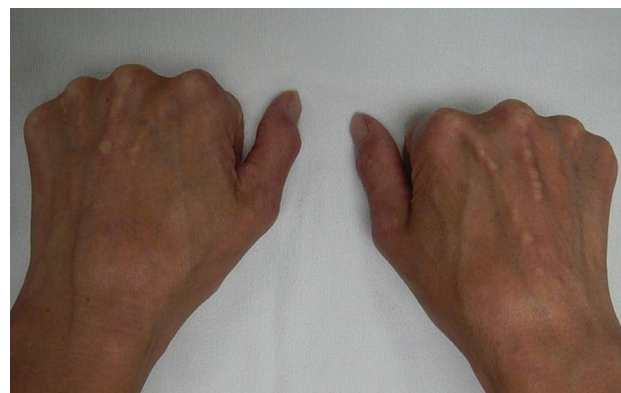

Figure 3. Calcinosis cutis or benign nodular calcification (reprinted with permission. <https://commons.wikimedia.org/wiki/File:CREST2015.JPG>).

articular lesions are usually painless unless joint mobility is affected. However, fingertip lesions are usually painful.^{2,8} A white chalky substance may be expressed through the skin.¹¹

Histopathology shows homogenous blue material (calcium) in the dermis and subcutis surrounded by foreign body giant cells and inflammation.^{2,8}

Pathophysiology

In chronic kidney disease, calcification of the skin occurs due to secondary hyperparathyroidism,⁷ which results from hyperphosphatemia and hypocalcaemia. In kidney disease hyperphosphatemia, results from decreased excretion of phosphorus. Hypocalcaemia is the result of decreased intestinal absorption of calcium due to impaired synthesis of active form of vitamin D. The resultant hyperparathyroidism in patients suffering ESRD causes mobilization of calcium and phosphorus from bone into serum, causing elevated levels of both calcium and phosphorus as well as their products, which contribute to development of lesions.^{2,11}

Treatment

The focus of therapy is normalization of calcium and phosphorus levels, as lesions will spontaneously regress.^{8,10} This can be achieved by phosphate binders and reduction of dietary phosphate.³ Foods rich in phosphate contents include milk and milk products, certain vegetables (broccoli and Brussels sprouts), oysters, salmon, beer, nuts, and wheat germ should be limited.¹⁰ In case of secondary hyperparathyroidism, if calcimimetic drugs such as cinacalcet are not effective, surgical parathyroidectomy may allow for cure.^{11,15}

CUTANEOUS PIGMENTATION

Clinical Presentation

A range of skin color changes have been described in chronic kidney disease patients undergoing dialysis, including pallor (8%), yellowish tinge (40%), and diffuse hyperpigmentation (22%) on sun-exposed areas (Figure 4).^{16,17} These cutaneous changes represent one of the most common markers of kidney disease, seen relatively early during the disease course.¹⁸ The pigmentary alteration is reported to occur in 25% to 70% of dialysis population and increases over the duration of kidney disease.¹⁹ Although hyperpigmentation is most frequently observed presentation of chronic

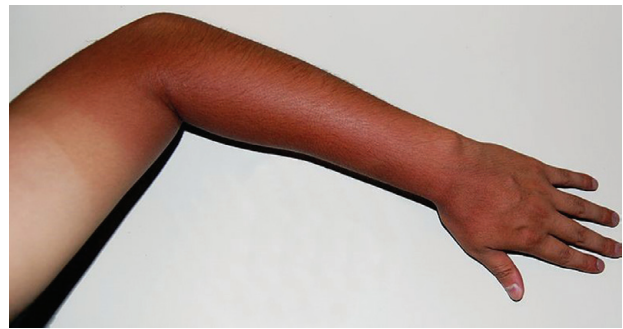


Figure 4. Brown dispegmentation seen on the sunexposed parts of the body (Reprinted with permission. https://commons.wikimedia.org/wiki/File:Skin_tanning.JPG).

kidney disease, some cases of hypopigmentation are described as well.²⁰

Pathophysiology

Diffuse hyperpigmentation on sun-exposed areas is due to an increase in melanin pigment in the basal layer of epidermis and superficial dermis, which results from an elevated levels of poorly dialyzable beta-melanocyte-stimulating hormone.^{7,19} The intensity of melanin pigmentation increases with the duration of ESRD.¹⁷ More than 50% of patients on long-term hemodialysis develop unusual forms of hyperpigmentation.²¹ The yellowish (sallow) hue is due to accumulation of lipid-soluble pigments such as lipochromes and carotenoids which are deposited in the dermis and the subcutaneous tissue.^{7,17,19} Grayish-brown skin discoloration seen in kidney disease is attributed to deposition of hemosiderin.^{3,17} Pallor of the skin is secondary to anemia of chronic disease and erythropoietin deficiency as well as resistance and iron and folic acid deficiency.^{3,21}

Treatment

The suggested treatment is the use of hemodiafiltration which clears the middle molecular-weight substances like urochrome pigments, carotenoids, and β -melanocyte-stimulating hormone more effectively than hemodialysis. Hemodiafiltration mechanism is designed according to a combination of both diffusive and convective filtrations; therefore, larger solutes could be removed more effectively than the regular hemodialysis.²² This leads to reduced accumulation of pigments with consequent decrease in hyperpigmentation. In addition, patients with chronic kidney disease should be advised to use

sunscreen, wide brimmed hats, and sun protective clothing to avoid pigment changes.¹¹

HALF AND HALF NAILS AND MUEHRCKE LINES

Clinical Presentation

Half and half nails, also known as Lindsay nails, are the most common nail change seen in patients with chronic kidney failure (Figure 5).³ Several studies have reported its prevalence ranging from 16% to 50.6%.⁴ Half and half nails have been observed in one-third of patients with uremia and is more characteristic of dialysis population occurring in as many as 40% of patients.^{17,23} There is no relationship between the severity of azotemia and the intensity of discoloration.²⁴ Clinically, nails show a white to normal proximal half and a reddish pink to brown distal half.^{7,18} The discoloration does not disappear with pressure and is not affected by nail growth, suggesting an abnormality in the nail bed.¹¹ Fingernails are affected more frequently than toenails.²⁴

Nonpalpable white transverse bands of fingernails, known as *Muehrcke lines*, which do not move with nail growth, could be a reversible feature of hypoalbuminemia (Figure 6).²⁵

Pathophysiology

The exact mechanism related to half and half nails is not clear. The suggested hypotheses include the elevated levels of β -melanocyte-stimulating hormone, which leads to activation of melanocytes with consequent deposition of melanin pigment in the nail plate.^{17,20} Lindsay, after whom this condition

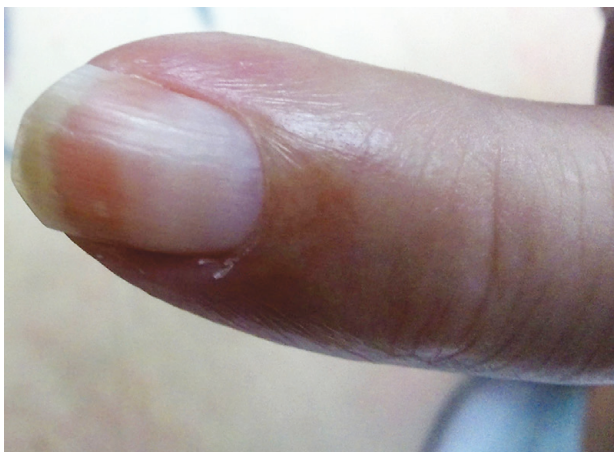

Figure 5. Half and half or Lindsay nails (reprinted with permission. <http://stanfordmedicine25.stanford.edu/the25/hand.html>).

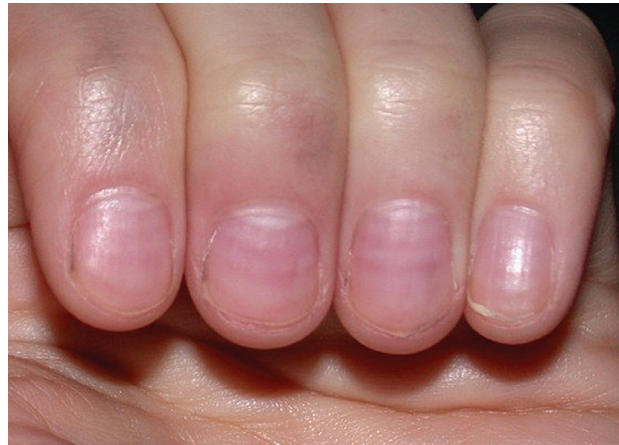

Figure 6. Muehrcke lines (reprinted with permission. <http://stanfordmedicine25.stanford.edu/the25/hand.html>).

is named, thought that the discoloration is caused by constricted venous return from the nail bed.^{24,25}

Treatment

The successful kidney transplantation may lead to remission of half and half nails in some cases but not the others.^{3,17} There is no improvement of condition with dialysis therapy.¹¹

CALCIPHYLAXIS

Clinical Presentation

Calciophylaxis, also called calcific uremic arteriopathy, is a rare and often life-threatening complication of ESRD.²⁶ It occurs in both peritoneal and hemodialysis patients and can sometimes occur prior to dialysis.^{18,27} The reported incidence rate is about 1% in patients with chronic kidney disease and up to 4% in those on dialysis.^{13,18} Risk factors for the development of calciophylaxis include female sex, Caucasian race, obesity, diabetes mellitus, malnutrition (low serum albumin levels), and warfarin therapy (Table).^{13,28,29} Other

Risk Factors for Calciophylaxis

Risk Factors
Elevated parathyroid hormone levels
Elevated calcium-phosphate product (≥ 17.5 mmol/L)
Vitamin D
Kidney failure
Diabetes mellitus
Female sex
Obesity
Caucasian
Immunosuppression
Lymphoma
Human immunodeficiency virus
Local trauma

factors associated with calciphylaxis are the use of vitamin D analogs, calcium containing phosphate binders, iron-replacement therapy, and glucocorticosteroids.^{13,30}

Although calciphylaxis mainly occurs in patients with chronic kidney disease, about 30% of cases are reported in kidney transplant patients.³ Also, it has been observed in patients with cancer, human immunodeficiency virus infection, cirrhosis, systemic lupus erythematosus, inflammatory bowel disease, and primary hyperparathyroidism with normal kidney function.^{8,30}

Clinically, patients initially develop superficial violaceous skin lesions that are painful, hyperesthetic, or pruritic surrounded by pallor or ecchymosis manifesting a livedo reticularis pattern. This pattern refers to the changes in cutaneous blood flow, which produces bluish purple reticular hyperpigmentation on the skin.³¹ The initial redness may evolve into intense erythema, which over a period of days or weeks, transforms into frank necrosis with eschar formation. Gangrenous infection may thereafter develop at the site. Subcutaneous nodules can often be felt extending beyond the edges of obvious skin lesion.^{13,28,30} The most common sites of involvement overlie thick adipose tissue such as the breast, abdomen, and thighs (Figure 7).^{10,12,32} Other less common locations of calcific uremic arteriopathy include the heart, lung, pancreas, tongue, eye, and penis.²⁸ Proximal areas of necrosis (thighs, buttocks, and trunk) have an unfavorable prognosis with a mortality rate of 60% to 80%, whereas acral distribution (calves, forearms, fingers, toes, and penis) is associated with 20% to 30% mortality rate.^{17,28}

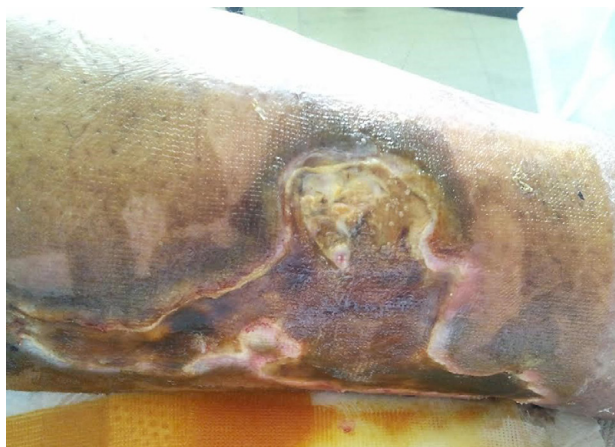

Figure 7. Calciphylaxis (used with permission).

Pathophysiology

The pathophysiology of calciphylaxis is multifactorial, because there is no single event enough which can predict its development.^{9, 11} Disturbance of phosphate and calcium homeostasis in chronic kidney disease is a key factor that underlies the mechanism of calciphylaxis (Figure 8).^{9, 12}

With the progression of kidney failure, elevated serum phosphorus levels, especially postprandial, in addition to low serum calcium levels secondary to impaired renal production of 1,25-dihydroxycholecalciferol, results in decreased intestinal calcium absorption, which leads to secondary hyperparathyroidism and hyperphosphatemia with consequent calcium deposition in microvasculature and tissue ischemia.³³ Although abnormalities of calcium, phosphorus, and parathyroid metabolism are implicated in the mechanism, high levels of calcium-phosphate product are not always absolute

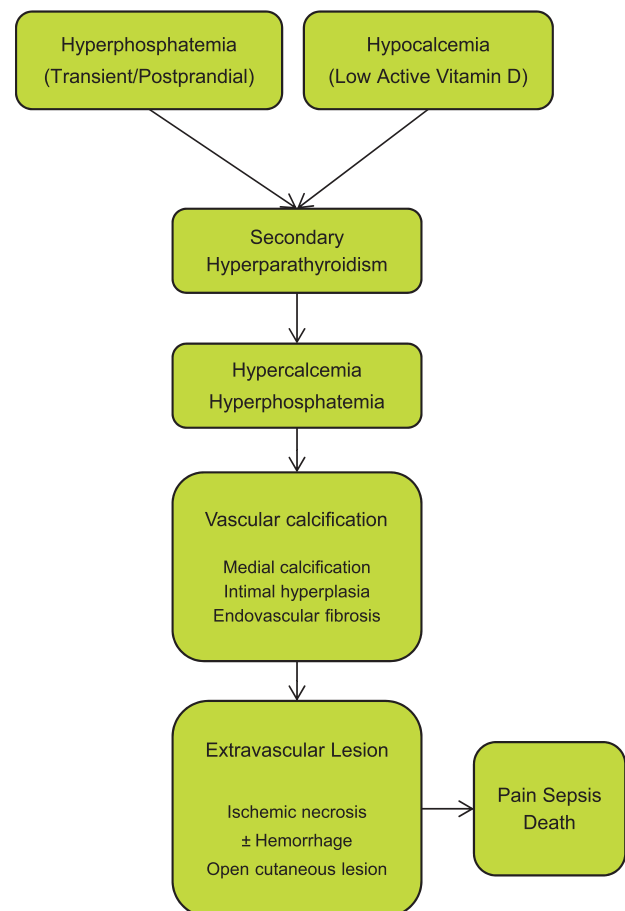


Figure 8. Pathophysiology of calciphylaxis

for the syndrome.^{2,3,10} Furthermore, it has been suggested that an imbalance of inducers and inhibitors of calcification of the vascular wall leads to calciphylaxis.^{10,13} This is supported by upregulation of inducers of vascular calcification, including osteopontin expressed by vascular smooth muscle cells and bone morphogenetic protein 4 normally involved in bone development.^{8,12} Additionally, there is transformation of vascular smooth muscle cells into osteoblast-like cells with the expression of bone-related proteins such as osteocalcin, bone sialoprotein, type 1 collagen, and osteopontin.¹³ Other mechanism thought to be deranged is suppression of inhibitors of vascular calcification including matrix Gla protein, osteoprotegerin, pyrophosphate, and fetuin-A.^{9,10} Matrix Gla protein requires vitamin-K-mediated γ -carboxylation for its functional activity. As a result, coumarin anticoagulants and vitamin K deficiency may antagonize matrix Gla protein function and stimulate vascular calcification.⁹ Levels of both osteoprotegerin and fetuin-A decline (via the nuclear factor κ B cascade) by the inflammatory changes encountered in uremia.^{9,13} Loss of pyrophosphate is related to dialytic clearance along with decreased synthesis and increased extra renal clearance, which favors the tissue calcification in chronic kidney disease.¹³

It has been suggested that a hypercoagulable state secondary to an absolute or functional protein C or protein S deficiency may be involved in the pathogenesis of calciphylaxis.⁹ In addition, abnormal deposition, especially of aluminum and certain microorganisms may have a role in the pathogenesis of calciphylaxis.^{2,10}

Skin biopsy is a useful means of understanding the pathophysiology of the disorder.³¹ Histologically, calciphylaxis demonstrates medial wall calcification of capillaries, venules, arterioles, and small arteries of dermis and subcutaneous fat along with intimal hyperplasia and endovascular fibrosis.³⁰ Affected vessels range in size from 0.02 mm to 0.60 mm and an average of 0.1 mm.³ Calcification of dermal vessels causes occlusion and subsequent tissue ischemia as well as necrosis, hence named as calcific uremic ischemic arteriolopathy.^{28,30}

A giant cell reaction may be observed in some vessels. Endovascular thrombosis may occur in subcutaneous and superficial dermal vessels but is not a diagnostic feature of calciphylaxis.³⁰

Treatment

Generally, therapeutic choices for calciphylaxis are limited, basically supportive in nature with unclear outcomes.³⁴ The main focus of treatment is to halt the progression of calcification and prevent lethal complications.^{35,36} As the abnormality of calcium phosphate metabolism has a vital role in development of calciphylaxis in patients with kidney failure, the primary treatment options revolve around controlling calcium and phosphate levels, which is achieved by using noncalcium-based phosphate binders (eg, sevelamer hydrochloride or lanthanum carbonate), increasing the frequency of dialysis (with low calcium dialysate) as well as proper use of vitamin D analogs, and limiting the phosphate intake (43 mg/d).^{2,26,35} Also, preventing secondary hyperparathyroidism and optimizing nutritional state are equally important.²⁸ In patients with elevated parathyroid hormone levels, emergent parathyroidectomy is indicated, which has shown survival advantage in short-term with complete healing of ulcers within weeks after the procedure.^{12,13,27} Parathyroidectomy is not useful in patients with low parathyroid hormone levels and may be harmful.³ For patients who cannot undergo surgery, medical therapy with cinacalcet, a calcimimetic is recommended, which increases the sensitivity of calcium-sensing receptor on the parathyroid glands.^{13,37} Furthermore, supportive measures include meticulous wound care, which may require frequent debridement of necrotic tissue, judicious use of systemic antibiotics to prevent infection, and adequate opioid analgesia.¹² In some cases, wound healing is improved by using vacuum dressing.¹³

A recent therapeutic approach includes the use of sodium thiosulfate, an inorganic salt which chelates calcium from soft tissue deposits to form calcium thiosulfate, a highly soluble calcium salt.^{13,38,39,40} It also decreases the metastatic calcification in patients with chronic kidney disease.¹² In addition, it acts as a potent antioxidant, which helps neutralize reactive oxygen radicals by generating the antioxidant glutathione.⁴⁰ Also, it prompts endothelial nitric oxide production thereby increases tissue blood flow and oxygenation.^{12,13} Furthermore, it metabolizes to hydrogen sulfide which has also vasodilatory effects.³⁹ Recommended treatment dosing is 5 g to 25g, 3 times per week at the end of each hemodialysis session for about 2 weeks to 34 months.⁴¹ Although

it is considered safe, the main side effects include nausea, vomiting, headache, rhinorrhea, and anion gap metabolic acidosis.³⁹

Bisphosphonates, both intravenous and oral, have also been used effectively in the treatment of calciphylaxis, with reported improvement in pain and signs of inflammation. The mechanism of action of bisphosphonates is complex, but it is thought to alter the ectopic deposition of calcium phosphate, suppress pro-inflammatory cytokines, and inhibit macrophage activity.^{12,13,28} It acts as a direct inhibitor of calcification similar to pyrophosphate.¹²

Hyperbaric oxygen therapy has been proved to be useful in treating calciphylaxis in patients undergoing both peritoneal and hemodialysis. Wounds that are refractory to medical management could respond to parathyroidectomy and debridement.² It enhances wound healing by promoting oxygen delivery to the damaged tissues, stimulating angiogenesis and collagen synthesis, thereby improving neutrophil-mediated bacterial killing, and reducing local tissue edema.^{2,12,13}

Moreover, patients with calciphylaxis should be assessed for hypercoagulable states such as proteins C and S and vitamin K deficiencies and antiphospholipid syndrome and anticoagulated accordingly.²⁹ In patients with warfarin-associated calciphylaxis, vitamin K therapy is recommended, and in patients who require chronic warfarin therapy, it should be switched to alternative anticoagulants.^{13,29}

Other triggers which should be avoided include obesity, local tissue trauma, and subcutaneous injections.^{2,9}

Prognosis

The prognosis of calciphylaxis remains poor in spite of aggressive therapeutic approaches, because by the first time the clinical signs are obvious, it is often too late to reverse the condition due to underlying significant vasculopathy.^{9,30} The vascular calcification increases the likelihood of ischemic events resulting in higher cardiovascular morbidity and mortality.³³

The mortality associated with this syndrome is about 60% to 80%.³ Death mainly occurs due to sepsis or even multisystem organ failure, which is common within the months of diagnosis most probably due to delayed diagnosis.^{31,36,42} Patients

with proximal necrosis have a more adverse outcome compared to those with distal involvement.^{2,29} It is estimated that 1-year rate of survival is 45% and the 5-year rate is 35%.^{13,40} An early clinical diagnosis and intervention may improve the dismal prognosis of condition.¹³

ACQUIRED PERFORATING DISORDERS

Clinical Presentation

Acquired perforating disorders represent a collection of diseases most commonly seen in the setting of ESRD and diabetes mellitus.^{8,11} They have also been reported in advanced chronic kidney disease and kidney transplant recipients.¹² The estimated incidence of perforating disorders ranges from 4.5% to 10% in hemodialysis population with a predilection for African-American patients.^{17,22} The characteristic diagnostic feature of condition is extrusion of dermal material through an epidermal channel (Figure 9).¹⁰ The acquired perforating disorders have similar clinical and histologic features to that of primary perforating disorders: Kyrle disease, perforating folliculitis, reactive perforating collagenosis, and elastosis perforans serpiginosa.¹¹

Clinically, the skin lesions consist of clustered dome-shaped papules, plaques, and nodules with centralized keratotic plug, ranging in size from 2 mm to 8 mm.^{8,12} They are most commonly found in areas susceptible to friction like extensor surfaces of the extremities with hair bearing areas as well as trunk being the most frequently involved followed by the scalp and the face.^{8,18} The pruritus is usually intense and the lesions may coalesce in a linear fashion secondary to koebnerization.¹¹ In white skins, the lesions appear pink and in darker skins, hyperpigmented or brown lesions are usually seen.³ The skin lesions may resolve spontaneously with the continued formation of new lesions.²

Pathophysiology

The pathophysiology of acquired perforating disorders is not clear. Various theories have been suggested to explain the development of the condition.¹⁸ It may occur due to poor blood supply secondary to vasculopathy in patients with diabetes mellitus or kidney disease.¹¹ Pruritus and scratching-induced local injury leads to dermal necrosis and inflammatory reaction, which is further aggravated by dermal microdeposits of calcium

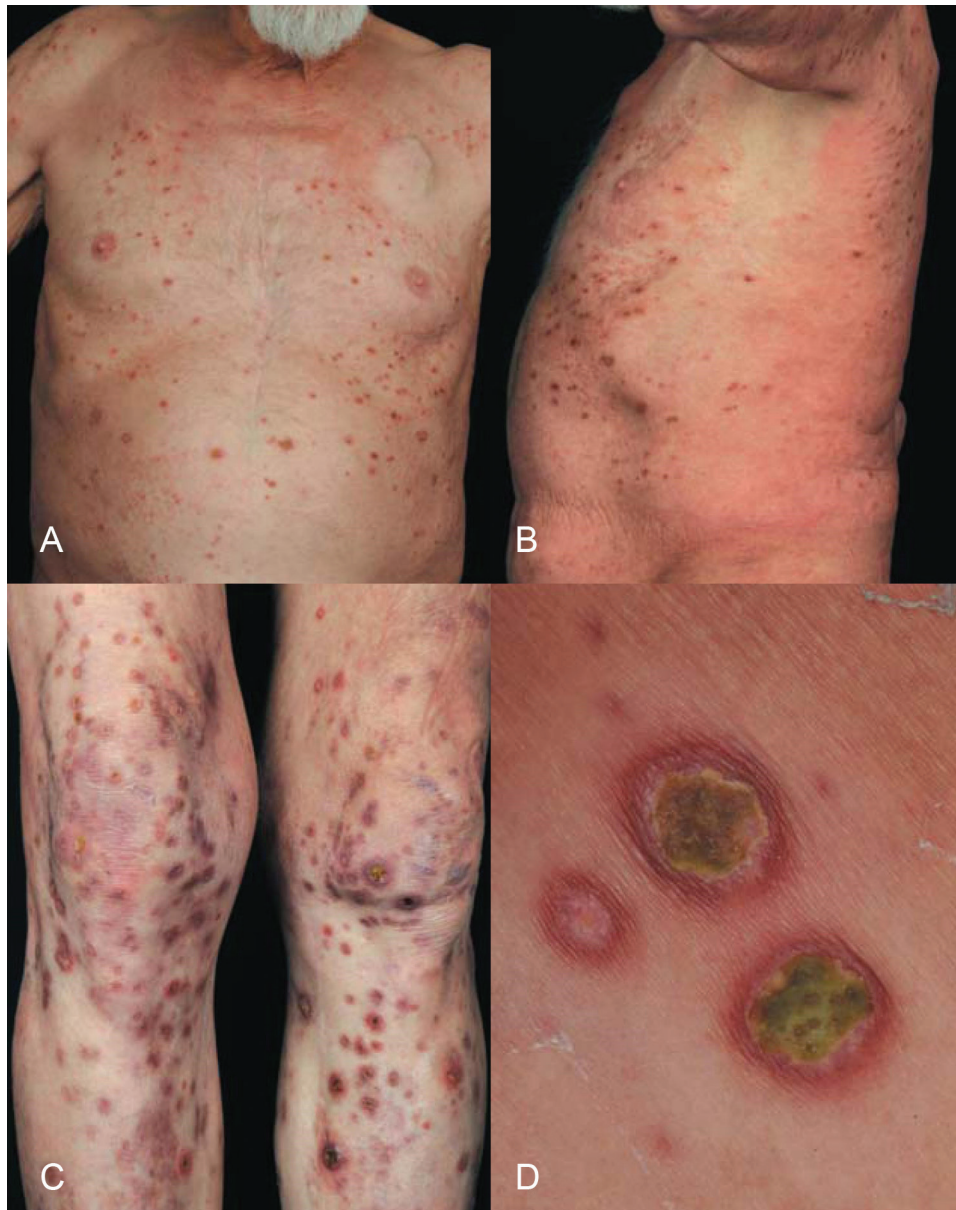

Figure 9. Acquired perforating disorders. A to C, Multiple excoriated hyperkeratotic papules and nodules with central crust involving the whole integument. D, Koebnerization (reprinted with permission. http://www.scielo.br/scielo.php?script=sci_arttext&pid=S0365-05962013000100094&lng=en&nrm=iso&tlng=en).

and uric acid.^{2,13} A foreign body reaction to altered dermal connective tissue is also thought to be a causative factor in acquired perforating disorders.⁸ It has been proposed that abnormal proliferation of epidermis secondary to faulty metabolism of vitamin A and D in kidney disease may play a role in the pathogenesis of the condition.¹⁸ Other factors responsible for the disease process include elevated levels of fibronectin that acts as a chemotactic substance for neutrophils and also stimulates epithelial proliferation.¹⁸ Leukocytes

may also contribute to pathogenesis of perforating disorders as indicated by the presence of nuclear material in the eliminated product. It is believed that elastase and collagenase, the proteinases released from degenerating leukocytes, may modify dermal connective tissue (Figure 10).^{2,18}

Treatment

Since vasculopathy is the initial event, prevention of vasculopathy is the key. Symptomatic or supportive treatment of this disorder is often challenging with

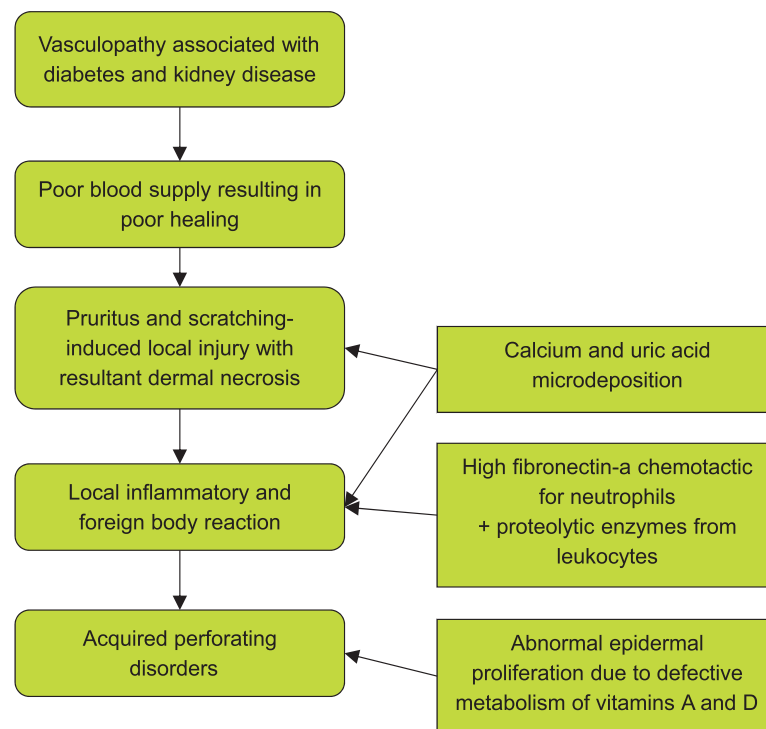


Figure 10. Pathophysiology of acquired perforating disorders

variable efficacy offered by numerous therapeutic modalities.³ The options include potent topical steroids, topical steroids under occlusion, and intralesional steroids which may relieve the inflammation but will not prevent the formation of new lesions.⁸ Topical and systemic retinoids and oral vitamin A (100 000 U/d) are beneficial in some cases.⁸ Cryotherapy and keratolytics have been tried with variable success.¹³ Narrowband ultraviolet B phototherapy, psoralen plus ultraviolet A, and allopurinol may also be considered in managing acquired perforating disorders.¹¹

BULLOUS DERMATOSES

Clinical Presentation

There are 2 types of blistering disorders which occur in patients with chronic kidney failure, being treated with hemodialysis therapy: a true porphyria (porphyria cutanea tarda) and pseudoporphyria (dialysis-porphyria; Figures 11 and 12).^{9,18,43}

The reported prevalence of these disorders in hemodialysis patients ranges from 1.2% to 18%.¹¹ Porphyria cutanea tarda is associated with abnormality of heme biosynthesis and caused by deficiency of enzyme uroporphyrinogen decarboxylase.¹² It is classified as sporadic

(acquired and type 1) and congenital (hereditary and type 2) forms.³ In the acquired group, there is enzymatic deficiency only in the liver, while in congenital group, all the tissues are deficient including erythrocytes and fibroblasts.^{3,8} Both conditions share a similar clinical manifestation and are characterized by a blistering photosensitive skin rash.¹⁸ The skin lesions include tense vesicles and bulla with a predilection for dorsal hands, forearms, as well as face, with the feet rarely involved.^{3,9} The crusting and erosions may develop secondary to blister injury and healing of lesions occur with scarring and milia formation.¹¹ Besides, facial hyperpigmentation and hypertrichosis of sun-exposed skin are frequently observed.¹³ The sclerodermoid plaques have also been reported, while in pseudoporphyria, patients do not manifest hypertrichosis and sclerodermoid changes.^{10,18}

The risk factors associated with porphyria cutanea tarda include alcohol, iron, estrogens, and viral infections including hepatitis B, hepatitis C, and human immunodeficiency syndrome.³ Pseudoporphyria is thought to be triggered by certain medications like furosemide, naproxen, amiodarone, tetracycline, nalidixic acid, and excessive ultraviolet exposure.¹²

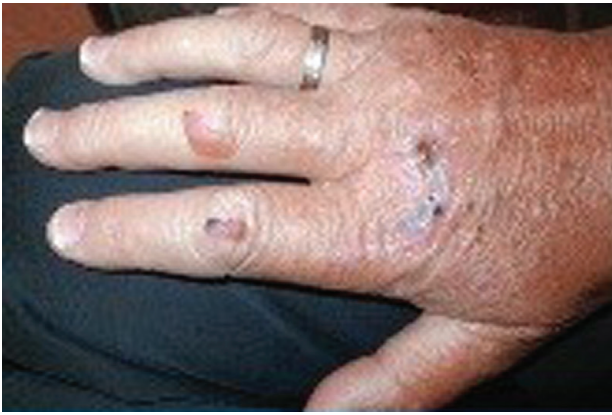

Figure 11. Porphyria cutanea tarda (reprinted with permission⁴³).

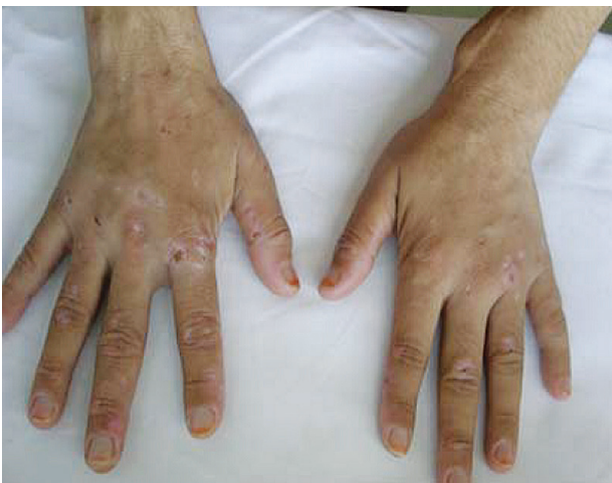

Figure 12. Dialysis porphyria (reprinted with permission⁴³).

Pathophysiology

The pathophysiology of bullous disorders in patients with kidney failure is not clear.¹⁰ Various factors have been implicated in the mechanism of porphyria cutanea tarda which include azotemia that is thought to reduce the activity of uroporphyrinogen decarboxylase involved in the metabolic pathway of porphyrins.¹⁸ Another mechanism is poor clearance of uroporphyrins in patients with kidney failure, which results in higher plasma levels.¹² Patients on hemodialysis therapy may also develop porphyria cutanea tarda as standard hemodialysis does not effectively remove the uroporphyrins, because porphyrins form complexes with high-molecular-weight proteins such as albumin, making them poorly dialyzable.¹¹ In addition, iron has an important role in the development of porphyria cutanea tarda as shown by elevated serum iron and serum ferritin and its liver stores in these

patients.^{2,8} It decreases the enzymatic activity of uroporphyrinogen decarboxylase through induction of 5-aminolevulinic synthase, a regulatory enzyme in heme biosynthesis.¹¹ In addition, it also stimulates oxidation of porphyrinogen precursors into porphyrins.⁸ Serum aluminum is also believed to be a contributing element in the pathogenesis of porphyria cutanea tarda.¹⁰

Although the origin of pseudoporphyria development is not known, excessive ultraviolet exposure, photoactive drugs, aluminum hydroxide, and erythropoietin have been suggested as causal factors in inducing the symptoms of pseudoporphyria.¹⁸ Furthermore, hemodialysis patients are more vulnerable to free radical injury due to reduced glutathione, an antioxidant, in plasma.¹¹

Treatment

Preventive strategies include avoidance of environmental triggers (alcohol, iron, and estrogens) as well as sun avoidance and sun protection by using broad-spectrum physical barriers which are key in the management of porphyria cutanea tarda and pseudoporphyria.^{8,10} As iron overload can aggravate the condition, the goal of treatment is to decrease the serum ferritin levels to the lower limit of normal range.⁴⁴ Therapeutic small volume phlebotomy (50 mL to 100 mL) performed once or twice weekly has been successful in inducing the remission after 8 months of therapy.¹¹ The use of erythropoietin therapy in conjunction with phlebotomies has been effective in mobilizing hepatic iron stores.³ Deferoxamine, an iron chelator, may be helpful but it is not suitable for long-term use because of side effects.³ Furthermore, because the standard hemodialysis does not eliminate uroporphyrins well, dialysis using high-flow dialyzer with polysulphate is used as it can decrease the porphyrin levels by up to 37%, although this is not enough to induce clinical remission.^{2,3} Antimalarial drugs such as chloroquine or hydroxychloroquine enhance the solubility of porphyrins thereby facilitating the urinary excretion, but this therapy has been unsuccessful in anuric patients.⁸ Plasmapheresis and plasma exchange have demonstrated limited success in eliminating porphyrins because they are not used often due to high costs.^{2,3} Refractory patients have exhibited complete cure following kidney transplantation.⁸

Withdrawal of culprit photosensitizing medications is crucial in managing pseudoporphyria.⁸ Treatment with N-acetylcysteine has demonstrated complete resolution of pseudoporphyria symptoms although this may take months. There may be recurrence of symptoms after discontinuing the medication.⁸

GADOLINIUM-INDUCED SYSTEMIC FIBROSIS

Clinical Presentation

Nephrogenic systemic fibrosis is a chronic progressive illness that occurs after exposure to gadolinium-based contrast agents and is typically found in patients of ESRD, including those on dialysis.^{45,46} It was first identified in 1997 as a scleromyxedema-like skin disorder in patients with renal insufficiency and was named *nephrogenic fibrosing dermopathy*.^{47,48} Afterwards, when the involvement of multiple tissues other than skin was observed (skeletal muscles, joints, myocardium, kidneys, and testes) it was renamed as *nephrogenic systemic fibrosis*.^{49,50} This disease has no racial or sex predisposition as it affects men and women equally.^{9,51} The reported prevalence of nephrogenic systemic fibrosis among hemodialysis patients is up to 18%.⁴⁹ It has also been documented in individuals with chronic kidney disease stages 3 and 4 and acute kidney failure, as well as in those with kidney transplants.⁵¹

Clinically, the symptoms of nephrogenic systemic fibrosis may appear from the day of exposure to gadolinium to a number of months later.^{52,53} The condition presents as hardening and thickening of the skin along with brawny hyperpigmentation, preferentially affecting the extremities symmetrically.^{49,51} The skin lesions commonly begin on distal lower limbs with the involvement of talocalcaneal joints which extend upwards to the center of thighs.^{49,53} In the upper extremities, it produces skin changes which ascend from the wrist to the middle upper arms, commonly sparing the neck and face.⁵³ Initially, patients may complain of itching or burning sensation associated with cutaneous erythema and edema.⁵² As the disease advances, thin fixed plaques which are hypopigmented or red to violaceous in color may appear on the extremities having reticular pattern.^{49,52} There may be hypopigmented pink or skin colored macules and papules which ultimately

combine to form patches and plaques.^{49,52} The affected skin becomes significantly indurated and fibrotic acquiring a woody texture.^{52,53} Later in the course, skin resembles peau d'orange (follicular dimpling) and the patients may have epidermal atrophy and hyperkeratosis with scaling.^{49,53} The scleral plaques have also been noted with eye involvement (Figure 13).^{50,54,55}

Patients usually develop flexion contractures of the joints within days or weeks, which lead to restriction of movement with consequent disability.⁵⁰ Nephrogenic systemic fibrosis also affects diaphragm resulting in respiratory failure, which may lead to death.⁵³

Pathophysiology

Gadolinium-based contrast agents are almost exclusively excreted by the kidneys with over 95% of administered dose cleared within 24 hours.⁵⁰ In individuals with normal kidney function, the half-life of gadolinium-based contrast agents is approximately 2 hours, which is prolonged to 30 hours or more in patients with kidney failure; thus,

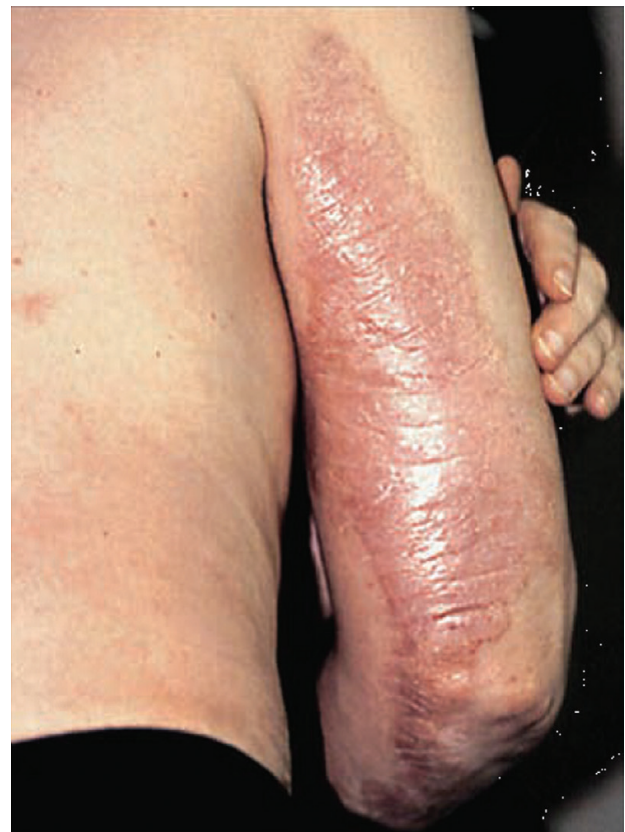

Figure 13. Nephrogenic systemic fibrosis (reprinted with permission^{50,55}).

increasing the duration of gadolinium exposure.⁴⁸⁻⁵⁰ During this time, gadolinium which is normally chelated when administered as a contrast agent may dissociate from its complex and deposit in tissues. This process is further enhanced by metabolic acidosis, pro-inflammatory conditions, and elevated ion levels (calcium, zinc, copper, and iron) through transmetallation.^{13,49,53} This is supported by detection of gadolinium deposits in the skin of affected patients.⁵³ Even though multiple repeated exposure of gadolinium increases the risk of developing nephrogenic systemic fibrosis, this disease can develop even after a single dose of gadolinium.^{49,53} Once the gadolinium is deposited in tissues, it is phagocytized by macrophages which leads to recruitment of circulating fibrocytes positive for CD34 and procollagen-I, considered as the main event in the mechanism of nephrogenic systemic fibrosis.^{9,13,49} These fibrocytes then differentiate into dermal fibroblast-like cells, which produce large amounts of sulphated glycosaminoglycans-inducing fibrosis.¹³ Transforming growth factor- β and factor XIIIa+ activated dendritic cells have also been shown to promote fibrosis in nephrogenic systemic fibrosis.^{11,13} Other risk factors which may exacerbate the condition include inflammatory states (infection, malignancy, recent surgery, and thrombosis), hyperphosphatemia, hypothyroidism, parathyroid hormone, and the use of high-dose erythropoietin therapy and exogenous iron.^{49,53}

Treatment

The prevention of nephrogenic systemic fibrosis is the best approach, since at present, there is no established treatment for this debilitating disorder.⁵³ As this disease occurs solely in patients with kidney failure, it is suggested that kidney function be determined before using gadolinium-based contrast agents either by history or laboratory testing for measurement of glomerular filtration rate.^{53,54} Additionally, these agents should be avoided in patients with severe acute or chronic kidney failure with a glomerular filtration rate less than 30 mL/min/1.73 m² and in those with hepatorenal syndrome or perioperative liver transplantation period.^{53,54} Alternative imaging techniques should be considered until and unless there is a true indication for gadolinium-based contrast agents.^{50,54} The use of lowest possible dose and avoiding

repeated exposure to gadolinium contrast agents is suggested.⁵⁰ The immediate hemodialysis preferably done in less than 2 hours following gadolinium exposure is recommended in patients with chronic kidney disease which is effective in eliminating about 93% of the administered gadolinium after 2 sessions.^{50,54} It is also suggested that exogenous iron therapy should be withheld 1 week before elective magnetic resonance imaging, as well as the erythropoiesis-stimulating agents.^{50,53}

Once nephrogenic systemic fibrosis is developed, the major therapeutic target is to recover the kidney function, which might happen spontaneously in patients with acute kidney failure, but in cases of chronic kidney failure, it needs kidney transplantation.^{53,54} Various treatment options have been used including topical and oral corticosteroids, selective H₂ blockers such as cimetidine, ranitidine, cyclosporine, and thalidomide.⁴⁹ Thalidomide has been useful in improving the very early skin changes but remained ineffective in the advanced stages of the disease.⁵² Ultraviolet A phototherapy, extracorporeal photopheresis, plasmapheresis, and sodium thiosulphate have demonstrated variable efficacy in the treatment of nephrogenic systemic fibrosis.⁴⁹ Improvement in skin changes and joint contractures has been seen with the use of imatinib mesylate, an antifibrotic which acts by inhibiting dermal fibroblast synthesis of fibronectin and type I collagen and also reduces the extracellular matrix production.^{50,52} In addition, physiotherapy and pain control are also beneficial in patients with nephrogenic systemic fibrosis.^{53,54,56}

CONCLUSIONS

Dermatologic disorders are frequently seen in patients with ESRD, which may increase with increased duration and severity of the underlying kidney disease. These dermatological disorders could be potentiated by using some medications such as warfarin and erythropoietin. These disorders have a negative impact on patient's physical and mental health, rendering them a low quality of life. Proper evaluation and management of these dermatologic disorders may reduce the associated morbidity and improve the quality of life in these patients.

CONFLICT OF INTEREST

None declared.

REFERENCES

1. Kolla PK, Desai M, Pathapati RM, et al. Cutaneous manifestations in patients with chronic kidney disease on maintenance hemodialysis. *ISRN Dermatol*. 2012;2012:679619.
2. Hajheydari Z, Makhloogh A. Cutaneous and mucosal manifestations in patients on maintenance hemodialysis: a study of 101 patients in Sari, Iran. *Iran J Kidney Dis*. 2008;2:86-90.
3. Robinson-Bostom L, DiGiovanna JJ. Cutaneous manifestations of end-stage renal disease. *J Am Acad Dermatol*. 2000;43:975-86.
4. Lupi O, Rezende L, Zangrando M, et al. Cutaneous manifestations in end-stage renal disease. *An Bras Dermatol*. 2011;86:319-26.
5. Deshmukh SP, Sharma YK, Dash K, Chaudhari NC, Deo KS. Clinicoepidemiological study of skin manifestations in patients of chronic renal failure on hemodialysis. *Indian Dermatol Online J*. 2013;4:18-21.
6. Khanna D, Singal A, Kalra OP. Comparison of cutaneous manifestations in chronic kidney disease with or without dialysis. *Postgrad Med J*. 2010;86:641-7.
7. Tajbakhsh R, Dehghan M, Azarhoosh R, et al. Mucocutaneous manifestations and nail changes in patients with end-stage renal disease on hemodialysis. *Saudi J Kidney Dis Transpl*. 2013;24:36-40.
8. Udayakumar P, Balasubramanian S, Ramalingam KS, Lakshmi C, Srinivas CR, Mathew AC. Cutaneous manifestations in patients with chronic renal failure on hemodialysis. *Indian J Dermatol Venereol Leprol*. 2006;72:119-25.
9. Cordova KB, Oberg TJ, Malik M, Robinson-Bostom L. Dermatologic conditions seen in end-stage renal disease. *Semin Dial*. 2009;22:45-55.
10. Evenepoel P, Kuypers DR. Dermatologic manifestations of chronic kidney disease. In: Floege J, Johnson RJ, Feehally J, editors. *Comprehensive clinical nephrology*. 4th ed. Saunders; 2010. p. 1001-9.
11. Ko CJ, Cowper SE. Dermatologic conditions in kidney disease. In: Taal MW, Chertow GM, Marsden PA, Skorecki K, Yu ASL, Brenner BM, editors. *Brenner Rector's the kidney*. 9th ed. Philadelphia, PA: Saunders Elsevier; 2011. p. 2156-68.
12. Markova A, Lester J, Wang J, Robinson-Bostom L. Diagnosis of common dermopathies in dialysis patients: a review and update. *Semin Dial*. 2012;25:408-18.
13. Brewster UC. Dermatological disease in patients with CKD. *Am J Kidney Dis*. 2008;51:331-44.
14. Kuypers DR. Skin problems in chronic kidney disease. *Nat Clin Pract Nephrol*. 2009;5:157-70.
15. Chung SD, Lu CW, Wu VC, Chen YS, Chang KC, Chu SH. Metastatic calcinosis cutis. *QJM*. 2009;102:359.
16. Krause WKH. Cutaneous manifestations of endocrine diseases. Springer; 2009. p. 35-44.
17. Amatya B, Agrawal S, Dhali T, Sharma S, Pandey SS. Pattern of skin and nail changes in chronic renal failure in Nepal: a hospital-based study. *J Dermatol*. 2008;35:140-5.
18. Abdelbaqi-Salhab M, Shalhub S, Morgan MB. A current review of the cutaneous manifestations of renal disease. *J Cutan Pathol*. 2003;30:527-38.
19. Avermaete A, Altmeyer P, Bacharach-Buhles M. Skin changes in dialysis patients: a review. *Nephrol Dial Transplant*. 2001;16:2293-6.
20. Thomas EA, Pawar B, Thomas A. A prospective study of cutaneous abnormalities in patients with chronic kidney disease. *Indian J Nephrol*. 2012;22:116-20.
21. Dyachenko P, Shustak A, Rozenman D. Hemodialysis-related pruritus and associated cutaneous manifestations. *Int J Dermatol*. 2006;45:664-7.
22. Tattersall JE, Ward RA. Online haemodiafiltration: definition, dose quantification and safety revisited. *Nephrol Dial Transplant*. 2013;28:542-50.
23. Huang WT, Wu CC. Half-and-half nail. *CMAJ*. 2009;180:687.
24. Lindsay PG. The half-and-half nail. *Arch Intern Med*. 1967;119:583-7.
25. Sharma V, Kumar V. Muehrcke lines. *CMAJ*. 2013;185:E239.
26. Hayashi M, Takamatsu I, Kanno Y, Yoshida T, Abe T, Sato Y. A case-control study of calciphylaxis in Japanese end-stage renal disease patients. *Nephrol Dial Transplant*. 2012;27:1580-4.
27. Fine A, Zacharias J. Calciphylaxis is usually non-ulcerating: risk factors, outcome and therapy. *Kidney Int*. 2002;61:2210-7.
28. Ross EA. Evolution of treatment strategies for calciphylaxis. *Am J Nephrol*. 2011;34:460-7.
29. Banerjee C, Woller SC, Holm JR, Stevens SM, Lahey MJ. Atypical calciphylaxis in a patient receiving warfarin then resolving with cessation of warfarin and application of hyperbaric oxygen therapy. *Clin Appl Thromb Hemost*. 2010;16:345-50.
30. Wilmer WA, Magro CM. Calciphylaxis: emerging concepts in prevention, diagnosis, and treatment. *Semin Dial*. 2002;15:172-86.
31. Gibbs MB, English JC, III, Zirwas MJ. Livedo reticularis: an update. *J Am Acad Dermatol*. 2005;52:1009-19.
32. Newey CR, Sarwal A, Uchin J, Mulligan G. Necrotic skin lesions after hemodialysis. *Cleve Clin J Med*. 2011;78:646-8.
33. Chacon G, Nguyen T, Khan A, Sinha A, Maddirala S. Warfarin-induced skin necrosis mimicking calciphylaxis: a case report and review of the literature. *J Drugs Dermatol*. 2010;9:859-63.
34. Rockx MA, Sood MM. A necrotic skin lesion in a dialysis patient after the initiation of warfarin therapy: a difficult diagnosis. *J Thromb Thrombolysis*. 2010;29:130-3.
35. Mwiapatayi BP, Cooke C, Sinniah RH, Abbas M, Angel D, Sieunarine K. Calciphylaxis: emerging concept in vascular patients. *Eur J Dermatol*. 2007;17:73-8.
36. Wollina U. Update on cutaneous calciphylaxis. *Indian J Dermatol*. 2013;58:87-92.
37. Gupta D, Tadros R, Mazumdar A, Moiin A, Fuleihan SF. Breast lesions with intractable pain in end-stage renal disease: calciphylaxis with chronic hypotensive

- dermatopathy related watershed breast lesions. *J Palliat Med.* 2013;16:551-4.
38. Cohen GF, Vyas NS. Sodium thiosulfate in the treatment of calciphylaxis. *J Clin Aesthet Dermatol.* 2013;6:41-4.
 39. Hayden MR. Calciphylaxis and the cardiometabolic syndrome: the emerging role of sodium thiosulfate as a novel treatment option. *J Cardiometab Syndr.* 2008;3:55-9.
 40. O'Neil B, Southwick AW. Three cases of penile calciphylaxis: diagnosis, treatment strategies, and the role of sodium thiosulfate. *Urology.* 2012;80:5-8.
 41. Barreiros HM, Goulao J, Cunha H, Bartolo E. Photoletter to the editor - Calciphylaxis: a diagnostic and therapeutic challenge. *J Dermatol Case Rep.* 2013;7:69-70.
 42. Scola N, Kreuter A. Calciphylaxis: a severe complication of renal disease. *CMAJ.* 2011;183:1882.
 43. El Kabbaj D, Laalou A, Alouane Z, Bahadi A, Oualim Z. Hemodialysis-associated pseudoporphyria resistant to N-acetylcysteine. *Saudi J Kidney Dis Transpl.* 2011;22:311-4.
 44. Ratnaike S, Blake D, Campbell D, Cowen P, Varigos G. Plasma ferritin levels as a guide to the treatment of porphyria cutanea tarda by venesection. *Australas J Dermatol.* 1988;29:3-8.
 45. Morcos SK, Thomsen HS. Nephrogenic systemic fibrosis: more questions and some answers. *Nephron Clin Pract.* 2008;110:c24-c31.
 46. Bernstein EJ, Schmidt-Lauber C, Kay J. Nephrogenic systemic fibrosis: a systemic fibrosing disease resulting from gadolinium exposure. *Best Pract Res Clin Rheumatol.* 2012;26:489-503.
 47. Igreja AC, Mesquita KC, Cowper SE, Costa IM. Nephrogenic systemic fibrosis: concepts and perspectives. *An Bras Dermatol.* 2012;87:597-607.
 48. Chopra T, Kandukurti K, Shah S, Ahmed R, Panesar M. Understanding nephrogenic systemic fibrosis. *Int J Nephrol.* 2012;2012:912189.
 49. Kay J. Nephrogenic systemic fibrosis: a gadolinium-associated fibrosing disorder in patients with renal dysfunction. *Ann Rheum Dis.* 2008;67 Suppl 3:iii66-iii69.
 50. Schlaudecker JD, Bernheisel CR. Gadolinium-associated nephrogenic systemic fibrosis. *Am Fam Physician.* 2009;80:711-4.
 51. Kribben A, Witzke O, Hillen U, Barkhausen J, Daul AE, Erbel R. Nephrogenic systemic fibrosis: pathogenesis, diagnosis, and therapy. *J Am Coll Cardiol.* 2009;53:1621-8.
 52. Mayr M, Burkhalter F, Bongartz G. Nephrogenic systemic fibrosis: clinical spectrum of disease. *J Magn Reson Imaging.* 2009;30:1289-97.
 53. Marckmann P, Skov L. Nephrogenic systemic fibrosis: clinical picture and treatment. *Radiol Clin North Am.* 2009;47:833-40, vi.
 54. Nair PA, Jivani NB, Diwan NG. Kyrle's disease in a patient of diabetes mellitus and chronic renal failure on dialysis. *J Family Med Prim Care.* 2015;4:284-6.
 55. Sadowski EA, Bennett LK, Chan MR, et al. Nephrogenic systemic fibrosis: risk factors and incidence estimation. *Radiology.* 2007;243:148-57.
 56. Tilz H, Becker JC, Legat F, Schettini AP, Inzinger M, Massone C. Allopurinol in the treatment of acquired reactive perforating collagenosis. *An Bras Dermatol.* 2013;88:94-7.

Correspondence to:
 Mohammad A Shafiee, MD, MSc, FRCPC
 Division of General Internal Medicine, Department of Medicine,
 Toronto General Hospital, University of Toronto
 14 EN-208, 200 Elizabeth St
 Toronto, Ontario, Canada
 M5G 2C4
 Tel: +1 416 340 4800, extension 6244
 Fax: +1 416 595 5826
 E-mail: mohammad.shafiee@uhn.ca

Received October 2014
 Revised June 2015
 Accepted July 2015