

# Recurrent Idiopathic Membranous Glomerulonephritis After Kidney Transplantation and Successful Treatment With Rituximab

Khadijeh Makhdoomi,<sup>1,2</sup> Saeed Abkhiz,<sup>1,2</sup> Farahnaz Noroozinia,<sup>1,3</sup>  
Azam Mivefroshan,<sup>1,2</sup> Javad Zeinali,<sup>1,2</sup> Lale Jafari,<sup>1,2</sup>  
Abbas Saffarifar<sup>3</sup>

<sup>1</sup>Nephrology and Renal Transplant Research Center, Urmia University of Medical Sciences, Urmia, Iran

<sup>2</sup>Division of Nephrology, Urmia University of Medical Sciences, Urmia, Iran

<sup>3</sup>Department of Pathology, Urmia University of Medical Sciences, Urmia, Iran

After kidney transplantation, approximately 40% of patients with membranous glomerulonephritis experience recurrence, most commonly during the first year. We present 2 patients with recurrent membranous glomerulonephritis after kidney transplantation that were successfully treated with rituximab.

IJKD 2015;9:158-62  
www.ijkd.org

**Keywords.** kidney transplantation, membranous glomerulonephritis, rituximab

## INTRODUCTION

All forms of primary glomerulonephritis may recur after kidney transplantation and potentially jeopardize the survival of the graft.<sup>1</sup> Membranous glomerulonephritis (MGN) is the most frequent cause of nephrotic syndrome in adults.<sup>2</sup> It is an antibody-mediated disease induced by deposits of immunoglobulins and complement components on the subepithelial layer of the glomerular capillary wall.<sup>3</sup> Infiltration of CD20-positive B cells has also been demonstrated in renal biopsies of patients with MGN.<sup>4</sup> Recurrence of idiopathic MGN has been reported to occur in 30% to 42% of patients in various series, resulting in reduced allograft survival.<sup>5</sup> Recurrence tends to occur early in the posttransplantation period, and men with hypertension and heavy proteinuria in the native kidney are considered to be at increased risk for that.<sup>6</sup> Rituximab targets the CD20 antigen expressed on immature and mature B cells. The administration of rituximab results in rapid and sustained depletion of circulating and tissue B cells.<sup>7</sup> Good results with rituximab have been reported in treatment MGN. We present 2 patients with

recurrent membranous glomerulonephritis after kidney transplantation who were successfully treated with rituximab.

## CASE REPORT

Two men aged 56 and 52 years with idiopathic MGN were presented 7 and 19 years after kidney transplantation, respectively (Table 1). Light microscopic examination revealed prominent uniform thickening of the glomerular capillary basement membrane with widely patent glomerular capillary lumen and periglomerular infiltration of lymphocytes. Thickened arterial walls are also notable (Figures 1 and 2). Immunohistochemistry for CD20 demonstrated interstitial B-lymphocytes aggregations, especially around the glomeruli (Figure 3). They were treated with 4 doses of rituximab, 375 g per 1.73 m<sup>2</sup>, per 2 weeks (Table 2). After 36 and 18 months of follow-up, respectively, their serum creatinine was stable and urinalysis showed no proteinuria.

## DISCUSSION

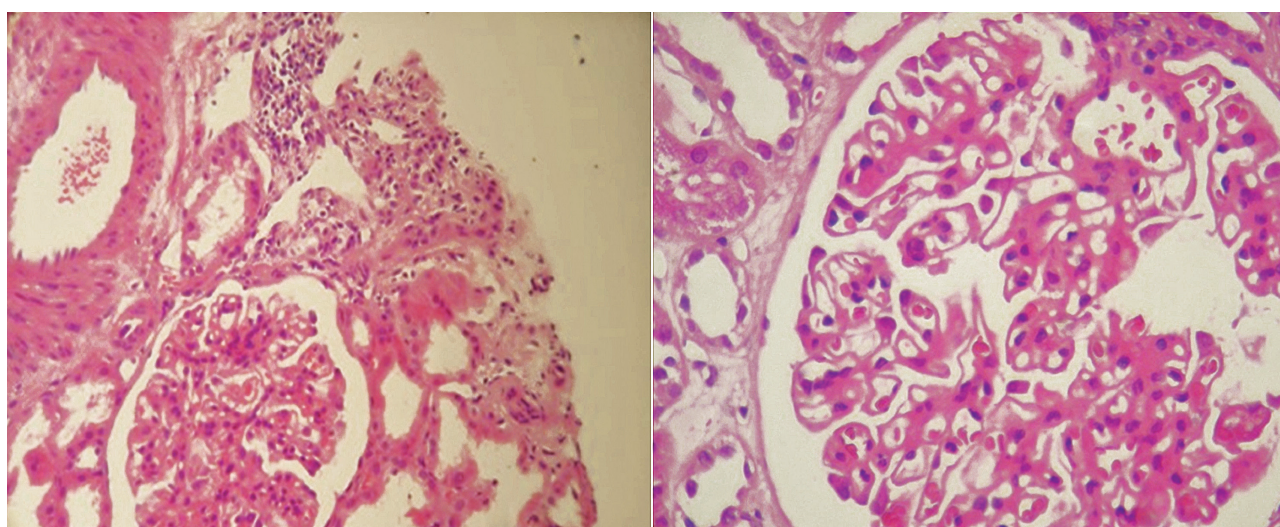
Idiopathic MGN is one of the most common

**Table 1.** Data Before Kidney Transplantation

Parameter	Patient 1	Patient 2
Sex	Male	Male
Age, y	56	52
Weight, kg	63	95
Body mass index, kg/m <sup>2</sup>	23	29
Time from first presentation with Nephrotic syndrome, y	14	22
Serum creatinine at first presentation, mg/dL	0.6	1
Results of serologic tests*	Negative	Negative
Serology of Hepatitis B and C viruses	Negative	Negative
Hypertension	Positive	Positive
Proteinuria at first presentation, g/24 h	> 5	> 4.3
Response to Ponticelli protocol†	Negative	Negative
Second drug selection	Cyclosporine	Cyclosporine
Response to cyclosporine	Partial Remission	Partial Remission
Time to overt kidney failure, y	3	10
Time to end-stage renal disease, y	7	19
Hemodialysis duration, mo	6	9
Follow-up since transplantation, y	7	19
Donor source	Living Unrelated, Male	Living Unrelated, Male

\*Serologic test included antinuclear antibodies, anti-double-stranded DNA, and complements C3, C4, and CH50.

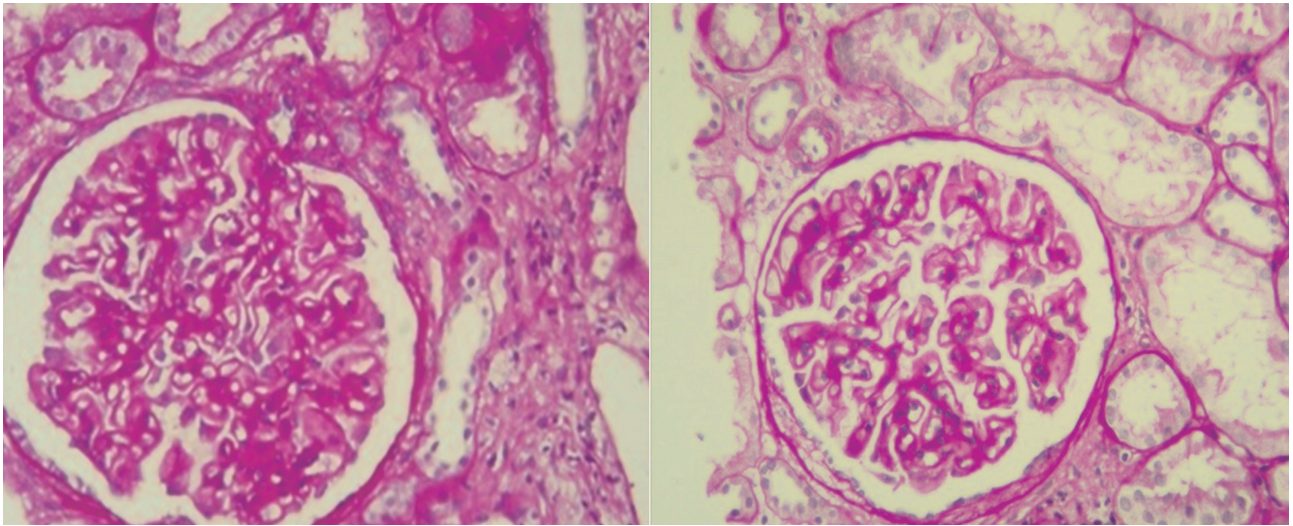
†Ponticelli protocol included methylprednisolone, 1000 mg intravenous for 3 days, followed by 0.5 mg/kg of prednisolone in the 1st month and 0.1 mg/kg of chlorambucil for the 2nd month, repeated for 3 courses.


**Figure 1.** Light microscopic examination using hematoxylin-eosin staining. **Left,** Patient 1; **Right,** Patient 2.

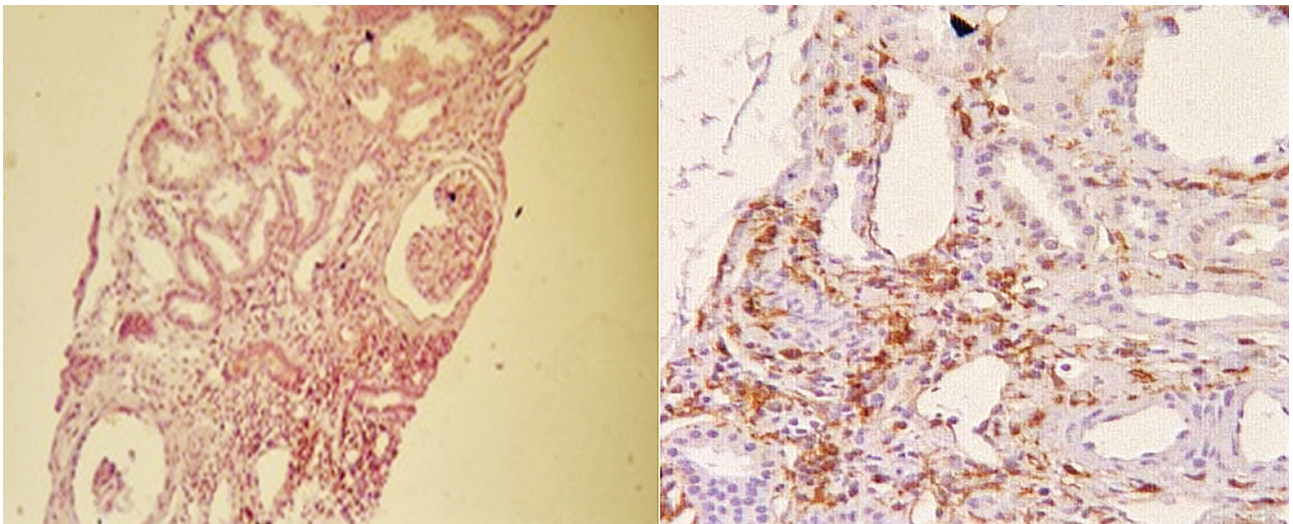
forms of primary glomerular disease. After kidney transplantation, approximately 40% of patients with MGN have recurrence, most commonly during the first year. The progression of the histologic and clinical manifestations of recurrent MGN in allografts represent that without additional immunosuppressive treatment, the MGN persist and progress, and in the majority of patients proteinuria increases over time despite good blood pressure control and use of angiotensin blockade. This high rate of recurrence and the

progressive nature of MGN after transplantation suggest that these patients represent a selective subgroup of the disease unlikely to spontaneously remit, and this form of disease may lead to graft failure.

Options for the treatment of recurrent MGN are limited. Although calcineurin inhibitors and mycophenolate mofetil are effective in reducing proteinuria and improving native kidney survival in MGN, these therapeutic strategies may not be relevant to the majority of kidney transplant



**Figure 2.** Light microscopic examination using periodic acid-Schiff staining. **Left,** Patient 1; **Right,** Patient 2.



**Figure 3.** Immunohistochemistry for CD20. **Left,** Patient 1; **Right,** Patient 2.

recipients who are already taking these drugs. Cytotoxic agents are also effective in native MGN, but because of leukopenia and the long-term risk of malignancy, the use of these drugs after transplantation is dubious.

Rituximab reduces proteinuria by decreasing B cells and perhaps suppressing the production of antibodies that may be responsible for the immune deposits and selective removal of immunoglobulin G from the glomeruli. Based on these considerations, rituximab may be an effective treatment for recurrent MGN. Ruggenti and colleagues<sup>8</sup> and Fervenza and colleagues<sup>9</sup> demonstrated that rituximab was effective in treating native MGN. Another publication suggests that rituximab may result in

partial histologic resolution of native MGN.<sup>10</sup> We also found 3 case reports of successful treatment of recurrent posttransplant MGN with rituximab.<sup>11-13</sup> The study of El-Zoghby and colleagues,<sup>14</sup> designed for early diagnosis of recurrent MGN after kidney transplantation with protocol biopsy, showed 75% of patients had either partial or complete remission 12 months after starting rituximab, which increased to 86% after 24 months. Based on these, we conclude that rituximab may be a safe and effective treatment for recurrent progressive MGN after kidney transplantation.

#### CONFLICT OF INTEREST

None declared.

**Table 2.** Data After Kidney Transplantation

Parameter	Patient 1	Patient 2
Time from transplantation, y	7	3
Delayed graft function	Negative	Positive
Immunosuppression Induction therapy	Cyclosporine, Mycophenolate Mofetil, Steroid	Thymoglobulin
Maintenance of Immunosuppression	Cyclosporine, Mycophenolate Mofetil, Steroid	Tacrolimus, Mycophenolate Mofetil, Steroid
Serum creatinine after transplantation at discharge, mg/dL	0.8	1.15
Time to recurrent nephrotic-range proteinuria after transplantation, y	4	1
Measurements at the time of biopsy		
Serum creatinine, mg/dL	1.97	1.40
Glomerular filtration rate, mL/min	37	82
Proteinuria, g/24 h	3.3	5.1
Antihypertensive*	Present	Present
Result of serologic tests after transplant	Negative	Negative
Pathologic examination†		
Number of glomeruli	9	6
Mesangial hypercellularity, %	25	50
Interstitial fibrosis, %	25	25
Tubular atrophy, %	25	25
CD20 in mononuclear cells, %	25 to 50	50
Rituximab protocol	4 doses, each 2 weeks 600 mg	4 doses, each 2 weeks 900 mg
Serum creatinine after last rituximab dose, mg/dL	1.20	1.34
Proteinuria 1 month after Rituximab, mg/24 h	180	1240
Duration of follow-up after treatment, mo	36	18
Last urinalysis	Normal, without proteinuria	Normal, without proteinuria
Last serum creatinine, mg/dL	1.10	1.18
Immunosuppressive during follow-up	Cyclosporine, Mycophenolate Mofetil, Steroid	Tacrolimus, Mycophenolate Mofetil, Steroid

\*Antihypertensives included angiotensin-converting enzyme inhibitors and angiotensin receptor blockers.

†See Figures 1 to 3.

## REFERENCES

- Ponticelli C, Glassock RJ. Posttransplant recurrence of primary glomerulonephritis. *Clin J Am Soc Nephrol.* 2010;5:2363-72.
- Glassock RJ. Diagnosis and natural course of membranous nephropathy. *Semin Nephrol.* 2003;23:324-32.
- Kerjaschki D, Farquhar MG. Immunocytochemical localization of the Heymann nephritis antigen (GP330) in glomerular epithelial cells of normal Lewis rats. *J Exp Med.* 1983;157:667-86.
- Cohen CD, Calvaresi N, Armelloni S, et al. CD20-positive infiltrates in human membranous glomerulonephritis. *J Nephrol.* 2005;18:328-33.
- Briganti EM, Russ GR, McNeil JJ, Atkins RC, Chadban SJ. Risk of renal allograft loss from recurrent glomerulonephritis. *N Engl J Med.* 2002;347:103-9.
- Sprangers B, Lefkowitz GI, Cohen SD, et al. Beneficial effect of rituximab in the treatment of recurrent idiopathic membranous nephropathy after kidney transplantation. *Clin J Am Soc Nephrol.* 2010;5:790-7.
- Salama AD, Pusey CD. Drug insight: rituximab in renal disease and transplantation. *Nat Clin Pract Nephrol.* 2006;2:221-30.
- Ruggenenti P, Chiurciu C, Brusegan V, et al. Rituximab in idiopathic membranous nephropathy: a one-year prospective study. *J Am Soc Nephrol.* 2003;14:1851-7.
- Fervenza FC, Cosio FG, Erickson SB, et al. Rituximab treatment of idiopathic membranous nephropathy. *Kidney Int.* 2008;73:117-25.
- Ruggenenti P, Cravedi P, Sghirlanzoni MC, et al. Effects of rituximab on morphofunctional abnormalities of membranous glomerulopathy. *Clin J Am Soc Nephrol.* 2008;3:1652-9.
- Weclawiak H, Ribes D, Guilbeau-Frugier C, et al. Relapse of membranous glomerulopathy after kidney transplantation: sustained remittance induced by rituximab. *Clin Nephrol.* 2008;69:373-6.
- Gallon L, Chhabra D. Anti-CD20 monoclonal antibody (rituximab) for the treatment of recurrent idiopathic membranous nephropathy in a renal transplant patient. *Am J Transplant.* 2006;6:3017-21.
- Sirimongkolrat T, Premasathian N, Vongwiwatana A, Limsrichamrern S, Cheunsuchon B, Vasuvattakul S. Anti-

CD20 monoclonal antibody (rituximab) for the treatment of membranous nephropathy after living-unrelated kidney transplantation: a case report. *Transplant Proc.* 2008;40:2440-1.

14. El-Zoghby ZM, Grande JP, Fraile MG, Norby SM, Fervenza FC, Cosio FG. Recurrent idiopathic membranous nephropathy: early diagnosis by protocol biopsies and treatment with anti-CD20 monoclonal antibodies. *Am J Transplant.* 2009;9:2800-7.

Correspondence to:  
Khadijeh Makhdoomi, MD  
Nephrology and Renal Transplant Center, Urmia University of  
Medical Sciences, Iran  
E-mail: makhdoomikhadijeh@yahoo.com

Received July 2014  
Revised October 2014  
Accepted October 2014