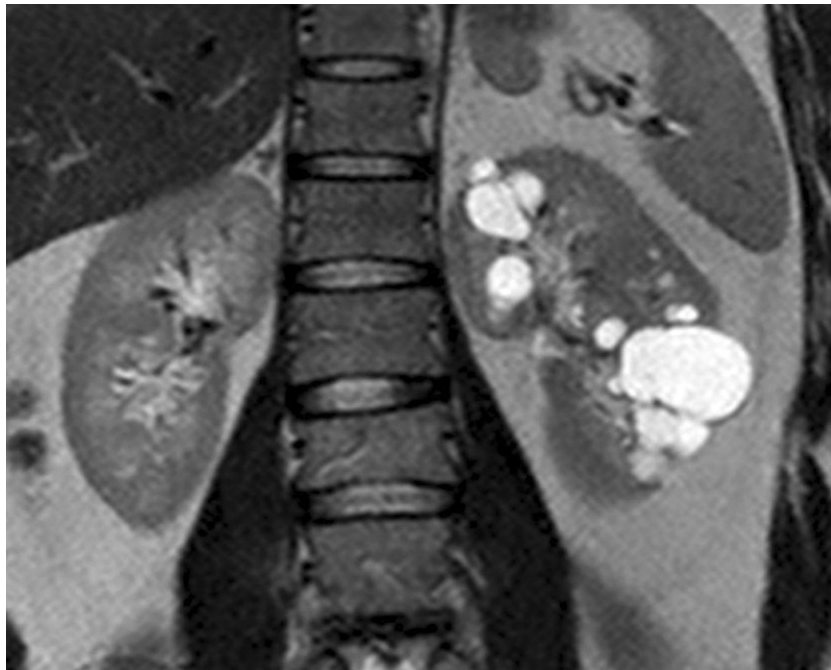


## Localized Cystic Disease of Kidney

IJKD 2015;9:193  
www.ijkd.org



In a 36-year-old Caucasian male with arterial hypertension and recurrent abdominal pain, imaging studies revealed multiple cysts limited to the left kidney. Results of basic laboratory tests, including serum creatinine and urinalysis, were normal. In effect, the diagnosis of localized cystic disease of the kidney (LCDK) was established. Localized cystic disease of the kidney is a rare nonhereditary benign condition of unknown etiology, and pathogenesis, which does not lead to kidney failure. It affects mostly men. Multiple cysts are localized in only one kidney, or its portion, with the contralateral kidney unaffected. Patients usually report arterial hypertension, abdominal pain, and hematuria. Patients with LCDK do not require treatment except for antihypertensive and symptomatic medicines. However, follow-up with imaging studies is usually advised.

From the practical point of view, it is crucial to differentiate LCDK with other cystic diseases of the kidney, with autosomal dominant polycystic kidney disease as the most common one. The features that enable to distinguish LCDK from autosomal dominant polycystic kidney disease are: negative family history, unilateral localization, normal kidney function, and lack of extrarenal manifestations except for renin-dependent hypertension. Additionally, in LCDK, normal pelvicalyceal system and ureter are observed, what distinguishes it from the multicystic dysplastic kidney.<sup>1,2</sup>

Mariusz Niemczyk,<sup>1\*</sup> Monika Gradzik,<sup>2</sup> Stanisław Niemczyk<sup>3</sup>

<sup>1</sup>Department of Immunology, Transplant Medicine, and Internal Diseases; Medical University of Warsaw, Warsaw, Poland

<sup>2</sup>Department of Radiology, Medical University of Warsaw, Warsaw, Poland

<sup>3</sup>Department of Internal Diseases, Nephrology and Dialysis; Military Institute of Medicine, Warsaw, Poland

\*E-mail: mariuszniemczyk@wp.pl

### REFERENCES

1. Neyaz Z, Kumar S, Lal H, Kapoor R. Localized cystic disease of the kidney: a rare entity. *J Radiol Case Rep.* 2012;6:29-35.
2. Solak A, Gur MS, Genc B, Sahin N. Localized cystic disease of the kidney: a rare cause of hypertension in a young adult. *J Clin Imaging Sci.* 2013;3:33.