

Ciprofloxacin-induced Crystal Nephropathy

Khawla Kammoun,^{1,2} Faiçal Jarraya,^{1,2} Saloua Makni,^{2,3}
 Lobna Ben Mahmoud,⁴ Mahmoud Kharrat,^{1,2} Mohamed Ben Hmida,^{1,2}
 Khaled Zeghal,⁴ Tahia Boudawara,³ Jamil Hachicha^{1,2}

¹Department of Nephrology, Hedi Chaker Hospital, Sfax, Tunisia

²Renal Pathology Unit UR 12 ES 14, Faculty of Medicine, Sfax, Tunisia

³Department of Histopathology, Habib Bourguiba Hospital, Sfax, Tunisia

⁴Regional Center of Pharmacovigilance, Faculty of Medicine, Sfax, Tunisia

Ciprofloxacin is a commonly used antibiotic. Renal side effects are rare and are usually immune mediated. Clinical and experimental studies have suggested that crystalluria and crystal nephropathy occur in alkaline urine. Preexisting kidney function impairment, high dose of the medication, and advanced age predispose to this complication. We report a case of crystal nephropathy in a young woman treated with ciprofloxacin and a nonsteroidal anti-inflammatory drug.

IJKD 2014;8:240-2
 www.ijkd.org

Keywords. acute kidney injury, ciprofloxacin, non-steroidal anti-inflammatory agents

INTRODUCTION

Ciprofloxacin is a commonly used antimicrobial fluoroquinolone. Acute kidney failure due to immune-mediated interstitial nephritis or vasculitis related to ciprofloxacin has been described in the literature.¹ Tubular necrosis with crystal nephropathy is an uncommon presentation of ciprofloxacin-induced kidney failure. We report a new case of crystal nephropathy due to administration of ciprofloxacin and a nonsteroidal anti-inflammatory drug (NSAID).

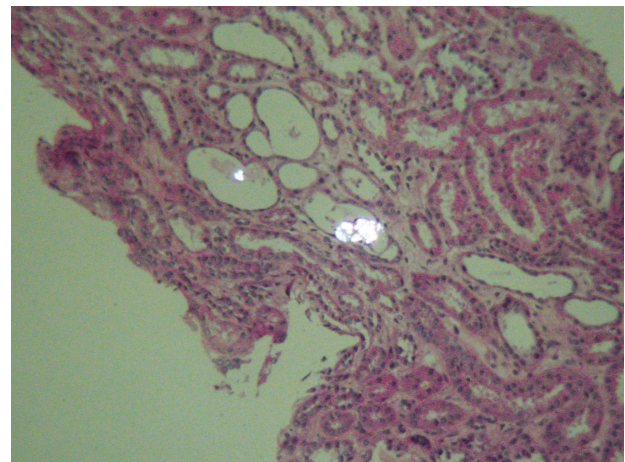
CASE REPORT

A 16-year-old woman was admitted because of nausea, vomiting, and elevated serum creatinine. Her past medical history was unremarkable until 15 days earlier, when she developed urinary tract infection treated by ciprofloxacin, 500 mg, twice per day, and mefenamic acid for 5 days. Twelve days after withdrawal of the treatment, she developed anorexia and vomiting.

On admission, body temperature was 37°C and the arterial blood pressure was 112/88 mm Hg. Physical examination was normal. On laboratory evaluation, serum creatinine level was 900 µmol/L; blood urea, 33 mmol/L; total serum protein, 77 g/L; serum albumin, 33.6 g/L; and serum

gammaglobulin, 11 g/L. Peripheral leukocyte count was $9.2 \times 10^9/L$ with 61.4% neutrophils, 30.9% lymphocytes, and 1.8% eosinophils. The patient did not report dysuria, decreased urine output, or cutaneous manifestations. Urinalysis showed neither proteinuria nor hematuria. Urine pH was 6. Serum complement levels were in reference range and tests for antinuclear antibodies, anti-Sjogren syndrome A and B antibodies, and antineutrophil cytoplasmic antibody were negative.

Abdominal ultrasonography showed normalized kidneys. A percutaneous kidney biopsy



Refringent intratubular crystals (hematoxylin-eosin, × 400).

was then performed, which showed 6 normal glomeruli and no interstitial edema or infiltrate. However, there was acute tubular necrosis with intratubular needle-shaped crystals. These crystals were refringent under polarized light (Figure). Spontaneous improvement of kidney function was observed. Serum creatinine levels at hospital discharge (10 days later), 15 days later, and 3 months later were 156 $\mu\text{mol/L}$, 74 $\mu\text{mol/L}$, and 70 $\mu\text{mol/L}$, respectively.

DISCUSSION

Crystal nephropathy may occur during administration of medications excreted by the kidney for which urine solubility depends on urine pH. Several drugs, notably acyclovir, methotrexate, indinavir, and sulfonamide, are associated with crystalluria and crystal nephropathy.^{2,3} Sulfadiazine and methotrexate tend to precipitate in tubule when urine pH is low. Acyclovir intratubular precipitation is increased in alkaline urine.³ Decreased flow rate, impaired kidney function, and high doses in relation to kidney function and concurrent use of nephrotoxic drugs are common factors of intratubular precipitation of all these drugs.⁴ Acute kidney failure secondary to quinolone is frequently immune-allergic acute interstitial nephropathy.¹

Crystal nephropathy secondary to ciprofloxacin is rarely reported. We report a case of crystal nephropathy after therapeutic-dose administration of ciprofloxacin in a young patient. About 30% to 60% of the active drug (ciprofloxacin) is excreted in the urine during 24 hours.⁵ Renal elimination is made by glomerular filtration and active tubular secretion.⁵ The presence of crystals deposits was first reported in experimental studies in animals known to have alkaline urine. Clinical studies have demonstrated that crystalluria after ciprofloxacin treatment are uncommon and occur in alkaline urine (pH > 7.3).^{1,5-7} Our case and others reported in literature demonstrated that crystal nephropathy might occur with acidic urine (Table).^{1,8,9} According

to our knowledge, most cases of crystal nephropathy associated with ciprofloxacin were observed in older patients with preexisting kidney damage or with high-dose administration of ciprofloxacin (Table). Conversely to the literature, our patient was young, without preexisting kidney damage, and the dose of ciprofloxacin was adequate.

In our case, tubular necrosis could also be attributed to NSAIDs rather than ciprofloxacin. Acute kidney failure associated with NSAIDs was reported in young patients without preexisting kidney damage or precipitating factor.^{10,11} It has been shown that tubular secretion of ciprofloxacin is mediated by organic anion transporters: hOAT3 in basolateral membrane and MRP2 in apical membrane, and that deletion of *HOAT3* increases systemic exposure to ciprofloxacin.^{12,13} These transporters are inhibited by NSAIDs.¹² In our case, it might be postulated that association of NSAIDs with ciprofloxacin led to systemic accumulation of ciprofloxacin. After withdrawal of NSAIDs, there was no longer inhibition of ciprofloxacin renal secretion and there was massive excretion of ciprofloxacin in the renal tube and development of crystal nephropathy.

In summary, even in young patients, concurrent administration of ciprofloxacin and NSAIDs should be avoided, since it is potentially responsible for acute kidney failure and intratubular crystal deposits.

CONFLICT OF INTEREST

None declared.

REFERENCES

1. Montagnac R, Briat C, Schillinger F, Sartelet H, Birembaut P, Daudon M. [Fluoroquinolone induced acute renal failure. General review about a case report with crystalluria due to ciprofloxacin]. *Nephrol Ther.* 2005;1:44-51.
2. Herlitz LC, D'Agati VD, Markowitz GS. Crystalline nephropathies. *Arch Pathol Lab Med.* 2012;136:713-20.
3. Yarlagadda SG, Perazella MA. Drug-induced crystal

Ciprofloxacin Crystal Nephropathy in Literature

Study	Patient Age, y	Ciprofloxacin Dose	Urine pH
Montagnac et al ¹	58	500 mg, Twice Daily	Not Available
Sedlacek et al ⁶	90	750 mg, Twice Daily	6.5
Stratta et al ⁹	74	750 mg, Twice Daily	5.5
Stratta et al ⁹	78	750 mg, Twice Daily	4.5
Present report	16	500 mg, Twice Daily	6

- nephropathy: an update. *Expert Opin Drug Saf.* 2008;7:147-58.
4. Obada EN, Level G, Mathieu P, Parent X, Gilson B, Bindi P. [Acute renal failure following a treatment with acyclovir]. *Nephrol Ther.* 2010;6:125-7.
 5. Vaamonde CA, Contreras GN, Diego JM. Sulfonamides, sulfadiazine, trimethoprim-sulfamethoxazole, pentamidine, pyrimethamine, dapsone, quinolones. In: De Broe ME, Porter GA, Bennett WM, Verpoorten GA, editors. *Clinical nephrotoxins: renal injury from drugs and chemicals.* Dordrecht: Springer Science; 2004. p. 223-48.
 6. Fogazzi GB, Garigali G, Brambilla C, Daudon M. Ciprofloxacin crystalluria. *Nephrol Dial Transplant.* 2006;21:2982-3.
 7. Ball P, Tillotson G. Tolerability of fluoroquinolone antibiotics. Past, present and future. *Drug Saf.* 1995;13:343-58.
 8. Sedlacek M, Suriawinata AA, Schoolwerth A, Remillard BD. Ciprofloxacin crystal nephropathy--a 'new' cause of acute renal failure. *Nephrol Dial Transplant.* 2006;21:2339-40.
 9. Stratta P, Lazzarich E, Canavese C, Bozzola C, Monga G. Ciprofloxacin crystal nephropathy. *Am J Kidney Dis.* 2007;50:330-5.
 10. Dixit MP, Nguyen C, Carson T, et al. Non-steroidal anti-inflammatory drugs-associated acute interstitial nephritis with granular tubular basement membrane deposits. *Pediatr Nephrol.* 2008;23:145-8.
 11. Patzer L. Nephrotoxicity as a cause of acute kidney injury in children. *Pediatr Nephrol.* 2008;23:2159-73.
 12. Hagos Y, Wolff NA. Assessment of the role of renal organic anion transporters in drug-induced nephrotoxicity. *Toxins (Basel).* 2010;2:2055-82.
 13. Vanwert AL, Srimaroeng C, Sweet DH. Organic anion transporter 3 (oat3/slc22a8) interacts with carboxyfluoroquinolones, and deletion increases systemic exposure to ciprofloxacin. *Mol Pharmacol.* 2008;74:122-31.

Correspondence to:

Khawla Kammoun, MD

Department of Nephrology, Hedi Chaker Hospital, Route El Ain Km 1, Sfax, Tunisia, UR/99-3807

E-mail: KhawlaKammoun2002@yahoo.fr

Received February 2013

Revised August 2013

Accepted September 2013