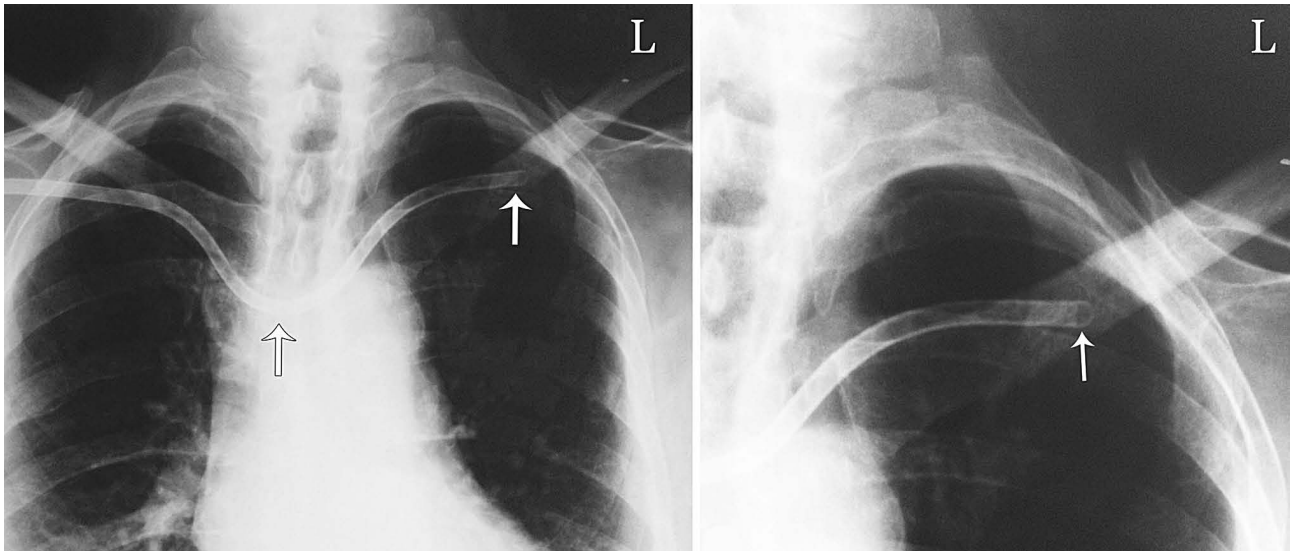


## Another Side Effect of Subclavian Catheter

IJKD 2013;7:101  
www.ijkd.org



A 74-year-old man was consulted due to dizziness, diaphoresis, light-headedness, myoclonic movements, and finally decreased consciousness shortly after hemodialysis commencement. Hemodialysis was halted immediately, and he recovered after a brief volume replacement therapy. Physical examination and the laboratory tests were unremarkable. A tunneled dialysis catheter (Permacath) had been placed through right subclavian vein one day earlier by an expert surgeon following the detection of signs of infection in the previous one in the left side. A chest radiography revealed that the hemodialysis catheter had passed the right innominate vein and entered the left innominate vein, with its tip being lodged in the left subclavian vein. The catheter was thereafter repositioned under fluoroscopy guide, and the position was confirmed by chest radiography. The next hemodialysis session was eventless.

Malposition of dialysis catheters is not uncommon and similar cases have already been reported.<sup>1</sup> The best position of the tip of a Permacath is in the right atrium.<sup>2</sup> Although fluoroscopy is mandatory for the insertion of all cuffed dialysis catheters, it is not always performed. We believe that the insertion of subclavian or jugular catheters should be monitored by electrocardiographic or radiographic measures to reduce the malpositioning of central venous catheters.<sup>3</sup> Taking a control chest radiography following the insertion of the dialysis catheter seems to be necessary in all patients.

Akbar Shafiee,<sup>1</sup> Khosro Barkhordari<sup>2\*</sup>

<sup>1</sup>Department of Cardiovascular Research, Tehran Heart Center, Tehran University of Medical Sciences, Tehran, Iran

<sup>2</sup>Department of Anesthesiology and Critical Care, Tehran Heart Center, Tehran University of Medical Sciences, Tehran, Iran

\*E-mail: kbarkhordari@sina.tums.ac.ir

### REFERENCES

1. Stolic RV, Stolic DZ. A Left jugular vein catheter for hemodialysis malpositioned in right brachiocephalic vein. *Iranian J Kidney Dis.* 2012;6:98.
2. National Kidney Foundation-Dialysis Outcomes Quality Initiative. NKF-DOQI Clinical Practice Guidelines for Vascular Access. *Am J Kidney Dis.* 1997;30:S150-91.
3. Ponikvar R. Hemodialysis catheters. *Ther Apher Dial.* 2005;9:218-22.