

Multicystic Dysplastic Kidney in Association With Congenital Ichthyosiform Erythroderma

Hamid Reza Badeli,¹ Seyed Aidin Sajedi,¹ Azita Tangestaninejad,² Mohammad Reza Ahmadian,¹ Kaveh Alipour Kanafi¹

¹Division of Nephrology, Department of Pediatrics, Guilan University of Medical Sciences, Rasht, Iran

²Department of Internal Medicine, Guilan University of Medical Sciences, Rasht, Iran

Keywords. congenital ichthyosiform erythroderma, multicystic dysplastic kidney, congenital heart defects

Multicystic dysplastic kidney is a noninherited congenital disease. Association of this disease with abnormalities of various organs is common. We, however, report a rare case of multicystic dysplastic kidney associated with congenital ichthyosiform erythroderma in an infant. Different developmental origins of the skin and the kidney can explain the scarcity of concurrent congenital skin and kidney abnormalities. Nonetheless, the development of both organs depends on mesenchyme-epithelial interactions for inductive signaling. It seems defects in the production of signaling molecules can explain such an association.

IJKD 2007;1:102-4
www.ijkd.org

INTRODUCTION

Multicystic dysplastic kidney (MCDK) is a noninherited congenital disease of the kidney that grossly consists of multiple cysts of various sizes without a normal kidney tissue on macroscopic and microscopic views. Involvement of other organs is likewise common in patients with MCDK. Esophageal atresia, tracheoesophageal atresia, ventricular septal defect, and patent ductus arteriosus are the most common extrarenal abnormalities.¹

Disorders of cornification, also known as *ichthyosis*, are a group of inherited conditions that are characterized clinically by patterns of scaling, and histopathologically, by hyperkeratosis. Congenital ichthyosiform erythroderma (CIE) is one of the inherited diseases that present shortly after birth.² We report a case of an infant with CIE, congenital heart disease, and MCDK.

CASE REPORT

A-35-day old male infant was admitted to our center for fever, poor feeding, and skin lesions. He did not have any history of delivery problems. His parents were healthy but at a low socioeconomic status. He had fever and poor feeding since 36 hours before admission and skin lesions since birth.

Upon admission, he underwent sepsis workup

and empirical antibiotic therapy consisting of ampicillin, 100 mg/kg, plus ceftriaxone, 100 mg/kg, was started. Chest radiography showed cardiomegaly (Figure 1). Cardiologic consultation and echocardiography revealed a small atrial

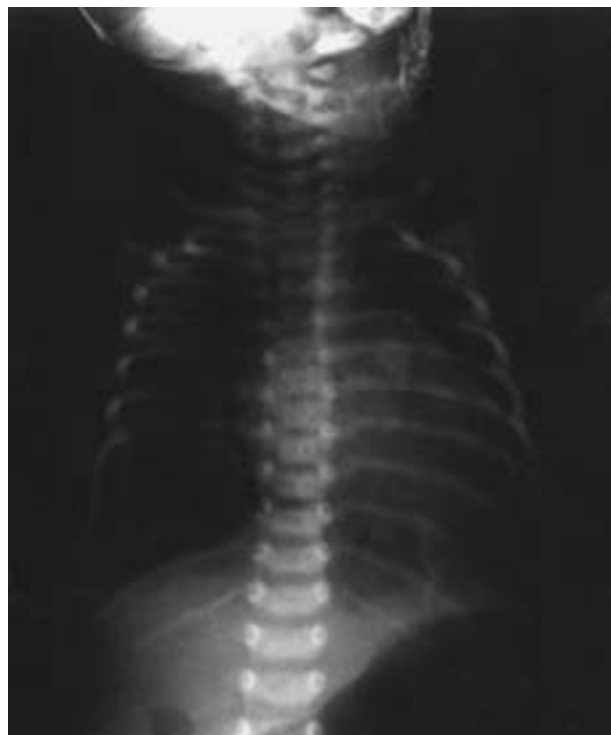

Figure 1. Cardiomegaly was visualized on chest radiography.

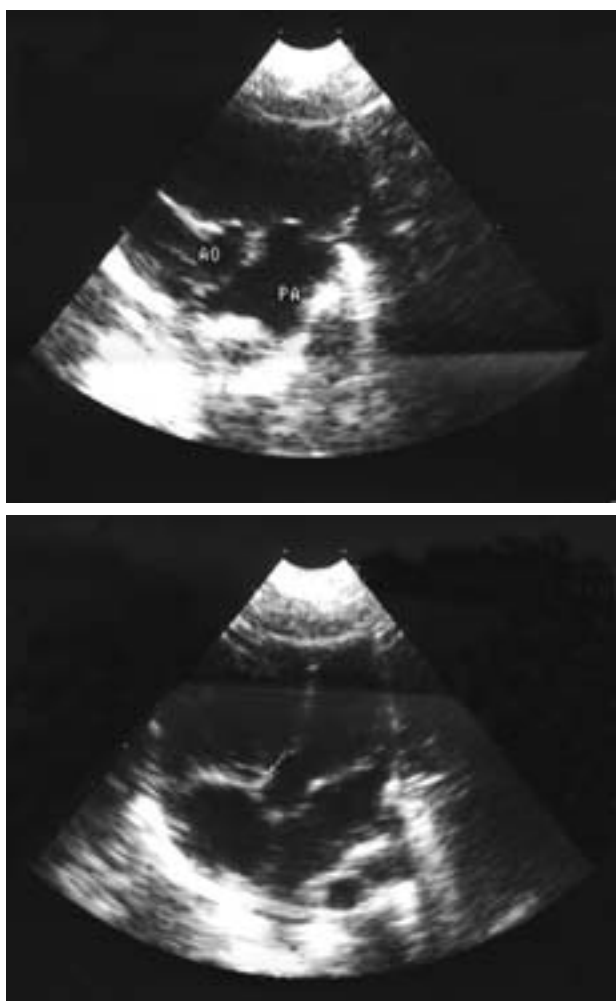


Figure 2. Echocardiography showed a small atrial septal defect, a moderate ventricular septal defect, and increased pressure of the pulmonary artery.

septal defect, a moderate ventricular septal defect, and pulmonary hypertension (Figure 2). Computed tomography of the brain did not show any abnormality. Other laboratory examinations were unremarkable (blood hemoglobin, 13 g/dL; hematocrit, 0.38; white blood cell count, $1.0 \times 10^9/L$).

The patient also had skin lesions that consisted of erythrodermia, generalized fine light-colored scales, and thickening of the palms and soles in general appearance. Following dermatologic consultation, skin biopsy was performed. Pathology examination result was indicative of mild regular acanthosis, thickening, and vacuolation, together with mild granular spongiosis with neutrophilic exocytosis, perivascular edema, and mixed lymphocytic and neutrophilic infiltration in the upper dermis. Findings were suggestive for nonbullous CIE.

During the hospitalization, his abdominal

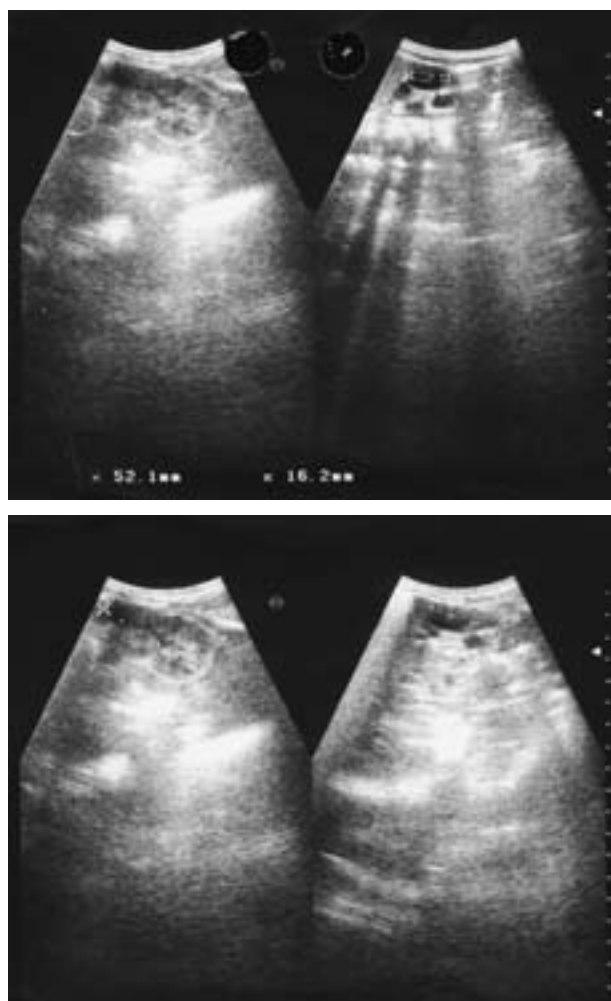


Figure 3. Ultrasonography of the kidneys demonstrated an enlarged right kidney containing multiple noncommunicating cysts.

ultrasonography demonstrated an enlarged right kidney containing multiple noncommunicating cysts (Figure 3), in favor of MCDK. Diethylenetriamine penta-acetic acid diuresis renography showed a nonfunctioning right kidney and a normal function in the left kidney. Voiding cystourethrography was negative for vesicoureteral reflux. Kidney function tests were in the reference ranges (serum creatinine, 0.4 mg/dL; blood urea nitrogen, 10 mg/dL). He was discharged from hospital after a standard 10-day treatment course for sepsis with the mentioned antibiotics and followed by a dermatologist. Unfortunately, after 2 weeks, we were informed of his death during a second hospitalization in another center due to a superimposed septic shock following undiagnosed chronic dehydration resulted from transepidermal water loss and lack of enough attention of his parents. His blood and urine cultures were negative for growth of microorganisms and

the cause of death had been documented on the basis of his clinical manifestations.

DISCUSSION

Multicystic dysplastic kidney is a noninherited congenital disease of the kidney that grossly consists of multiple cysts of various sizes without a normal kidney tissue. Abnormality of the contralateral kidney in patients with unilateral MCDK is common, having been demonstrated in 20% to 75% of the cases.^{3,4} The most common abnormality (seen in 18% of the patients) is vesicoureteral reflux.⁵ Agenesis, ureterovesical obstruction, ureteral valve, and ectopic ureter with ureterocele are the other accompanied urinary tract abnormalities.^{6,7} Involvements of other organs are likewise common in patients with MCDK. Esophageal atresia, tracheoesophageal atresia, ventricular septal defect, and patent ductus arteriosus are the most common extrarenal abnormalities.¹

Although the association of MCDK with various abnormalities, as mentioned above, has been reported, to our knowledge, this is the first report of MCDK associated with nonbullous CIE in an infant. It might be either a coincidental phenomenon or due to a linkage between MCDK and ichthyosiform erythroderma.

Association of abnormalities in the kidney with aberrant skin development is rare, since the kidney is derived from the intermediate mesoderm, while the skin is derived from the ectoderm. Nonetheless, both organs depend on mesenchyme-epithelial interactions for inductive signaling. It has suggested that kidney malformations in patients with MCDK result from a primary defect of ampullary function, ie, the ureteral bud of the kidney is formed, but normal branching of renal mesenchyme induction is failed thereafter.⁸ It is now clear that induction and differentiation of the renal mesenchyme and ureteral bud depend on mutual interactions mediated by signaling molecules such as growth factors and matrix molecules, with transcription factors controlling expression of their genes.⁸ On the other hand, although mutations of transglutaminase-1 have been identified in some families with CIE, the genetic etiology of CIE is not known completely.^{9,10} Nevertheless, we know that normal development of the skin and its appendages is dependent on reciprocal signaling between the epithelial cells and the underlying mesenchyme.¹¹

Accordingly, we speculate that these may explain a probable association between MCDK and CIE on the basis of a defect in producing inductive and signaling molecules during organs development. Obviously, this hypothesis needs further studies to be elucidated.

CONFLICT OF INTEREST

None declared.

REFERENCES

1. Glassberg KI. Renal dysplasia and cystic disease of the kidney. In: Walsh PC, Retik AB, Vaughan ED Jr, Wein AJ, editors. *Campbell's urology*. 7th ed. Philadelphia: WB Saunders; 1998. p. 1757-813.
2. Rand RE, Baden HP. The ichthyoses—a review. *J Am Acad Dermatol*. 1983;8:285-305.
3. Pathak IG, Williams DI. Multicystic and cystic dysplastic kidneys. *Br J Urol*. 1964;36:318-31.
4. Atiyeh B, Husmann D, Baum M. Contralateral renal abnormalities in multicystic-dysplastic kidney disease. *J Pediatr*. 1992;121:65-7.
5. Gil-Salom M, Sanchez C, Chuan P, Morell L, Clar F. Reflux nephropathy: a clinico-pathological study of 16 cases. *Urol Int*. 1991;46:129-34.
6. Govaerts J, Huysmans G, Wouters Y. Ureteric valves in an ectopic ureter associated with renal dysplasia. *Br J Urol*. 1991;67:554-5.
7. Blane CE, Ritchey ML, DiPietro MA, Sumida R, Bloom DA. Single system ectopic ureters and ureteroceles associated with dysplastic kidney. *Pediatr Radiol*. 1992;22:217-20.
8. Woolf AS, Price KL, Scambler PJ, Winyard PJ. Evolving concepts in human renal dysplasia. *J Am Soc Nephrol*. 2004;15:998-1007.
9. DiGiovanna JJ, Robinson-Bostom L. Ichthyosis: etiology, diagnosis, and management. *Am J Clin Dermatol*. 2003;4:81-95.
10. Becker K, Csikos M, Sardy M, Szalai ZS, Horvath A, Karpati S. Identification of two novel nonsense mutations in the transglutaminase 1 gene in a Hungarian patient with congenital ichthyosiform erythroderma. *Exp Dermatol*. 2003;12:324-9.
11. O'Shaughnessy RF, Christiano AM. Inherited disorders of the skin in human and mouse: from development to differentiation. *Int J Dev Biol*. 2004;48:171-9.

Correspondence to:

Hamid Reza Badeli, M.D
Hefda-e-Shahrivar Pediatric Hospital, Namjoo St, Rasht, Iran
Tel: +98 131 772 3155
Fax: +98 131 322 6101
E-mail: badeli@gums.ac.ir

Received June 2007

Revised July 2007

Accepted August 2007